This is a digital copy of a book that was preserved for generations on library shelves before it was carefully scanned by Google as part of a project to make the world's books discoverable online.

It has survived long enough for the copyright to expire and the book to enter the public domain. A public domain book is one that was never subject to copyright or whose legal copyright term has expired. Whether a book is in the public domain may vary country to country. Public domain books are our gateways to the past, representing a wealth of history, culture and knowledge that's often difficult to discover.

Marks, notations and other marginalia present in the original volume will appear in this file - a reminder of this book's long journey from the publisher to a library and finally to you.

Usage guidelines

Google is proud to partner with libraries to digitize public domain materials and make them widely accessible. Public domain books belong to the public and we are merely their custodians. Nevertheless, this work is expensive, so in order to keep providing this resource, we have taken steps to prevent abuse by commercial parties, including placing technical restrictions on automated querying.

We also ask that you:

+ *Make non-commercial use of the files* We designed Google Book Search for use by individuals, and we request that you use these files for personal, non-commercial purposes.
+ *Refrain from automated querying* Do not send automated queries of any sort to Google's system: If you are conducting research on machine translation, optical character recognition or other areas where access to a large amount of text is helpful, please contact us. We encourage the use of public domain materials for these purposes and may be able to help.
+ *Maintain attribution* The Google "watermark" you see on each file is essential for informing people about this project and helping them find additional materials through Google Book Search. Please do not remove it.
+ *Keep it legal* Whatever your use, remember that you are responsible for ensuring that what you are doing is legal. Do not assume that just because we believe a book is in the public domain for users in the United States, that the work is also in the public domain for users in other countries. Whether a book is still in copyright varies from country to country, and we can't offer guidance on whether any specific use of any specific book is allowed. Please do not assume that a book's appearance in Google Book Search means it can be used in any manner anywhere in the world. Copyright infringement liability can be quite severe.

About Google Book Search

Google's mission is to organize the world's information and to make it universally accessible and useful. Google Book Search helps readers discover the world's books while helping authors and publishers reach new audiences. You can search through the full text of this book on the web at `http://books.google.com/`

BOSTON
MEDICAL LIBRARY
8 THE FENWAY

TRANSACTIONS

OF THE

PATHOLOGICAL SOCIETY OF LONDON.

VOLUME THE TWENTY-NINTH.

COMPRISING THE REPORT OF THE PROCEEDINGS FOR THE SESSION 1877-78.

LONDON:
PRINTED FOR THE SOCIETY BY J. E. ADLARD, BARTHOLOMEW CLOSE.
1878.

30004

THE present publication, being the Twenty-ninth Volume of Transactions, constitutes the Thirty-second published Annual Report of the Pathological Society's Proceedings.

The COUNCIL think it right to repeat that the exhibitors are alone responsible for the descriptions given of the Specimens exhibited by them, the only change made in the Reports furnished by the authors being such verbal alterations as were absolutely necessary.

53, BERNERS STREET, OXFORD STREET
October, 1878.

TABLE OF CONTENTS

OF VOLUME XXIX.

Lists of Presidents and of Officers and Members for 1877 . . . . . IV—XXXII

Annual Report of Council for 1877 XXXIII

List of Specimens Exhibited during the Session 1877-8 XXXVII

List of Specimens Reported on by the Committee on Morbid Growths XLVI

List of Plates XLVII

List of Woodcuts XLIX

Diseases, etc., of the Nervous System . . . 1

Diseases, etc., of the Organs of Respiration . . 29

Diseases, etc., of the Organs of Circulation . . 43

Diseases, etc., of the Organs of Digestion . . 113

Diseases, etc., of the Genito-Urinary Organs . 151

Diseases, etc., of the Osseous System . . . 172

Morbid Growths 194

Diseases, etc., of the Skin 252

Special Communications 269

A—On Diseases of the Lymphatic System . . 269

B—On Splenic Fever 420

C—On Measles 421

D—On Lactic Fermentation 425

Index 469

Presidents of the Society.

ELECTED

1846 CHARLES J. B. WILLIAMS, M.D., F.R.S.
1848 CHARLES ASTON KEY.
1850 PETER MERE LATHAM, M.D.
1852 CÆSAR H. HAWKINS, F.R.S.
1853 BENJAMIN GUY BABINGTON, M.D., F.R.S.
1855 JAMES MONCRIEFF ARNOTT, F.R.S.
1857 SIR THOMAS WATSON, BART., M.D., F.R.S.
1859 SIR WILLIAM FERGUSSON, BART., F.R.S.
1861 JAMES COPLAND, M.D., F.R.S.
1863 PRESCOTT G. HEWETT, F.R.S.
1865 THOMAS BEVILL PEACOCK, M.D.
1867 JOHN SIMON, D.C.L., F.R.S.
1869 RICHARD QUAIN, M.D., F.R.S.
1871 JOHN HILTON, F.R.S.
1873 SIR WILLIAM JENNER, BART., M.D., K.C.B., D.C.L., F.R.S.
1875 GEORGE D. POLLOCK.
1877 CHARLES MURCHISON, M.D., LL.D., F.R.S.

OFFICERS AND COUNCIL

OF THE

Pathological Society of London,

ELECTED AT

THE GENERAL MEETING, JANUARY 4TH, 1878.

President.

CHARLES MURCHISON, M.D., LL.D., F.R.S.

Vice-Presidents.

EDWARD HEADLAM GREENHOW, M.D., F.R.S.
GEORGE HARLEY, M.D., F.R.S.
WALTER MOXON, M.D.
HERMANN WEBER, M.D.
THOMAS BRYANT.
GEORGE W. CALLENDER, F.R.S.
THOMAS WILLIAM NUNN.
THOMAS SMITH.

Treasurer.

JOHN WHITAKER HULKE, F.R.S.

Council.

WILLIAM CAYLEY, M.D.
SIDNEY COUPLAND, M.D.
JAMES F. GOODHART, M.D.
WILLIAM RICHARD GOWERS, M.D.
T. HENRY GREEN, M.D.
WILLIAM SMITH GREENFIELD, M.D.
CHARLES HENRY RALFE, M.D.
JOHN C. THOROWGOOD, M.D.
C. THEODORE WILLIAMS, M.D.
JOHN WILLIAMS, M.D.
WILLIAM ADAMS.
EDWARD BELLAMY.
HENRY TRENTHAM BUTLIN.
RICKMAN JOHN GODLEE.
HENRY GREENWAY HOWSE.
JEREMIAH McCARTHY.
WILLIAM MAC CORMAC.
HENRY MORRIS.
ARTHUR TREHERNE NORTON.
WILLIAM W. WAGSTAFFE.

Honorary Secretaries.

R. DOUGLAS POWELL, M.D. | W. MORRANT BAKER.

Trustees.

THOS. BEVILL PEACOCK, M.D. | RICHARD QUAIN, M.D., F.R.S.
GEORGE D. POLLOCK.

*** *Members are requested to indicate to the Secretaries corrections when necessary.*

LIST OF MEMBERS OF THE SOCIETY.

Honorary Members.

ARNOTT, JAMES MONCRIEFF, F.R.S., Chapel House, Lady Bank, Fifeshire; and 36, Sussex-gardens, Hyde-park, W.

BILLROTH, THEODOR, M.D., Professor of Surgery in the University of Vienna.

BRUECKE, ERNST, M.D., Professor of Physiology in the University of Vienna.

HELMHOLTZ, H., M.D., Professor of Physiology in the University of Heidelberg.

HENLE, J., M.D., Professor of Anatomy and Physiology in the University of Göttingen.

LUDWIG, C., M.D., Professor of Physiology in the University of Leipzig.

VIRCHOW, RUDOLF, M.D., Professor of Pathological Anatomy in the University of Berlin.

VOGEL, JULIUS, M.D., Professor of Cutaneous Diseases in the University of Halle.

EXPLANATION OF ABBREVIATIONS.

O.M.—Original Member.	V.-P.—Vice-President.
Pres.—President.	S.—Secretary.
T.—Treasurer.	C.—Member of Council.

Those marked thus (†) have paid Composition Fee for Annual Subscription.
Those marked thus (‡) have paid Composition Fee for Transactions.

GENERAL LIST OF MEMBERS.

Elected

1858 ACLAND, HENRY WENTWORTH, M.D., F.R.S., Regius Professor of Medicine, University of Oxford, Physician to the Radcliffe Infirmary, Oxford.

‡1866 ADAMS, ARTHUR BAYLEY.

1869 ADAMS, JAMES EDWARD, Surgeon to the London Hospital, 10, Finsbury-circus, E.C.

O.M. ADAMS, WILLIAM, Consulting Surgeon to the National Orthopædic Hospital, 5, Henrietta-street, Cavendish-square, W. (C. 1851-4. V.-P. 1867-9.)

1859 ADAMS, WILLIAM (C.), 37, Harrington-square, N.W. (C. 1877-8.)

1848 AIKIN, CHARLES A., 7, Clifton-place, Sussex-square, Hyde-park, W. (C, 1864-6.)

1872 AIKIN, CHARLES EDMUND, 7, Clifton-place, Sussex-square, Hyde-park, W.

1871 AIR, A. CUMMINGS, 88, Kennington-park-road, S.E.

1869 ALLBUTT, THOMAS CLIFFORD, M.D., Physician to the Leeds General Infirmary, 35, Park-square, Leeds.

Elected

1877 ALTHAUS, JULIUS, M.D., Physician to the Infirmary for Epilepsy and Paralysis, 36, Bryanston-street, Portman-square.

1878 AMPHLETT, EDWARD, M.B., Assistant Surgeon to the Charing Cross Hospital, 40, Weymouth-street, Portland-place, W.

1868 ANDERSON, J. FORD, M.D., 28, Buckland-crescent, Belsize-park, N.W.

1871 ANDERSON, WILLIAM, Professor of Medical Science at the University of Yeddo, Japan.

1859 ANDREW, EDWYN, M.D., Hardwick House, St. John's-hill, Shrewsbury.

1863 ANDREW, JAMES, M.D., Physician to St. Bartholomew's Hospital, 22, Harley-street, W. (C. 1868-70.)

1866 ARNOTT, REV. HENRY, Braeside, Beckenham. (C. 1872, 1875-6. S. 1873, 1874.)

1863 BAGSHAWE, FREDERICK, M.A., M.D., 16, Warrior-square, Hastings.

1864 BAKER, WILLIAM MORRANT (HON. SECRETARY), Assistant Surgeon to, and Lecturer on Physiology at, St. Bartholomew's Hospital, 26, Wimpole-street, Cavendish-square, W. (C. 1873-6. S. 1878.)

‡1856 BALDING, DANIEL BARLEY, Royston, Herts.

1851 BARCLAY, A. WHYTE, M.D., Physician to St. George's Hospital, 23A, Bruton-street, Berkeley-square, W. (C. 1858-61.)

1875 BARKER, ARTHUR, Assistant Surgeon and Assistant Teacher of Clinical Surgery, University College Hospital, 28, Welbeck-street, Cavendish-square, W.

1874 BARLOW, THOMAS, M.D., B.S., Assistant Physician to Charing Cross Hospital and to the Children's Hospital, 10, Montague-street, Russell Square, W.C.

1871 BARNES, ROBERT, M.D., Obstetric Physician to St. George's Hospital, 15, Harley-street, Cavendish-square, W.

1862 BARRATT, JOSEPH GILLMAN, M.D., Accoucheur to the St. George's and St. James's Dispensary, 8, Cleveland-gardens, Bayswater, W.

1877 BARROW, A. BOYCE, Pathological Registrar, King's College Hospital, 17, Welbeck-street, Cavendish-square, W.

1853 BARWELL, RICHARD, Surgeon to, and Lecturer on Surgery at, the Charing Cross Hospital, 32, George-street, Hanover-square, W. (C. 1862-4.)

1861 BASTIAN, H. CHARLTON, M.A., M.D., F.R.S., Professor of Pathological Anatomy in University College, and Physician to University College Hospital, 20, Queen Anne-street, W. (C. 1869-71.)

1877 BATEMAN, ARTHUR W., B.A., 16, Endsleigh-street, Tavistock-square, W.C.

†1876 BATTESON, JOHN, Medical Officer of the Royal Humane Society, 1, Coborn-place, Bow-road, E.

1870 BÄUMLER, CHRISTIAN G. H., M.D., Professor of Materia Medica in the University of Erlangen.

1871 BAXTER, EVAN BUCHANAN, M.D., Professor of Materia Medica, King's College, London, and Assistant Physician to King's College Hospital, 28, Weymouth-street, Portland-place, W.

Elected

1874 BEACH, FLETCHER, M.B., Asylum for Idiots, Lower Clapton, N.E.

1852 BEALE, LIONEL S., M.B., F.R.S., Professor of Medicine at King's College, Physician to King's College Hospital, 61, Grosvenor-street, W. (C. 1858-9. V.-P. 1874-5.)

1856 BEALEY, ADAM, M.D., M.A., Oak-lea, Harrogate.

1870 BECK, MARCUS, M.S., Assistant Surgeon to University College Hospital, 30, Wimpole-street, Cavendish-square, W. (C. 1875-7.)

1865 BEEBY, WALTER, M.D., Bromley, Kent.

1865 BEIGEL, HERMANN, M.D., 2, Lichtensteinstrasse, Vienna.

1875 BELL, H. ROYES, Surgeon, with care of Out-patients, to King's College Hospital, 44, Harley-street, Cavendish-square, W.

1865 BELLAMY, EDWARD (C.), Surgeon to the Charing Cross Hospital, 17, Wimpole-street, Cavendish-square, W. (C. 1876-8.)

1847 BENNET, JAMES HENRY, M.D., Weybridge, Surrey.

1876 BENNETT, ALEX. HUGHES, M.D., Assistant Physician to the Westminster Hospital, 117, Cromwell-road, South Kensington, S.W.

O.M. BENNETT, JAMES RISDON, M.D., F.R.S., Consulting Physician to St. Thomas's Hospital, and to the City of London Hospital for Diseases of the Chest, 22, Cavendish-square, W. (C. 1846-8. V.-P. 1856-9.)

1877 BENNETT, WILLIAM HENRY, Surgeon to the Belgrave Hospital for Children, 22, James-street, Buckingham-gate, S.W.

1878 BERNARD, FRANCIS W., M.D., Medical Superintendent, Stockwell Small-pox Hospital, Stockwell, S.W.

1876 BERNAYS, SIDNEY, Acre House, Brixton.

‡1856 BICKERSTETH, EDWARD R., Surgeon to the Liverpool Royal Infirmary, 2, Rodney-street, Liverpool.

1878 BINDON, WILLIAM JOHN VEREKER, M.D., 2, Elm-villas, Kilburn, N.W.

1878 BIRD, CUTHBERT H. GOLDING, M.B., Assistant Surgeon to Guy's Hospital, 16, St. Thomas's-street, S.E.

1850 BIRKETT, EDMUND LLOYD, M.D., Consulting Physician to the City of London Hospital for Diseases of the Chest, 48, Russell-square, W.C. (C. 1856-7.)

O.M. BIRKETT, JOHN, Consulting Surgeon to Guy's Hospital, 59, Green-street, Grosvenor-square, W. (C. 1851. V.-P. 1860-2.)

1865 BISSHOPP, JAMES, Bedford-place, Tunbridge Wells.

1853 BLACK, CORNELIUS, M.D., Physician to the Chesterfield Dispensary, St. Mary's-gate, Chesterfield.

1877 BLACK, JAMES, 41, Aytoun-road, Brixton.

1850 BLAGDEN, ROBERT, Stroud, Gloucestershire.

1863 BLANCHET, JEAN B., M.D., M.S., Montreal, Quebec, Canada.

1876 BLASSON, WILLIAM, Edgeware, Middlesex.

1876 BOND, THOMAS, M.B., Assistant Surgeon and Lecturer on Forensic Medicine to Westminster Hospital, 50, Parliament-street, S.W.

Elected

1869 BOURNE, WALTER, M.D.

1861 BOWER, RICHARD NORRIS, 14, Doughty-street, Mecklenburg-square, W.C.

1851 BOWMAN, WILLIAM, F.R.S., Surgeon to the Royal Ophthalmic Hospital, 5, Clifford-street, Bond-street, W. (C. 1855-6.)

1877 BRIDGES, ROBERT, M.B., M.A. Oxford, Casualty Physician to St. Bartholomew's Hospital, 52, Bedford-square, W.C.

1867 BRIDGEWATER, THOMAS, M.B. Lond., Harrow-on-the-hill, Middlesex.

1873 BRIGGS, JACOB MYERS, M.D., Coeymans, New York, U.S.

1868 BRIGHT, G. C., M.B., 29, Lüttichanstrasse, Dresden.

1857 BRISCOE, JOHN, 12, Broad-street, Oxford.

†1851 BRISTOWE, JOHN S., M.D., Physician to, and Lecturer on the Theory and Practice of Medicine at, St. Thomas's Hospital, 11, Old Burlington-street, W. (C. 1854-8. S. 1861-4. C. 1865-7. V.-P. 1868-76.)

1860 BROADBENT, WILLIAM HENRY, M.D. Lond., Physician to St. Mary's Hospital, and Physician to the London Fever Hospital, 34, Seymour-street, Portman-square, W. (C. 1871-3.)

1877 BROCKMAN, E. F., Madras Medical Service, 18, Addison-gardens North, Kensington, W.

1852 BRODHURST, BERNARD E., Surgeon to the Royal Orthopædic Hospital, 20, Grosvenor-street, W. (C. 1862-4.)

1863 BRODIE, GEORGE BERNARD, M.D., Consulting Physician-Accoucheur to Queen Charlotte's Hospital, 3, Chesterfield-street, Mayfair, W.

1865 BROWN, AUGUSTUS, M.D., 29, Belitha-villas, Barnsbury-park, N.

1871 BROWN, FREDERICK GORDON, 16, Finsbury-circus, E.C.

1875 BROWNE, GEORGE BUCKSTONE, 40, Harley-street, W.

1866 BROWNE, LENNOX, Surgeon to the Central Throat and Ear Hospital, and to the Royal Society of Musicians, 36, Weymouth-street, Portland-place, W.

O.M. BROWNE, JOSEPH HULLETT, M.D., Physician to the St. Pancras Royal General Dispensary, 55, Gordon-square, W.C. (C. 1859-60.)

1877 BRUCE, J. MITCHELL, M.D., Assistant Physician to Charing Cross Hospital and to the Hospital for Consumption, Brompton, 60, Queen Anne-street, Cavendish-square, W.

1855 BRYANT, THOMAS (V.-P.), Surgeon to Guy's Hospital, 53, Upper Brook-street, Grosvenor-square, W. (C. 1863-6. V.-P. 1877-78.)

1854 BUCHANAN, GEORGE, M.D., Inspector Medical Department Local Government Board, 24, Nottingham-place, Marylebone-road, W. (C. 1864-6.)

1862 BUCHANAN, ALBERT, M.B. Lond., 382, Camden-road, N.

1858 BUDD, GEORGE, M.D., F.R.S., Ashleigh, Barnstaple. (C. 1862-4.)

1860 BURTON, ALFRED, 13, Dover-street, Piccadilly, W.

1853 BURTON, JOHN M., Lee-park Lodge, Lee, Kent, S.E.

Elected

1872 BUTLIN, HENRY TRENTHAM (C.), Surgical Registrar to St. Bartholomew's Hospital, Assistant Surgeon to the West London Hospital, 47, Queen Anne-street, W. (C. 1876-8.)

1866 BUTT, WILLIAM FREDERICK, 25, Park-street, Park-lane, W.

1856 BUZZARD, THOMAS, M.D., Physician to the National Hospital for the Epileptic and Paralysed, 56, Grosvenor-street, W. (C. 1869-70.)

1856 CALLENDER, G. W., F.R.S. (V.-P.), Surgeon to St. Bartholomew's Hospital, 7, Queen Anne-street, Cavendish-square, W. (C. 1865-9. V.-P. 1877-78.)

†O.M. CAMPS, WILLIAM, M.D. (C. 1856-9.)

‡1855 CARPENTER, ALFRED, M.D., High-street, Croydon.

1871 CARTER, CHARLES HENRY, M.D., B.S. Lond., Physician to the Hospital for Women, 45, Great Cumberland-place, Hyde-park, W.

1855 CARTER, H. VANDYKE, M.D., Professor of Anatomy and Physiology, Grant Medical College, Bombay. [22, Clarendon-road, Victoria-road, Kensington, W.]

1876 CARTER, ROBERT BRUDENELL, Ophthalmic Surgeon to, and Lecturer on Ophthalmic Surgery at, St. George's Hospital, 69, Wimpole-street, Cavendish-square, W.

1877 CASSON, JOHN HORNSBY, 25, Maddox-street, Bond-street, W.

†1868 CAVAFY, JOHN, M.D., Senior Assistant Physician to, and Lecturer on Physiology at, St. George's Hospital, 2, Upper Berkeley-street, Portman-square, W.

1864 CAY, CHARLES VIDLER, Coldstream Guards, the Hospital, Vincent-square, Westminster, S.W.

1863 CAYLEY, WILLIAM, M.D. (C.), Physician to, and Lecturer on the Principles and Practice of Medicine at, the Middlesex Hospital, 58, Welbeck-street, Cavendish-square, W. (C. 1870-1, 1875-8. S. 1872-4.)

1869 CHAFFERS, EDWARD, Keighley, Yorkshire.

1849 CHALK, WILLIAM OLIVER, 3, Nottingham-terrace, Regent's-park, N.W (C. 1856-7.)

1876 CHARLES, T. CRANSTOUN, M.D., M.C., Lecturer on Practical Physiology at St. Thomas's Hospital, 10, Mitre Court Chambers, Temple.

1870 CHEADLE, WALTER BUTLER, M.D., Assistant Physician to St. Mary's Hospital, and to the Hospital for Sick Children, Great Ormond-street, 2, Hyde-park-place, Cumberland-gate, W.

O.M. CHEVERS, NORMAN, M.D., India. (C. 1848.)

1858 CHILD, GILBERT W., 11, Norham-gardens, Oxford.

1873 CHISHOLM, EDWIN, M.D., 121, Macquarie-street, Sydney, New South Wales.

1855 CHOLMELEY, WILLIAM, M.D., Physician to the Great Northern Hospital, and to the Margaret-street Infirmary for Consumption, 63, Grosvenor-street, W. (C. 1871-3.)

1871 CHRISTIE, THOMAS BEATH, M.D., Superintendent of the Royal India Asylum, Ealing, Middlesex.

Elected

1865 CHURCH, WILLIAM SELBY, M.D., Physician to St. Bartholomew's Hospital, 130, Harley-street, Cavendish-square, W. (C. 1871-3.)

†1868 CHURCHILL, FREDERICK, M.B., Assistant Surgeon to the Victoria Hospital for Children, 6, Sumner-place, S.W.

1861 CLAPTON, EDWARD, M.D., 10A, St. Thomas's-street, Southwark, S.E.

1854 CLARK, ANDREW, M.D., Physician to the London Hospital, 16, Cavendish-square, W. (C. 1862-5.)

1872 CLARK, ANDREW, Assistant Surgeon to the Middlesex Hospital, 19, Cavendish-place, W.

1865 CLARKE, JACOB LOCKHART, M.D., F.R.S., 21, New Cavendish-street, W. (C. 1868-70.)

1867 CLARKE, WILLIAM FAIRLIE, M.A., Southborough, Tunbridge Wells. (C. 1873-5.)

1875 CLARKSON, JOHN, Surgeon in the India Department, Bombay Presidency, India.

1875 CLUTTON, HENRY HUGH, Resident Assistant Surgeon, St. Thomas's Hospital.

‡1865 COATES, CHARLES, M.D., Physician to the Bath General and Royal United Hospitals, 10, Circus, Bath.

1856 COCKLE, JOHN, M.D., M.A., Physician to the Royal Free Hospital, 7, Suffolk-place, Pall-mall, S.W.

O.M. COHEN, DANIEL WHITAKER, M.D., South-bank, Northdown-lane, Bideford, Devon.

†1866 COLES, GEORGE CHARLES, Surgeon to the Infirmary for Epilepsy and Paralysis, and Assistant Surgeon to the Royal South London and Central London Ophthalmic Hospitals, 20, Great Coram-street, Russell-square, W.C.

COLLEY, see DAVIES-COLLEY.

1858 COOKE, ROBERT THOMAS, Surgeon to the Scarborough Dispensary, 15, St. Nicholas-cliff, Scarborough, Yorkshire.

1871 COOKE, THOMAS, Assistant Surgeon to the Westminster Hospital, 16, Woburn-place, W.C.

1866 COOMBS, ROWLAND HILL, Mill-street, Bedford.

1851 COOPER, WILLIAM WHITE, Consulting Ophthalmic Surgeon to St. Mary's Hospital, 19, Berkeley-square, W. (C. 1860-2.)

1853 CORNISH, WILLIAM ROBERT, Surgeon-Major, Madras Army, Sanitary Commissioner for Madras.

1875 CORY, ROBERT, M.B., Assistant Obstetric Physician to St. Thomas's Hospital, 14, Palace-road, Albert Embankment, S.E.

1876 COTTLE, ERNEST WYNDHAM, M.A., Assistant Surgeon, Hospital for Diseases of the Skin, Blackfriars, 3, Savile-row.

1859 COULSON, WALTER J., Surgeon to the Lock Hospital, 17, Harley-street, Cavendish-square, W.

Elected

†1861 COUPER, JOHN, Surgeon to the London Hospital, 80, Grosvenor-street, Grosvenor-square, W. (C. 1870-2.)

1873 COUPLAND, SIDNEY, M.D. (C.), Assistant Physician to, and Lecturer on Pathological Anatomy at, the Middlesex Hospital, 7, Nottingham-place, W. (C. 1878.)

1873 CRIPPS, WILLIAM HARRISON, 61, Pall-mall.

O.M. CRISP, EDWARDS, M.D., 29, Beaufort-street, Chelsea, S.W. (C. 1846-7. V.-P. 1870-2.)

1848 CRITCHETT, GEORGE, Surgeon to the Royal London Ophthalmic Hospital, Moorfields, and Ophthalmic Surgeon to the Middlesex Hospital, 21, Harley-street, W. (S. 1849. C. 1851, 1858-9. V.-P. 1866-7.)

1877 CROCKER, HENRY RADCLIFFE, M.D., Assistant Medical Officer in the Skin Department, University College Hospital; Assistant Physician and Pathologist to the East London Hospital for Children, 135, Gower-street, W.C.

1856 CROFT, JOHN, Surgeon to St. Thomas's Hospital, 61, Brook-street, Grosvenor-square, W. (C. 1870-2.)

1861 CROSBY, THOMAS BOOR, M.D., 21, Gordon-square, W.C.

1875 CROSS, FRANCIS RICHARDSON, 17, Welbeck-street, Cavendish-square.

1854 CROSS, ROBERT, M.D., 42, Craven-street, Strand, W.C.

1864 CRUCKNELL, HENRY H., M.B. (C. 1875-76.)

1871 CUMBERBATCH, ELKIN, Demonstrator of Anatomy at St. Bartholomew's Hospital, 17, Queen Anne-street, W.

1858 CUMBERBATCH, LAURENCE T., M.D., 25, Cadogan-place, Sloane-street, S.W.

1855 CURLING, THOMAS BLIZARD, F.R.S., Consulting Surgeon to the London Hospital, 39, Grosvenor-street, W. (C. 1857-60. V.-P. 1866-8.)

1873 CURNOW, JOHN, M.D., Professor of Anatomy at King's College, and Assistant Physician to King's College Hospital, 3, Warwick-street, Cockspur-street, S.W.

‡1865 CURRAN, WILLIAM, M.D., Army Medical Staff. [Agent: Mr. H. K. Lewis, 136, Gower-street, W.C.]

1863 DANE, THOMAS, 86, Finchley-road, N.W.

1873 DAVIDSON, ALEXANDER, M.D., Physician to the Liverpool Royal Infirmary; Lecturer on Pathology at the Liverpool Medical School, 49, Rodney-street, Liverpool.

1869 DAVIES-COLLEY, J. N., M.B., Assistant Surgeon to Guy's Hospital, 36 Harley-street, Cavendish-square.

O.M. DAVIES, HERBERT, M.D., Consulting Physician to the London Hospital, and to the Infirmary for Asthma, 23, Finsbury-square, E.C. (C. 1849-50. V.-P. 1871.)

Elected

1847 DAVIS, JOHN HALL, M.D., Physician-Accoucheur to the Middlesex Hospital, and to the Royal Maternity Charity, 24, Harley-street Cavendish-square, W. (C. 1852-3.)

‡1859 DAVIS, FRANCIS WILLIAM, R.N., Surgeon to the Naval Medical Establishment, Lisbon. [Agents: Messrs. Hallett and Co., 7, St. Martin's-place, Trafalgar-square, W.C.]

1867 DAVY, RICHARD, Surgeon to, and Lecturer on Surgery at, the Westminster Hospital, 33, Welbeck-street, Cavendish-square, W.

1866 DAY, WILLIAM HENRY, M.D., Physician to the Samaritan Free Hospital for Women and Children, 10, Manchester-square, W.

1872 DECASTRO, JAMES C., M.B., Pau, France.

1871 DE LIEFDE TEMPLE, JOHN, M.D. [per Mr. James Nimmo, 7, Red Lion-court, Watling-street, E.C.].

1863 DEVEREUX, DANIEL, Tewkesbury.

1856 DICK, H., M.D., 59, Wimpole-street, Cavendish-square, W.

1871 DICKINSON, EDWARD HARRIMAN, M.A. Oxon., M.D., Physician to the Liverpool Northern Hospital, and Lecturer on Comparative Anatomy at the Liverpool School of Medicine, 162, Bedford-street, Liverpool.

1858 DICKINSON, WILLIAM HOWSHIP, M.D., Physician to the Hospital for Sick Children, Physician and Lecturer on Medicine to St. George's Hospital, 9, Chesterfield-street, Mayfair, W. (C. 1866-8. S. 1869-71. V.-P. 1872-4.)

1872 DIVER, EBENEZER, M.D., Kenley, Caterham-valley, Surrey.

O.M. DIXON, JAMES, Consulting Surgeon to the Royal Ophthalmic Hospital, Moorfields; Harrowlands, Dorking, Surrey. (C. 1852-6. V.-P. 1860-2.)

1872 DORAN, ALBAN HENRY GRIFFITHS, Surgeon to Out-Patients, Samaritan Hospital, Pathological Assistant to Museum, Royal College of Surgeons, 51, Seymour-street, Portman-square, W.

†1866 DOWN, JOHN LANGDON H., M.D., Physician to the London Hospital, 39, Welbeck-street, Cavendish-square, W. (C. 1872-4.)

1872 DOWSE, THOMAS STRETCH, M.D., 2, Old Burlington-street, Piccadilly, W.

1866 DREWRY, GEORGE OVEREND, M.D., 57, Queen Anne-street, W.

1865 DUCKWORTH, DYCE, M.D., Assistant Physician to St. Bartholomew's Hospital, 11, Grafton-street, Bond-street, W. (C. 1877.)

1863 DUDFIELD, THOMAS ORME, M.D., 8, Upper Phillimore-place, Kensington, W.

1847 DUDGEON, ROBERT E., M.D., 53, Montagu-square, W.

1852 DUFF, GEORGE, M.D., High-street, Elgin.

1865 DUFFIN, ALFRED BAYNARD, M.D., Physician to King's College Hospital, 18, Devonshire-street, Portland-place, W. (C. 1872-4.)

1875 DUKA, THEODORE, M.D., Surgeon-Major, H.M.'s Bengal Army; 38, Montagu-square, W.

Elected

1868 Duke, Oliver Thomas, M.B., India.

1871 Dukes, Clement, M.D., B.S., Horton-crescent, Rugby.

1877 Dunbar, J. J. M., Assistant House Physician to St. George's Hospital, 77, Ladbroke-grove, Kensington, W.

1877 Duncan, Andrew, 8, Henrietta-street, Covent-garden, W.C.

1861 Dunn, Robert William, 13, Surrey-street, Strand, W.C.

1865 Du Pasquier, Claudius Francis, Surgeon-Apothecary to the Queen, 62, Pall-mall, S.W.

1858 Durham, Arthur Edward, Surgeon to Guy's Hospital, 82, Brook-street, Grosvenor-square, W. (C. 1869-71.)

1867 Ellis, James, M.D., California.

1847 Ellis, James.

1878 Engelmann, George Julius, M.D., A.M., 3003, Locust-street, St. Louis, Miss., U.S.

1846 Erichsen, John Eric, F.R.S., Surgeon to University College Hospital, 6, Cavendish-place, Cavendish-square, W. (C. 1849-51. V.-P. 1863-4.)

1853 Evans, Conway, M.D., 5, Tavistock-street, Covent-garden, W.C. (C. 1867-8.)

1873 Evans, George Henry, M.D.

1875 Evans, Julian, A.M., M.D., Physician to the Victoria Hospital for Sick Children, 123, Finboro'-road, Redcliffe-square, West Brompton, S.W.

1876 Ewart, James Cossar, M.B., C.M., Curator, University College.

1877 Ewart, William, M.B., 33, Curzon-street, Mayfair, W.

‡1859 Ewens, John, Cotham Brow, Bristol.

1864 Fagge, Charles Hilton, M.D., Assistant Physician to, and Lecturer on Pathology at, Guy's Hospital, 11, St. Thomas's-street, Southwark, S.E. (C. 1870-2.)

1862 Farquharson, Robert, M.D., Assistant Physician to and Lecturer on Materia Medica at St. Mary's Hospital, 23, Brook-street, Grosvenor-square, W. (C. 1876-7.)

1872 Fayrer, Sir Joseph, C.S.I., M.D., F.R.S. Ed., Hon. Physician to the Queen, Surgeon-Major, Bengal Army, Examining Medical Officer to the Secretary of State for India in Council, 16, Granville-place, Portman-square, W.

1872 Fenn, Edward L., M.B., The Old Palace, Richmond.

1872 Fenwick, John C. J., M.D., Physician to the Durham County Hospital; Chilton Hall, Ferry-hill, and 16, Old Elvet, Durham.

1863 Fenwick, Samuel, M.D., Physician, with charge of out-patients to, and Lecturer on Medicine at, the London Hospital, 29, Harley-street, W.

1846 Fincham, George T., M.D., Physician to the Westminster Hospital, 13, Belgrave-road, S.W. (C. 1855.)

Elected

1876 FINLAY, DAVID W., M.D., Medical Registrar, Middlesex Hospital, 21, Montagu-street, Portman-square, W.

1870 FISH, JOHN CROCKETT, M.B., 92, Wimpole-street, W.

1859 FISHER, ALEXANDER, M.D., Assistant Surgeon, R.N., Her Majesty's Ship "Endymion."

1855 FLOWER, WILLIAM H., F.R.S., Conservator of the Museum, Royal College of Surgeons, 39, Lincoln's-inn-fields, W.C. (C. 1862-4.)

1872 FORBES, DANIEL MACKAY, L.R.C.P. Ed., Shoreditch Workhouse, Kingsland.

1852 FORBES, J. GREGORY, 82, Oxford-terrace, Hyde-park, W. (C. 1860-3.)

†O.M. FORSTER, JOHN COOPER, Surgeon to Guy's Hospital, 29, Upper Grosvenor-street, W. (C. 1857-8. V.-P. 1871-3.)

‡1866 FOSTER, BALTHAZAR WALTER, M.D., Physician to the General Hospital, Birmingham, 16, Temple-row, Birmingham.

1872 FOTHERBY, HENRY J., M.D., Physician to the Metropolitan Free Hospital, 3, Finsbury-square, E.C.

1878 FOX, THOMAS COLCOTT, M.B., B.A., 14, Harley-street, Cavendish-square, W.

1862 FOX, WILSON, M.D., Holme Professor of Clinical Medicine in University College, and Physician to University College Hospital, 67, Grosvenor-street, W. (C. 1868-70. V.-P. 1875-77.)

1865 FOX, W. TILBURY, M.D., Physician to the Skin Department of University College Hospital, 14, Harley-street, W.

1858 FRANCIS, CHARLES RICHARD, M.B., Bengal Medical Establishment, Indian Army.

O.M. FRERE, J. C.

1864 FRODSHAM, JOHN MILL, M.D., Streatham, S.W.

‡1858 GAIRDNER, WILLIAM TENNANT, M.D., Professor of Medicine in the University of Glasgow, 225, St. Vincent-street, Glasgow.

1870 GALTON, EDMUND H., Springfield House, Brixton-hill, S.W.

1870 GALTON, JOHN H., M.D., 1, Woodside, Anerley-road, Upper Norwood, S.E.

1855 GAMGEE, JOSEPH SAMPSON, Surgeon to the Queen's Hospital, Birmingham, 20, Broad-street, Birmingham.

1855 GAMGEE, J.

1877 GARLICK, GEORGE, M.D., 33, Great James-street, Bedford-row, W.C.

1846 GARROD, ALFRED BARING, M.D., F.R.S., Consulting Physician to King's College Hospital, 10, Harley-street, Cavendish-square, W. (C. 1851. V.-P. 1863-5.)

1872 GARTON, WILLIAM, Hardshaw-street, St. Helen's, Lancashire.

O.M. GAY, JOHN, Senior Surgeon to the Great Northern Hospital, 10, Finsbury-place South, E.C. (C. 1852-4. V.-P. 1870-2.)

1853 GIBBON, SEPTIMUS, M.D., 39, Oxford-terrace, Hyde-park, W.

1878 GIBBONS, R. A., M.D., 49, Great Ormond-street, W.C.

Elected

1876 Gill, John, M.D., Newton Abbot, Devon.

1873 Godlee, Rickman John, M.B., B.S. (C.), Assistant Surgeon to University College Hospital; Demonstrator of Anatomy University College; 22, Henrietta-street, Cavendish-square, W. (C. 1877-8.)

1875 Godson, Clement, M.D., Assistant Physician-Accoucheur to St. Bartholomew's Hospital, 8, Upper Brook-street, Grosvenor-square.

1871 Goodhart, James Frederick, M.D. (C.), Assistant Physician to, and Teacher of Clinical Medicine at, Guy's Hospital, 27, Weymouth-street, Portland-place, W. (C. 1876-8.)

1875 Gould, Alfred Pearce, M.S., Assistant Surgeon to, and Lecturer on Anatomy at, the Westminster Hospital, 93, Gower-street, W.C.

1870 Gowers, William Richard, M.D. (C.), Assistant Physician to University College Hospital, 50, Queen Anne-street, W. (C. 1878.)

1858 Gowlland, Peter Y., Surgeon to St. Mark's Hospital, 34, Finsbury-square, E.C.

1867 Green, T. Henry, M.D. (C.), Physician to Charing Cross Hospital, Assistant Physician to the Hospital for Consumption, Brompton, 74, Wimpole-street, W. (C. 1871-3, 1878. S. 1875-6.)

1873 Greenfield, William Smith, M.D., B.S. (C.), Assistant Physician to, and Lecturer on Morbid Anatomy at, St. Thomas's Hospital, 15, Palace-road, Albert Embankment, S.E. (C. 1877-8.)

1856 Greenhalgh, Robert, M.D., 72, Grosvenor-street, W.

‡1855 Greenhill, William Alexander, M.D., Carlisle-parade, Hastings.

1863 Greenhow, Edward Headlam, M.D., F.R.S. (V.-P.), Physician to the Middlesex Hospital, 14a, Manchester-square, W. (C. 1867-9. V.-P. 1877-8.)

1876 Griffiths, Thomas D., M.D., Hearne Lodge, Swansea.

1871 Grigg, William Chapman, M.D., Assistant Obstetric Physician to the Westminster Hospital, and Physician to the In-Patients, Queen Charlotte's Lying-in Hospital, 6, Curzon-street, Mayfair, W.

1861 Guéneau de Mussy, Henri, M.D., 15, Rue du Cirque, Paris.

1863 Gull, Sir William Withey, Bart., M.D., D.C.L., F.R.S., Consulting Physician to Guy's Hospital, 74, Brook-street, Grosvenor-square, W.

1876 Gwyther, James, M.B. Lond., St. Mary Church, Torquay.

1849-59 Habershon, Samuel Osborne, M.D., Physician to Guy's Hospital, 70, Brook-street, Grosvenor-square, W. (Re-elected 1874.) (C. 1855-6.

1851 Hacon, E. Dennis, 249, Mare-street, Hackney, N.E. (C. 1872.)

1877 Hallowes, Frederick Blackwood, Redhill, Surrey.

1848 Hare, Charles John, M.D., late Physician to University College Hospital, 57, Brook-street, Grosvenor-square, W. (C. 1852-4. V.-P. 1874-7.)

†1856 Harley, George, M.D., F.R.S. (V.-P.), 25, Harley-street, Cavendish-square, W. (C. 1862-5. V.-P. 1878.)

Elected

1872 HARRIS, HENRY, M.D., Trengweath-place, Redruth, Cornwall.

†1858 HART, ERNEST, 38, Wimpole-street, Cavendish-square, W. (C 1867-8.)

1870 HAWARD, JOHN WARRINGTON, Assistant Surgeon to St. George's Hospital, 5, Montagu-street, Portman-square, W.

O.M. HAWKINS, CÆSAR H., F.R.S., Consulting Surgeon to St. George's Hospital, 26, Grosvenor-street, W. (V.-P. 1846-51. *Pres.* 1852-3.)

1857 HAWKSLEY, THOMAS, M.D., Physician to the Margaret-street Dispensary for Consumption, 17, Cheyne-walk, Chelsea, S.W.

1869 HAY, THOMAS BELL, L.R.C.P. Ed., Christchurch, New Zealand.

1856 HEATH, CHRISTOPHER, Holme Professor of Clinical Surgery in University College, and Surgeon to University College Hospital, 36, Cavendish-square, W. (C. 1866-7.)

1878 HELLIER, JOHN B., M.B., Hospital for Women, Soho-square.

1869 HENSLEY, PHILIP J., M.D., Assistant Physician to St. Bartholomew's Hospital, 4, Henrietta-street, Cavendish-square, W.

‡1868 HESLOP, THOMAS P., M.D., Physician to the Children's Hospital, Birmingham.

O.M. HEWETT, PRESCOTT G., F.R.S., Consulting Surgeon to St. George's Hospital, 1, Chesterfield-street, Mayfair, W. (C. 1846-52. V.-P. 1854-7. *Pres.* 1863-4. V.-P. 1865-8.)

1855 HEWITT, GRAILY, M.D., Obstetric Physician to University College Hospital, 36, Berkeley-square, W. (C. 1865-7.)

1864 HICKMAN, WILLIAM, M.B., Surgeon to the Samaritan Free Hospital, 1, Dorset-square, N.W.

1860 HILL, M. BERKELEY, M.B., Surgeon to University College Hospital, and Surgeon for Out-Patients to the Lock Hospital, 55, Wimpole-street, Cavendish-square, W. (C. 1874-5.)

1875 HITCHCOCK, HARRY KNIGHT, M.D., St. Clare College Park, Lee, Lewisham, S.E.

1852 HOGG, JABEZ, Surgeon to the Westminster Ophthalmic Hospital, 1, Bedford-square, W.C. (C. 1860-2.)

1874 HOGGAN, GEORGE, M.B., 7, Trevor-terrace, Rutland-gate, S.W.

1847 HOLMAN, H. MARTIN, M.D., Hurstpierpoint, Sussex.

1854 HOLMES, TIMOTHY, Surgeon-in-Chief to the Metropolitan Police, Surgeon to St. George's Hospital, 18, Great Cumberland-place, Hyde-park, W. (C. 1862-3. S. 1864-7. C. 1868. V.-P. 1869-71.)

1850 HOLT, BARNARD WIGHT, Consulting Surgeon to the Westminster Hospital, 14, Savile-row, W. (C. 1853.)

O.M. HOLTHOUSE, CARSTEN, 15, George-street, Hanover-square, W. (C. 1852-4, V.-P. 1874-5.)

1878 HOOD, DONALD WILLIAM CHARLES, M.D., 43, Green-street, Park Lane.

Elected

1864 HOOD, WHARTON P., M.D., 65, Upper Berkeley-street, Portman-square, W.

1865 HOOPER, JOHN HARWOOD, M.B., 67, High-street, Wandsworth, S.W.

1870 HOPE, WILLIAM, M.D., 56, Curzon-street, Mayfair, W.

1877 HOUGHTON, WALTER B., M.D., Assistant Physician to Charing Cross Hospital, 26, Cavendish-square, W.

1866 HOWARD, EDWARD, M.D.

1875 HOWSE, HENRY GREENWAY, M.S. (C.), Surgeon to Guy's Hospital, and to the Evelina Hospital for Sick Children, 10, St. Thomas's-street, S.E. (C. 1878.)

†1856 HUDSON, JOHN, M.D., 11, Cork-street, Bond-street, W.

1854 HULKE, JOHN WHITAKER, F.R.S. (*Treasurer*), Surgeon to the Middlesex Hospital, and Surgeon to the Royal London Ophthalmic Hospital, 10, Old Burlington-street, W. (C. 1863-5. S. 1868-72. V.-P 1873-6, T. 1877-8.)

1854 HULME, EDWARD CHARLES, Woodbridge-road, Guildford.

1853 HUMBY, EDWIN, M.D., 83, Hamilton-terrace, St. John's Wood, N.W.

1874 HUMPHREYS, HENRY, M.D., Physician to the Children's Hospital at Pendlebury, 106, Eccles Old-road, Eccles, near Manchester.

1852 HUTCHINSON, JONATHAN, Surgeon to the London Hospital, and to the Royal London Ophthalmic Hospital, Moorfields, 15, Cavendish-square, W. (C. 1856-9. V.-P. 1872-3.)

1875 IRVINE, J. PEARSON, M.D., 3, Mansfield-street, Cavendish-square.

1865 JACKSON, J. HUGHLINGS, M.D., Physician to the London Hospital, Physician to the National Hospital for the Paralysed and Epileptic, 3, Manchester-square, W. (C. 1872-3.)

1876 JACKSON, ERNEST CARR, 91, Harley-street, Cavendish-square, W.

1875 JALLAND, WILLIAM HAMERTON, St. Leonard's House, Museum-street, York.

‡1853 JARDINE, JOHN LEE, Capel, near Dorking, Surrey.

1847 JAY, EDWARD, 112, Park-street, Grosvenor-square, W.

O.M. JENNER, SIR WILLIAM, Bart., M.D., D.C.L., K.C.B., F.R.S., Physician to University College Hospital, 63, Brook-street, Grosvenor-square, W. (C. 1850-3. V.-P. 1862-4, 1875-6. *Pres.* 1873-4.)

1875 JESSETT, FREDERIC BOWREMAN, Pier-road, Erith, Kent.

1866 JESSOP, THOMAS RICHARD, 31, Park-square, Leeds.

1878 JOHNSON, ARTHUR JUKES, Yorkville, Ontario, Canada.

1876 JOHNSON, CHARLES HENRY, late Staff Surgeon, Turkish Contingent.

O.M. JOHNSON, GEORGE, M.D., F.R.S., Physician to King's College Hospital, 11, Savile-row, W. (C. 1846-50. V.-P. 1863-4.)

1854 JOHNSTONE, ATHOL A. W., St. Moritz House, 61, Dyke-road, Brighton.

1853 JONES, SYDNEY, M.B., Surgeon to St. Thomas's Hospital, 16, George-street, Hanover-square, W. (C. 1864-6.)

Elected

1862 JONES, THOMAS RIDGE, M.D., Physician to the Victoria Hospital for Sick Children, 19, Chapel-street, Belgrave-square, S.W.

1858 JONES, WILLIAM PRICE, M.D., Claremont-road, Surbiton, Kingston.

1860 JONES, WALTER, College-yard, Worcester.

1867 KELLY, CHARLES, M.D., Medical Officer of Health for the West Sussex Combined Sanitary District, Worthing, Sussex. (C. 1874.)

1846 KENT, THOMAS J., 60, St. James's-street, S.W.

1852 KERSHAW, W. WAYLAND, M.D., Kingston-on-Thames.

1872 KESTEVEN, WILLIAM B., M.D., 401, Holloway-road, N.

1859 KIALLMARK, HENRY WALTER, 66, Prince's-square, Bayswater, W. (C. 1875-6.)

1867 KING, EDWIN HOLBOROW, Killcott, Godalming, Surrey.

1871 KING, ROBERT, M.B., Assistant Physician to the Middlesex Hospital, 48, Harley-street, W.

1852 KINGDON, J. ABERNETHY, Surgeon to the City Dispensary, and to the City of London Truss Society, 2, New Bank-buildings, Lothbury, E.C.

‡1856 KINGSLEY, HENRY, M.D., Physician to the Stratford Infirmary, Stratford-on-Avon, Warwickshire.

1878 KLEIN, EDWARD EMANUEL, M.D., F.R.S., 5, Longridge-road, Earl's-court, S.W.

1877 KNIGHT, CHARLES FREDERICK, 8, Northampton-square, Clerkenwell, E.C.

1875 KOCH, EDWIN LAWSON, M.D., Principal of the Medical School of Ceylon, Colombo, Ceylon. [Agents: Messrs. Henry S. King & Co., 65, Cornhill.]

1875 LACY, C. S. DE LACY, 5, Ovington-square, Brompton, S.W.

‡1865 LANCHESTER, HENRY THOMAS, M.D., 53, High-street, Croydon.

1877 LANG, ALEXANDER, M.B., 51, Warwick-road, S.W.

1851 LANGMORE, JOHN C., M.B., 20, Oxford-terrace, Hyde-park, W. (C. 1858-61.)

1865 LANGTON, JOHN, Assistant Surgeon to and Lecturer on Anatomy at St. Bartholomew's Hospital, and Surgeon to the City of London Truss Society, 2, Harley-street, Cavendish-square, W.

1869 LARCHER, O., M.D. Par., Laureate of the Institute of France, of the Medical Faculty and Academy of Paris, 97, Rue de Passy, Paris. [M. Kliensieck, Libraire, Rue de Lille, 11, Paris, per Messrs. Longman.]

1873 LATHAM, PETER WALLWORK, M.D., Physician to Addenbrooke Hospital, and Downing Professor of Medicine, Cambridge University, 17, Trumpington-street, Cambridge.

1876 LAW, WILLIAM THOMAS, M.D., Resident Medical Officer, Brompton Consumption Hospital.

1853 LAWRENCE, HENRY JOHN HUGHES, Surgeon, Grenadier Guards' Hospital, Rochester-row, Westminster, S.W. (C. 1873-5.)

Elected

1859 LAWSON, GEORGE, Surgeon to the Middlesex Hospital, and Surgeon to the Royal London Ophthalmic Hospital, Moorfields, 12, Harley-street, Cavendish-square, W. (C. 1870-1.)

1857 LEARED, ARTHUR, M.D., Physician to the Great Northern Hospital, 12, Old Burlington-street, W. (C. 1874-5.)

1875 LEDIARD, HENRY AMBROSE, M.D., Medical Superintendent to Cleveland-street Asylum, 42, Cleveland-street, Fitzroy-square.

1852 LEE, HENRY, Consulting Surgeon to St. George's Hospital, 9, Savile-row, W. (C. 1860-2. V.-P. 1875-6.)

1877 LEES, DAVID B., M.D., Assistant Physician to Charing Cross Hospital, and to the Hospital for Sick Children, 2, Thurloe Houses, Thurloe-square, S.W.

1867 LEES, JOSEPH, M.D., 21, Brixton-road, S.W.

1877 LEESON, ARTHUR EDMUND. M.A., M.D., 45, Devonshire-street, Portland-place, W.

1877 LEESON, JOHN RUDD, M.B., C.M., Bushey-park Cottage, Teddington.

1868 LEGG, JOHN WICKHAM, M.D., Lecturer on Pathological Anatomy, St. Bartholomew's Hospital, 47, Green-street, Park-lane, W. (C. 1874-5.)

1852 LEGGATT, ALFRED, 13, William-street, Lowndes-square, S.W. (C. 1866-7.)

‡1867 LEUDET, T. EMILE, M.D. Par., Professor of Clinical Medicine, 49, Boulevard Cauchoise, Rouen, France. [M. Kliensieck, Libraire, Rue de Lille, 11, Paris, per Messrs. Longman.]

1861 LICHTENBERG, GEORGE, M.D., 47, Finsbury-square, E.C.

1875 LINGARD, ALFRED, 2, Strand-terrace, Derby.

1877 LISTER, JOSEPH, F.R.S., Professor of Clinical Surgery at King's College and Surgeon to King's College Hospital, 12, Park Crescent, Regent's Park, W.

1878 LITTLEJOHN, SALTER G., M.B., C.M., Central London District Schools, Hanwell.

1848 LITTLE, WILLIAM JOHN, M.D., 18, Park-street, Grosvenor-square, W. (C. 1851-2. V.-P. 1856-9.)

†1862 LITTLE, LOUIS S., China. [18, Park-street.]

1874 LIVEING, EDWARD, M.D., 52, Queen Anne-street, Cavendish-square, W.

1863 LIVEING, ROBERT, M.D., Lecturer on Dermatology at the Middlesex Hospital, 11, Manchester-square, W. (C. 1876.)

1876 LONGHURST, ARTHUR EDWIN TEMPLE, M.D., 22, Wilton-street, S.W.

1873 LUCAS, R. CLEMENT, M.B., M.S., Assistant Surgeon to Guy's Hospital, 4, St. Thomas's-street, S.E.

1873 LUCEY, WILLIAM C., M.D., Ben Rhydding, by Leeds.

1876 LYELL, ROBERT WISHART, M.D., Surgical Registrar at the Middlesex Hospital, 26, Harley-street, Cavendish-square, W.

1877 LYNCH, GILBERT, M.B., 30, Sackville-street, Piccadilly, W.

Elected

1871 McCarthy, Jeremiah, M.A. (C.), Surgeon to the London Hospital, 26, Finsbury-square, E.C. (C. 1878.)

1873 McConnell, J. F., Professor of Pathology, Medical College, Calcutta. [Per Grindlay & Co., Parliament-street.]

1871 Mac Cormac, William (C.), Surgeon to St. Thomas's Hospital, 13, Harley-street, W. (C. 1878.)

1876 MacGrath, W. M., L.Q.K.C.P.I., 32, Colville-terrace, Bayswater, W.

1875 Mackellar, Alexander Oberlin, Assistant Surgeon, St. Thomas's Hospital, Albert Embankment, S.E.

1873 Mackellar, Peter H., M.B., Medical Officer, Fever Hospital, Stockwell, S.W.

1870 Mackenzie, George Welland, 15, Hans-place, Sloane-street, S.W.

1870 Mackenzie, John T., Bombay, India. [East India United Service Club, 14, St. James's-square.]

1864 Mackenzie, Morell, M.D., Physician to the Hospital for Diseases of the Throat, and Lecturer on Diseases of the Throat at the London Hospital, 19, Harley-street, Cavendish-square, W.

1865 MacLaurin, H. N., M.D.

1876 Maclean, Thomas Edwin, M.B., B.S.

1876 Macnamara, Charles, Surgeon to the Westminster Hospital, 13, Grosvenor-street, W.

1875 Mahomed, Frederick Akbar, M.D., Pathologist and Medical Tutor, St. Mary's Hospital, 31, Lower Seymour-street, W.

1877 Makins, George Henry, St. Thomas's Hospital, Albert Embankment, S.E.

1876 Mallam, Benjamin, Meadow Side, Leacroft-road, Staines.

1876 Maples, Reginald, Spalding, Lincolnshire.

1857 Marcet, William, M.D., F.R.S., Villa Bianca, Cannes. (C. 1869-71.)

1868 Marsh, F. Howard, Assistant Surgeon to the Hospital for Sick Children, Assistant Surgeon to St. Bartholomew's Hospital, 36, Bruton-street, Berkeley-square. (C. 1876-7.)

1876 Marshall, Francis John, St. George's Hospital.

1846 Marshall, John, F.R.S., Surgeon to University College Hospital, 10, Savile-row, W. (C. 1861.)

1856 Martin, Robert, M.D., 51, Queen Anne-street, Cavendish-square, W. (C. 1871-2.)

1860 Mason, Francis, Surgeon to St. Thomas's Hospital, 5, Brook-street, Grosvenor-square, W. (C. 1873-5.)

1867 Mason, Philip Brookes, Burton-on-Trent.

†1858 Maunder, Charles F., Surgeon to the London Hospital, 16, Queen Anne-street, Cavendish-square, W. (C. 1869-71.)

†1852 May, George, Jun., M.B., Surgeon, Royal Berkshire Hospital, Reading.

1874 Meredith, William Appleton, M.B., 14, Old Burlington-street, W.

1859 Messer, John Cockburn, M.D., Assistant Surgeon, R.N., Her Majesty's Ship "Edinburgh," Queensferry, N.B.

Elected

‡1867 MICKLEY, ARTHUR GEORGE, M.B., Derby-road, Nottingham.

1866 MICKLEY, GEORGE, M.A., M.B., St. Luke's Hospital, Old-street, E.C.

1877 MILNER, EDWARD, Surgical Registrar, St. Bartholomew's Hospital, 32, New Cavendish-street, Portland-place, W.

†1859 MONTEFIORE, NATHANIEL, 18, Portman-square, W.

1861 MOREHEAD, CHARLES, M.D., 11, North Manor-place, Edinburgh.

1847 MORGAN, JOHN, 3, Sussex-place, Hyde-park-gardens, W. (C. 1856-8.)

1875 MORGAN, JOHN H., 12, Chapel-street, Grosvenor-square.

1874 MORISON, ALEXANDER, M.B., C.M., 70, Marquess-road, Canonbury, N.

1869 MORRIS, HENRY, M.A., M.B. (C.), Assistant Surgeon to, and Lecturer on Practical Surgery at, the Middlesex Hospital, 2, Mansfield-street, Portland-place, W. (C. 1877-8.)

1875 MORTON, JOHN, M.B., Guildford.

1860 MOXON, WALTER, M.D. (V.P.), Physician to Guy's Hospital, 6, Finsbury-circus, E.C. (C. 1868-70, V.P. 1876-8.)

1878 MUMFORD, WILLIAM LUGAR, M.D., 1, Bartlett's-passage, Holborn-circus, E.C.

1876 MUNRO, WILLIAM, M.D., C.M., 102, Carl-street, Lower Broughton-road, Manchester.

1854 MURCHISON, CHARLES, M.D., LL.D. Edinb., F.R.S. (PRESIDENT), Physician to, and Lecturer on Clinical Medicine at, St. Thomas's Hospital, and Consulting Physician to the London Fever Hospital, 79, Wimpole-street, W. (C. 1859-62. S. 1865-8. T. 1869-76. *Pres.* 1877-8.)

1872 MURRAY, J. JARDINE, 99, Montpellier-road, Brighton.

1864 MYERS, ARTHUR B. R., Surgeon to 1st Battalion Coldstream Guards, Hospital, Vincent-square, Westminster, S.W. (C. 1872-3.)

1874 NANKIVELL, ARTHUR WOLCOT, St. Bartholomew's Hospital, Chatham.

1873 NETTLESHIP, EDWARD, 4, Wimpole-street, Cavendish-square, W.

1875 NEWBY, CHARLES HENRY, Surgical Registrar, St. Thomas's Hospital.

1865 NEWMAN, WILLIAM, M.D., Stamford, Lincolnshire.

1868 NICHOLLS, JAMES, M.D., Chelmsford, Essex.

1876 NICHOLSON, JOHN FRANCIS, St. Thomas's Hospital, S.E.

1865 NICOLL, CHARLES R., M.D., Resident Medical Officer to the Charter House, 17, Charterhouse-square, E.C. (C. 1872-3.)

1878 NOOTT, W. M., 8, Kensington-park-road, W.

1864 NORTON, ARTHUR T. (C.), Surgeon to St. Mary's Hospital, 6, Wimpole-street, Cavendish-square, W. (C. 1877-8.)

1856 NUNN, THOMAS WILLIAM (V.-P.), Senior Surgeon to the Middlesex Hospital, 8, Stratford-place, Oxford-street, W. (C. 1864-6. V.-P. 1878.)

1871 NUNNELEY, REV. FREDERICK BARHAM, M.D., Mickleover, Derbyshire.

1873 O'FARRELL, GEORGE PLUNKETT, M.B., Tangier House, Boyle, Ireland.

Elected

1850 OGLE, JOHN W., M.D., Consulting Physician to St. George's Hospital, 30, Cavendish-square, W. (C. 1855-6. S. 1857-60. C. 1861-3. V.-P. 1865-8.)

1876 OLIVER, JOHN FERENS, M.D., 12, Old Elvet, Durham.

1860 ORANGE, WILLIAM, M.D., Broadmoor, Wokingham, Berkshire.

1875 ORD, WILLIAM MILLER, M.B., Physician to, and Lecturer on Medicine at St. Thomas's Hospital, 7, Brook-street, Hanover-square, W.

1875 OSBORN, SAMUEL, 10, Maddox-street, Bond-street, W.

1876 OTTLEY, WALTER, M.B., 18, Weymouth-street, Portland-place, W.

1865 OWLES, JAMES ALLDEN, M.D., 204, Burlington-street, Liverpool.

1875 PAGE, HERBERT WILLIAM, M.A., M.C. Cantab., Assistant Surgeon to and Lecturer on Operative and Practical Surgery at St. Mary's Hospital, 28, New Cavendish-street, W.

1870 PAGET, SIR JAMES, Bart., D.C.L., F.R.S., Consulting Surgeon to St. Bartholomew's Hospital, 1, Harewood-place, Hanover-square, W.

1872 PARKER, ROBERT WILLIAM, 8, Old Cavendish-street, W.

1874 PARKER, RUSHTON, M.B., B.S., 69, Rodney-street, Liverpool.

1853 PARKINSON, GEORGE, 50, Brook-street, Grosvenor-square, W.

1865 PAVY, FREDERICK WILLIAM, M.D., F.R.S., Physician to Guy's Hospital, 35, Grosvenor-street, W. (C. 1872-4.)

1868 PAYNE, JOSEPH FRANK, B.A., M.B., Assistant Physician to, and Lecturer on Forensic Medicine at, St. Thomas's Hospital, 78, Wimpole-street, W. (C. 1873-5.)

O.M. PEACOCK, THOMAS BEVILL, M.D. (TRUSTEE), Physician to St. Thomas's Hospital, and Physician to the City of London Hospital for Diseases of the Chest, 20, Finsbury-circus, E.C. (C. 1846-9. S. 1850-1. V.-P. 1852-6. C. 1858-61. *Pres.* 1865-6. V.-P. 1867-70.)

1872 PEARCE, JOSEPH CHANING, M.B., C.M., The Manor House, Brixton-rise, S.W.

1878 PEARSE, THOMAS FREDERICK, M.D., 141, Finborough-road, S.W.

1868 PEARSON, DAVID R., M.D., 23, Upper Phillimore-place, Kensington, W.

1878 PHILIPPS, SUTHERLAND REES, M.D., 3, Berkeley-place, Cheltenham.

1871 PHILLIPS, CHARLES DOUGLAS F., M.D., 107, Lancaster-gate, W.

1878 PHILLIPS, JOHN WALTER, 13, Cardington-street, Hampstead-road, N.W.

1877 PHILLIPS, RICHARD, 27, Leinster-square, Bayswater, W.

1875 PHILPOT, HARVEY JOHN, Dyer-street, Cirencester.

1863 PICK, THOMAS PICKERING, Surgeon to, and Lecturer on Anatomy at, St. George's Hospital, 13, South Eaton-place, S.W. (C. 1870-1.)

1878 PINK, THOMAS, Stratford St. Mary, near Colchester, Essex.

1875 PITMAN, HENRY A., M.D., Consulting Physician to St. George's Hospital, 28, Gordon-square, W.C.

1867 PITT, EDWARD G., M.D., Hastings.

Elected

1876 PITTS, BERNARD, M.A., M.B., Tharning Rectory, Oundle, Huntingdonshire.

1862 POLLOCK, ARTHUR JULIUS, M.D., Physician to Charing Cross Hospital, 85, Harley-street, Cavendish-square, W. (C. 1874-5.)

1846 POLLOCK, GEORGE D., Surgeon to St. George's Hospital, 36, Grosvenor-street, W. (S. 1850-3. C. 1854-6. V.-P. 1863-5. P. 1875-6.)

1850 POLLOCK, JAMES EDWARD, M.D., Physician to the Hospital for Consumption and Diseases of the Chest, Brompton, 52, Upper Brook-street, W. (C. 1862-4.)

1870 POORE, GEORGE VIVIAN, M.B., Assistant Physician to University College Hospital, 30, Wimpole-street, W.

1876 PORT, HEINRICH, M.D., 48, Finsbury-square, E.C.

1854 POTTS, WILLIAM, 26, South Audley-street, Grosvenor-street, W. (C. 1870-2.)

1866 POWELL, RICHARD DOUGLAS, M.D. (HON. SECRETARY), Physician to the Hospital for Consumption and Diseases of the Chest, Brompton, 15, Henrietta-street, Cavendish-square, W. (C. 1873-5. S. 1877-8.)

1865 POWER, HENRY, Ophthalmic Surgeon to St. Bartholomew's Hospital, 37A, Great Cumberland-place, Hyde-park, W. (C. 1876-7.)

1856 PRIESTLEY, WILLIAM OVEREND, M.D., Consulting Physician-Accoucheur to King's College Hospital, and to the St. Marylebone Infirmary, 17, Hertford-street, Mayfair, W.

†1848 PURNELL, JOHN JAMES, Surgeon to the Royal General Dispensary, Woodlands, Streatham-hill, S.W. (C. 1858-61.)

1865 PYE-SMITH, PHILIP HENRY, M.D., Assistant Physician to, and Lecturer on Physiology at, Guy's Hospital, 56, Harley-street, Caven-, dish-square, W. (C. 1874-7.)

O.M. QUAIN, RICHARD, M.D., F.R.S. (TRUSTEE), Consulting Physician to the Hospital for Consumption and Diseases of the Chest, Brompton, 67, Harley-street, Cavendish-square, W. (C. 1846-51. S. 1852-6. T. 1857-68. *Pres.* 1869-70. V.-P. 1871-3.)

1859 RADCLIFFE, CHARLES BLAND, M.D., Physician to the Westminster Hospital, 25, Cavendish-square, W.

1872 RALFE, CHARLES HENRY, M.D., M.A. (C.), Physician to the Seamen's Hospital, Lecturer on Physiological Chemistry at St. George's Hospital, 26, Queen Anne-street, W. (C. 1877-8.)

1857 RAMSKILL, J. SPENCE, M.D., Physician to the London Hospital, Physician to the National Hospital for the Paralysed and Epileptic, 5, St. Helen's-place, Bishopsgate-street, E.C.

1848 RANDALL, JOHN, M.D., Medical Officer, St. Marylebone Infirmary, 35, Nottingham-place, W. (C. 1864-6.)

1875 RANGER, W. G., 4, Finsbury-square.

1857 RANKE, HENRY, M.D., Munich.

Elected

1865 RASCH, ADOLPHUS A., M.D., Physician for Diseases of Women to the German Hospital, 7, South-street, Finsbury-square, E.C.

1870 RAY, EDWARD REYNOLDS, Dulwich, S.E.

1871 RAYNER, HENRY, M.D., Lecturer on Mental Diseases at St. Thomas' Hospital, Medical Superintendent, Middlesex County Lunatic Asylum, Hanwell, W.

1858 REED, FREDERICK GEORGE, M.D., 46, Hertford-street, Mayfair, W.

1866 REEVES, HENRY ALBERT, Assistant Surgeon to the London Hospital, 8, Grovenor Street, W.

1875 REID, ROBERT WILLIAM, M.B., St. Thomas's Hospital.

1854 REYNOLDS, J. RUSSELL, M.D., F.R.S., Consulting Physician to University College Hospital, 38, Grosvenor-street, W. (C. 1868-9.)

1871 RICHARDS, J. PEEKE, Medical Superintendent, Middlesex County Lunatic Asylum, Hanwell, W.

1866 RIVINGTON, WALTER, M.S. Lond., Surgeon to the London Hospital, 22, Finsbury-square, E.C.

‡1865 ROBERTS, DAVID LLOYD, M.D., Physician to St. Mary's Hospital, Manchester, 23, St. John's-street, Manchester.

1871 ROBERTS, FREDERICK THOMAS, M.D., Professor of Materia Medica at University College, Assistant Physician, University College Hospital, and to the Hospital for Consumption, &c., Brompton, 53, Harley-street, Cavendish-square, W.

1878 ROBERTS, WILLIAM HOWLAND, M.D., Surgeon, Madras Army, East India United Service Club, St. James's Square.

1859 ROBINSON, FREDERICK, M.D., Surgeon-Major, Scots Fusilier Guards, 47, Claverton-terrace, St. George's-road, S.W. (C. 1871-3.)

1856 ROBINSON, THOMAS, M.D., 35, Lamb's Conduit-street, W.C.

1858 ROLLESTON, GEORGE, M.D., F.R.S., Linacre Professor of Anatomy, University of Oxford, Park Grange, Oxford.

1876 ROPER, ARTHUR, 17, Granville Park, Blackheath.

1858 ROSE, HENRY COOPER, M.D., Surgeon to the Hampstead Dispensary, High-street, Hampstead. (C. 1873-4.)

1876 ROSE, WILLIAM, M.B., B.S., Assistant Surgeon to King's College, 21, Welbeck Street, Cavendish-square, W.

1875 ROSSITER, GEORGE FREDERICK, 14, Melina-crescent, Weston-super-Mare.

1877 ROTH, BERNARD, M.S., 48, Wimpole Street, Cavendish Square, W.

1858 ROUSE, JAMES, Surgeon to St. George's Hospital, 2, Wilton-street, Grosvenor-place, S.W.

1869 RUTHERFORD, WILLIAM, M.D., F.R.S., Professor of Physiology in the University of Edinburgh.

1858 SALTER, JAMES A., M.B., F.R.S., Dental Surgeon to Guy's Hospital, 17, New Broad-street, City, E.C. (C. 1861-3.)

Elected

1852 SANDERSON, HUGH JAMES, M.D., 26, Upper Berkeley-street, Portman-square, W.

1854 SANDERSON, JOHN BURDON, M.D., F.R.S., Jodrell Professor of Human Physiology at University College (C. 1864-7. V.-P. 1873-4.), 26, Gordon-square, W.C.

1877 SANGSTER, ALFRED, M.B., B.A., 57, Welbeck Street, Cavendish-square, W.

1875 SANGSTER, CHARLES, 148, Lambeth-road, S.E.

1877 SANKEY, H. R. O., Sandywell-park, near Cheltenham.

‡1847 SANKEY, W. H. OCTAVIUS, M.D., Sandywell-park, near Cheltenham. (C. 1855.)

1871 SAUNDERS, CHARLES EDWARD, M.D., 21, Lower Seymour-street, Portman-square, W.

1873 SAVAGE, GEORGE HENRY, M.D., Lecturer on Mental Diseases at Guy's Hospital, Bethlem Royal Hospital, St. George's-road, S.E.

1854 SCOTT, JOHN, 10, Tavistock-square, W.C.

‡1847 SEATON, EDWARD C., M.D., Medical Officer of the Local Government Board, 14, Gordon-street, Gordon-square, W.C. (C. 1859-61.)

1877 SEMON, FÉLIX, M.D., 6, Chandos-street, Cavendish-square.

1852 SEMPLE, ROBERT HUNTER, M.D., Physician to the Bloomsbury Dispensary, 8, Torrington-square, W.C. (C. 1859-61.)

1872 SERGEANT, EDWARD, Medical Officer of Health, Bolton, Yorkshire.

1876 SHARKEY, SEYMOUR, M.D., St. Thomas's Hospital, S.E.

1877 SHEPPARD, CHARLES E., 7, Addison-gardens, W.

1856 SHILLITOE, BUXTON, Surgeon to the Great Northern Hospital, and to the Lock Hospital, 2, Frederick's-place, Old Jewry, E.C.

1855 SIBLEY, SEPTIMUS W., 4, Savile Row, W. (C. 1863-5.)

1875 SIDDALL, JOSEPH BOWER, M.D., C.M., 24, The Mall, Clifton, Bristol.

1847 SIEVEKING, EDWARD H., M.D., Physician to St. Mary's Hospital, 17, Manchester-square, W. (C. 1854-7. V.-P. 1864-5.)

O.M. SIMON, JOHN, C.B., D.C.L., F.R.S., Consulting Surgeon to St. Thomas's Hospital, 40, Kensington-square, W. (C. 1846-8. V.-P. 1855-9. *Pres.* 1867-8. V.-P. 1869-71.)

1866 SIMS, FRANCIS MANLEY BOLDERO, Assistant Surgeon to the Hospital for Diseases of the Skin, and Surgeon to the St. George's Dispensary, 25, Half-moon-street, Piccadilly, W.

1865 SIMS, J. MARION, M.D., 267, Madison-avenue, New York.

1877 SKINNER, WILLIAM A., 45, Upper Belgrave-street, W.

1875 SMEE, ALFRED HUTCHINSON, 7, Finsbury-circus, E.C.

1872 SMITH, GILBART, M.B., Assistant Physician to the London Hospital, Physician to the Royal Hospital for Diseases of the Chest, City-road, Visiting Physician to the Margaret-street Infirmary for Consumption, 68, Harley-street, Cavendish-square, W.

1875 SMITH, GEORGE JOHN MALCOLM, M.B., Hurstpierpoint, Sussex.

Elected

1863 SMITH, HENRY, Surgeon to, and Professor of Surgery at, King's College Hospital, 82, Wimpole-street, Cavendish-square, W. (C. 1873-4.)

1866 SMITH, HEYWOOD, M.D., Physician to the Hospital for Women, 2, Portugal-street, Grosvenor-square, W.

SMITH (P. H. PYE), see PYE-SMITH.

1846 SMITH, PROTHEROE, M.D., Physician to the Hospital for Women, 42, Park-street, Grosvenor-square, W.

1873 SMITH, RICHARD T., M.D., Physician to the St. Pancras Dispensary, 53, Haverstock-hill, N.W.

1869 SMITH, ROBERT SHINGLETON, M.D., Lecturer on Physiology, Bristol Medical School, 32, Oakfield-road, Clifton, Bristol.

1878 SMITH, HERBERT WINSON, M.B., St. Thomas's Hospital.

1856 SMITH, SPENCER, Consulting Surgeon to St. Mary's Hospital, 92, Oxford-terrace, W.

1856 SMITH, THOMAS (V.-P.), Surgeon to St. Bartholomew's Hospital, 5, Stratford-place, Oxford-street, W. (C. 1867-9. V.-P. 1877-8.)

1866 SMITH, WILLIAM, Melbourne, Australia.

1870 SMITH, WILLIAM JOHNSON, Surgeon, Seamen's Hospital, Greenwich, S.E.

1869 SMITH, WILLIAM WILBERFORCE, M.D., 2, Eastbourne-terrace, Bishop's-road, W.

1870 SNOW, WILLIAM VICARY, M.D., Richmond Gardens, Bournemouth.

1868 SOUTHEY, REGINALD, M.D., Physician to St. Bartholomew's Hospital, 6, Harley-street, Cavendish-square, W.

1873 SPARKS, EDWARD ISAAC, M.B. [abroad].

1868 SPRY, G. FREDERICK HUME, M.D., 2nd Life Guards, Army and Navy Club, Pall-mall, S.W.

1855 SQUIRE, WILLIAM, M.D., 6, Orchard-street, Portman-square, W. (C. 1870-2.)

1861 SQUIRE, ALEXANDER BALMANNO, 24, Weymouth-street, Portland-place, W.

1876 STARTIN, JAMES, 17, Sackville-street, Piccadilly, W.

1854 STEWART, WILLIAM EDWARD, 16, Harley-street, Cavendish-square, W.

†1853 STREATFEILD, J. F., Surgeon to the Royal London Ophthalmic Hospital, Moorfields, and Ophthalmic Surgeon to University College Hospital, 15, Upper Brook-street. W.

1875 STURGE, W. A., M.D., 9, Wimpole-street, Cavendish-square, W.

1863 STURGES, OCTAVIUS, M.D., Physician to the Westminster Hospital, 85, Wimpole-street, W.

1871 SUTHERLAND, HENRY, M.D., 6, Richmond-terrace, Whitehall, S.W.

1876 SUTRO, SIGISMUND, M.D., Senior Physician to the German Hospital, 37A, Finsbury-square.

1864 SUTTON, HENRY G., M.B., Physician to, and Lecturer on Medicine at, the London Hospital, Physician to the City of London Hospital for Diseases of the Chest, 9, Finsbury-square, E.C. (C. 1875-6.)

Elected

‡1867 SWAIN, WILLIAM PAUL, 20, Ker-street, Devonport.

‡1857 SYMONDS, FREDERICK, Surgeon to the Radcliffe Infirmary, 35, Beaumont-street, Oxford.

1870 TAIT, ROBERT LAWSON, Surgeon to the Birmingham and Midland Hospital for Women, 7, Great Charles-street, Birmingham.

‡1856 TAPP, W. DENNING, Hillside-house, Hatherley-road, Cheltenham.

1864 TATHAM, JOHN, M.D., Physician to the Hospital for Consumption and Diseases of the Chest, Brompton., 1, Wilton-place, Belgrave-square, S.W.

1870 TAY, WARREN, Surgeon to, and Demonstrator of Practical Anatomy at, the London Hospital, 4, Finsbury-square, E.C.

1871 TAYLOR, FREDERICK, M.D., Assistant Physician to Guy's Hospital, 15, St. Thomas's-street, S.E.

1861 TEEVAN, WILLIAM FREDERIC, Surgeon to the West London Hospital, 10, Portman-square, W.

1870 THOMAS, JOHN DAVIES, M.B., University College Hospital (India).

1852 THOMPSON, SIR HENRY, Knt., Emeritus Professor of Clinical Surgery in University College, 35, Wimpole-street, Cavendish-square, W. (S. 1859-63. C. 1865-67. V.-P. 1868-70.)

1874 THORNTON, JOHN KNOWSLEY, M.B., Surgeon to the Samaritan Free Hospital for Women and Children, 83, Park-street, Grosvenor-square.

1872 THORNTON, WILLIAM PUGIN, Surgeon to the Hospital for Diseases of the Throat, and to the St. Marylebone General Dispensary, 42, Devonshire-street, Portland-place, W.

1865 THOROWGOOD, J. C., M.D. (C.), Lecturer on Materia Medica at the Middlesex Hospital, Physician to the City of London Hospital for Diseases of the Chest, 61, Welbeck-street, W. (C. 1876-78.)

1877 TIBBITS, HERBERT, F.R.C.P. Ed., Medical Superintendent of the National Hospital for the Paralysed and Epileptic, 30, New Cavendish-street, W.

1856 TOMES, J., F.R.S., Consulting Dental Surgeon to the Middlesex Hospital, 37, Cavendish-square, W. (C. 1867-9.)

1864 TONGE, MORRIS, M.D., Harrow-on-the-hill, Middlesex.

1872 TOWNSEND, THOMAS SUTTON, 68, Queen's Gate, South Kensington.

1851 TROTTER, JOHN W., Surgeon-Major, Coldstream Guards, Bossall Vicarage, York. (C. 1865-9.)

1859 TRUMAN, EDWIN THOMAS, Surgeon-Dentist in Ordinary to Her Majesty's Household, 23, Old Burlington-street, W.

1867 TUCKWELL, HENRY MATTHEWS, M.D., Physician to the Radcliffe Infirmary, 64, High-street, Oxford.

1858 TUDOR, JOHN, Dorchester, Dorset.

†1875 TURNER, FRANCIS CHARLEWOOD, M.D., Physician to the London Hospital, 15, Finsbury-square, E.C.

Elected

1863 TURNER, JAMES SMITH, Dental Surgeon to the Middlesex Hospital, 12, George-street, Hanover-square, W.

1858 TURTLE, FREDERICK, Clifton Lodge, Woodford, Essex.

1878 TYRRELL, WALTER, St. Thomas's Hospital.

1854 VASEY, CHARLES, 5, Cavendish-place, Cavendish-square, W.

1867 VENNING, EDGCOMBE, Assistant Surgeon, 1st Life Guards, Knightsbridge Barracks, 87, Sloane-street.

1875 VERDON, WALTER.

1868 VINCENT, OSMAN, Surgeon to the National Orthopædic Hospital, 45, Seymour-street, Portman-square, W.

†1867 WAGSTAFFE, WILLIAM WARWICK, B.A., Assistant Surgeon to St. Thomas's Hospital, 2, Palace-road, Albert Embankment, S.E. (C. 1874, C. 1878, S. 1875-7.)

O.M. WAITE, CHARLES D., M.D., Senior Physician to the Westminster General Dispensary, 3, Old Burlington-street, W.

1873 WALSHAM, WILLIAM J., M.B., C.M., Demonstrator of Anatomy and Operative Surgery at St. Bartholomew's Hospital, 27, Weymouth-street, Portland-place.

1859 WALTERS, JOHN, M.B., Reigate, Surrey.

1847 WARD, T. OGIER, M.D., 12, Place de la Mare, Caen. (C. 1851-3.)

1858 WARDELL, JOHN RICHARD, M.D., Calverley-park, Tunbridge Wells.

1877 WARNER, FRANCIS, M.D., 15, Finsbury-square, E.C.

1878 WATNEY, HERBERT, M.D., Lecturer on Materia Medica at St. George's Hospital, 1, Wilton-crescent, S.W.

1877 WATERHOUSE, CHARLES, M.B., M.C., Aigburth, Liverpool.

1855 WATSON, SIR THOMAS, Bart., M.D., F.R.S., 16, Henrietta-street, Cavendish-square, W. (*Pres.* 1857-8. V.-P. 1859-63.)

1865 WATSON, W. SPENCER, Surgeon to the Great Northern Hospital, Surgeon to the Royal South London Ophthalmic and to the Central London Ophthalmic Hospitals, 7, Henrietta-street, Cavendish-square, W. (C. 1875-6.)

1860 WAY, JOHN, M.D., 4, Eaton-square, S.W. (C. 1873-4.)

†1858 WEBER, HERMANN, M.D. (V.-P.), Physician to the German Hospital, 10, Grosvenor-street, Grosvenor-square, W. (C. 1867-70. V.-P. 1878.)

1876 WEIR, ARCHIBALD, M.D., St. Mungho's, Great Malvern.

1864 WELCH, THOMAS DAVIES, M.D., Wilton Lodge, Queen's-road, Weybridge, Surrey.

1861 WELLS, JOHN SOELBERG, Ophthalmic Surgeon to King's College Hospital, and Surgeon to the Royal London Ophthalmic Hospital, 16, Savile-row, W.

1853 WELLS, THOMAS SPENCER, Surgeon to the Samaritan Free Hospital for Women and Children, 3, Upper Grosvenor-street, W. (C. 1865-8. V.-P. 1876-7.)

Elected

†1851 West, Charles, M.D., Consulting Physician to the Hospital for Sick Children, 61, Wimpole-street, Cavendish-square, W. (C. 1856-7.)

1877 West, Samuel, M.B., Assistant Physician to the City of London Hospital for Diseases of the Chest, Victoria-park, 8, Guilford-street, Russell-square, W.C.

1867 Whipham, Thomas Tillyer, M.B., Physician to, and Lecturer on Pathology at, St. George's Hospital, 37, Green-street, Grosvenor-square, W.

1869 Whipple, John H. C., M.D., Assistant Surgeon, 1st Battalion Coldstream Guards, Hospital, Vincent-square, Westminster, S.W.

1877 White, Charles Haydon, Brathay House, Tufnell-park, N.

‡1868 Whitehead, Walter, 248, Oxford-road, Manchester.

1877 Whitmore, William Tickle, 7, Arlington-street, S.W.

1870 Wickstead, Francis William, Field House, Walthamstow, Essex.

1867 Wilcox, Richard Wilson, Temple-square, Aylesbury, Bucks.

1869 Wilkin, John F., M.D., M.C., New Beckenham, Kent.

1871 Wilkinson, J. Sebastian, Surgeon to the Central London Ophthalmic Hospital, 83, Wimpole-street, W.

1864 Wilks, Alfred G. P., M.A., M.B., Charlemont House, Spencer-road, Ryde, Isle of Wight.

1855 Wilks, Samuel, M.D., F.R.S., Physician to Guy's Hospital, 77, Grosvenor-street, W. (C. 1857-60. V.-P. 1869-72.)

1869 Williams, Albert, M.B., 4, York-terrace, Dartmouth-road, Sydenham, S.E.

O.M. Williams, C. J. B., M.D., F.R.S., Consulting Physician to the Hospital for Consumption and Diseases of the Chest, Brompton [47, Upper Brook-street, Grosvenor-square, W.]. (*Pres.* 1846-7. V.-P. 1848-52. C. 1853-5. V.-P. 1858-61.)

‡1858 Williams, Charles, Assistant Surgeon to the Norfolk and Norwich Hospital, 9, Prince of Wales-road, Norwich.

1866 Williams, Charles Theodore, M.B. (C.), Physician to the Hospital for Consumption and Diseases of the Chest, Brompton, 47, Upper Brook-street, Grosvenor-square, W. (C. 1875-8.)

1872 Williams, John, M.D. (C.), Assistant Obstetric Physician to University College Hospital, 28, Harley-street, Cavendish-square, W. (C. 1878.)

1864 Williams, W. Rhys, M.D., Bethlem Royal Hospital, Lambeth-road, S.E.

1876 Williamson, James Mann, M.D., Ventnor, Isle of Wight.

1863 Willis, Francis, M.D., Braceborough, Stamford.

1859 Wilson, Edward Thomas, M.B., Montpelier-terrace, Cheltenham.

1859 Wilson, Robert James, F.R.C.P. Ed., 7, Warrior-square, St. Leonard's-on-Sea.

1863 Wiltshire, Alfred, M.D., Joint Lecturer on Midwifery at St. Mary's Hospital, 57, Wimpole street, Cavendish-square, W.

Elected

‡1861 WINDSOR, THOMAS, Surgeon to the Salford Royal Hospital, 44, Ardwick-green, Manchester.

1874 WISEMAN, JOHN GREAVES, Dearden-street, Ossett, Yorkshire.

1865 WITHERBY, WILLIAM H., M.D., Pitt-place, Coombe, Croydon.

1850 WOOD, JOHN, F.R.S., Surgeon to, and Professor of Clinical Surgery at, King's College Hospital, 68, Wimpole-street, W. (C. 1857-9. V.-P. 1872-4.)

1854 WOOD, WILLIAM, M.D., Physician to St. Luke's Hospital, 99, Harley-street, W.

1876 WOOD, WILLIAM EDWARD RAMSDEN, M.A., M.B. Cantab., 99, Harley-street, W.

1877 WOODHOUSE, THOMAS JAMES, M.D., Ranelagh Lodge, Bridge-street, Fulham, S.W.

1865 WORKMAN, CHARLES JOHN, M.D., Titherley, Teignmouth, Devon.

1863 WORLEY, WILLIAM CHARLES, 1, New North-road, Hoxton, N.

1859 WOTTON, WILLIAM GORDON, King's Langley, Herts.

1852 WRIGHT, EDWARD JOHN, 169, Clapham-road, S.W.

1869 WYMAN, W. S., M.D., Westlands, Upper Richmond-road, Putney, S.W.

1862 YEO, J. BURNEY, M.D., Physician with Charge of Out-Patients to King's College Hospital, and Assistant Physician to the Brompton Hospital for Consumption, 44, Hertford-street, Mayfair, W.

1872 YOUNG, HENRY, M.B., Monte Video, South America.

ANNUAL REPORT OF COUNCIL.

1877-78.

THE Council feel that they have reason to congratulate the Society upon the work of the past year—upon work done and upon equally important work inaugurated during this period; and they can point with satisfaction to the fact that the average attendance at the meetings has exceeded that of any previous year as evidence that the labours of the Society have been appreciated by the profession at large.

The total number of members is now 601, and of these 32 have been added during the financial year. Five members have been removed by death—Sir William Fergusson, Bart., F.R.S., Dr. Snow Beck, F.R.S., Mr. William Coulson, Dr. Basham, and Dr. William Carr. Sir William Fergusson had been an able and esteemed President of the Society, and Mr. William Coulson had held the office of Vice-President; and to each of them the Society was much indebted for active work in the early days of its existence. During the past year eight members have retired.

The Council have during the past session set apart certain evenings for the exhibition of specimens illustrating the pathology of visceral syphilis, and they feel that in so doing they have been the means of directing attention to a subject not hitherto sufficiently studied, and also of bringing to light facts and specimens of considerable value, which will advance our knowledge of this important subject. The numerous contributions bearing upon this, and published in the 'Transactions,' will, they think, render the 28th volume of the Reports of more than ordinary value, and the Council tender their thanks to those gentlemen who brought the results of their labours and experience before the Society. The success of this plan of setting apart evenings for the exhibition of allied speci-

mens has induced the Council to continue it in the current season, and the subject they have chosen for illustration is Diseases of the Lymphatic System, including Lymphadenoma and Leukæmia. They anticipate with confidence that the exhibition and careful examination of specimens of such diseases will show results not less interesting and important than those which have followed from the consideration of visceral syphilis.

But besides the subject of visceral syphilis which engaged the attention of the Society for three evenings, other matters of special importance have been brought before the meetings; and the volume of the 'Transactions' is enriched by the communications of Sir William Gull and Dr. Sutton on arterio-capillary fibrosis; of Dr. George Johnson on the changes in the blood-vessels in the small red granular kidney; by Mr. Godlee on the organisms characteristic of vaccinia; by Dr. Braidwood and Mr. Vacher on vaccinia and variola; by Dr. Klein on scarlatina and on pig typhoid; and by Dr. Gowers on hydrophobia. For these special communications the Council desire to express their thanks to the different authors.

A committee was appointed to inquire into "the infective processes known as pyæmia, septicæmia," and allied diseases, and included representatives from each of the large general hospitals of the Metropolis; and of these a working committee was selected, consisting of Mr. Marcus Beck, Dr. Greenfield, Mr. MacCarthy, and Dr. Ralfe. Application was made to the Local Government Board for assistance in an inquiry which might be so important to the welfare of the public. A grant of £350 was at once made, and the committee has since been actively engaged in pursuing its investigations.

A committee has also been formed to inquire into the structure of the arteries and capillaries in Bright's disease with contracted kidneys, and the Council feel that, as it is composed of Dr. Burdon Sanderson, Dr. Bristowe, Dr. Gowers, Dr. Charles, and Mr. Schäfer, the Society may look forward to a report of considerable value.

The Committee on Morbid Growths has revised its rules and regulations, and these have received the assent of the Council, and have been published in the volume of the 'Transactions' for 1877, for the information and guidance of members presenting specimens.

The expenses of the 'Transactions' have been unusually large, but the Council feel that the volume is exceptionally valuable from

the number and character of the engravings, no less than for the importance of the communications which they accompany. To the liberality of Sir William Gull and Dr. Sutton the Society is indebted for the greater part of the illustrations to their paper, and the Council desire to offer them their warmest thanks for thus adding to the value of this, the 28th volume of the 'Transactions.'

They feel assured that the Society will endorse their acknowledgment of the services of Mr. Wheatley, whose labours have greatly increased with the growth of the Society and the increased attendances at the ordinary meetings.

The Treasurer's Balance Sheet for the financial year 1876-7 is appended, and from this it appears that the total amount invested in the names of the Trustees remains £1067 15*s*. 1*d*., and the balance now in hand is £12 15*s*. The total receipts for the year amounted to £669 16*s*. 10*d*., which, with the balance of £30 8*s*. 2*d*. remaining over from last year, makes the sum total of £700 5*s*. This includes £154 5*s*. 11*d*., the contribution of Sir William Gull and Dr. Sutton, towards the expenses of the illustrations. The total amount expended is £688 11*s*., and of this £521 14*s*. 2*d*. represents the cost of the volume of the 'Transactions.'

CHARLES MURCHISON.

THE PATHOLOGICAL SOCIETY

Dr. *In Account with the Treasurer*, JOHN W. HULKE, Esq. **Cr.**

To *Meetings:* 1877.	£	s.	d.	£	s.	d.
Payment to Royal Medical and Chirurgical Society for use of Rooms, &c....	63	0	0			
Refreshments, Waiters, and Management of Meetings.....	31	10	0			
Hire of Microscopes.....	9	16	6			
				104	6	6
Petty Cash: per Hon. Secretaries.....	4	19	9			
Per Mr. Wheatley, Postages, &c.....	7	7	4			
				12	7	1
Stationery: Wodderspoon's Account.....	8	11	9			
Odell and Ives (Receipt Books)	1	0	0			
				9	11	9
Assistance to Secretaries, Treasurer, &c.:						
Assistance to Secretaries (Mr. Wheatley)	7	7	0			
Collection of Subscriptions	14	18	6			
Posting of Ledger (Mr. McDermot) ...	1	10	0			
Gratuity (Mr. Wheatley)	15	15	0			
				39	10	6
Transactions: Expenses of Vol. XXVIII (750 copies):						
Printing (Adlard).....	199	19	5			
Woodcuts (Butterworth and Heath)...	8	16	0			
Lithography (Mintern)	98	7	9			
Ditto (Smith)	14	10	0			
Ditto (Hanhart)	196	18	0			
Index (Wheatley).....	3	3	0			
				521	14	2
Balance at Bankers	11	14	0			
Ditto returned Draft (repaid)	1	1	0			
				12	15	0
				£700	5	0

1877	£	s.	d.	£	s.	d.
By Balance at Bankers', December, 1876				30	8	0
Subscriptions and other Fees:						
367 Annual Subscriptions for 1876-77...	385	7	0			
3 Arrears, 1868-70	3	3	0			
30 Admission Fees	31	10	0			
4 Fees, Non-Resident Members	8	8	0			
				428	8	0
Transactions:						
Sale of Volume XXVII, and previous volumes				56	18	9
Dividends:						
On £972 5*s.* 3*d.*, January, 1877 ...	14	8	1			
On £1067 15*s.* 1*d.*, July, 1877	15	16	3			
				30	4	4
Contributions by Sir Wm. Gull and Dr. Sutton in aid of Illustrations for Transactions				154	5	11
Total Funds invested in 3 per cent. Consols December, 1877	1067	15	1			
				£700	5	0
Balance in hand at Bankers'				£12	15	0

Audited and compared with the Vouchers and found correct, December 22nd, 1877.

Auditors. { J. S. BRISTOWE.
SEPTIMUS W. SIBLEY.

LIST OF SPECIMENS AND REPORTS

BROUGHT BEFORE THE SOCIETY DURING THE SESSION 1877-78.

I.—DISEASES, ETC., OF THE NERVOUS SYSTEM.

PAGE

1. Pachymeningitis hæmorrhagica in delirium tremens By W. S. Greenfield, M.D. 1
2. Miliary aneurysms on a branch of the anterior cerebral artery in a case of apoplexy By Thomas Barlow, M.D. 8
3. Report on a case of syphilitic tumour of anterior cerebral artery By W. S. Greenfield, M.D. 10
4. Multiple tumours of the brain; tuberculosis of lungs and kidneys; caseous degeneration of bronchial glands; obstruction of the pulmonary artery By J. Pearson Irvine, M.D. 11
5. The pathology of a case of paralysis agitans, or Parkinson's disease By T. S. Dowse, M.D. 17
6. Elongated cavity in the spinal cord (Syringomyelus) By Frederick Taylor, M.D. 21
7. A case of diabetes; morbid appearances met with in the brain, spinal cord, lungs, and elsewhere. By Alexander Silver, M.D., and J. Pearson Irvine, M.D. . 25

II.—DISEASES, ETC., OF THE ORGANS OF RESPIRATION.

1. Diphtheria associated with enteric fever By W. S. Greenfield, M.D. 29

PAGE

2. Millstone-makers' disease; siliceous matter found in the lung By T. B. Peacock, M.D. 31
3. Miliary tubercle of the lungs in an infant aged three months By Edwards Crisp, M.D. 34
4. Destructive pneumonia due to compression of bronchus by aneurysm of aorta By J. Pearson Irvine, M.D. 36
5. Case of aneurysm of a branch of the pulmonary artery; death from hæmorrhage By Samuel West, M.B. 41

III.—DISEASES, ETC., OF THE ORGANS OF CIRCULATION.

1. Malformation of the heart; large aperture in the septum of the auricles, with the foramen ovale closed By T. B. Peacock, M.D. 43
2. Defective muscular development of the cardiac ventricular septum; consequent septal aneurysm; displacement of an aortic valve by this aneurysm By J. Pearson Irvine, M.D. 47
3. Two cases of loose balls of fibrin in the left auricle, with mitral stenosis By J. Wickham Legg, M.D. 49
4. Large ante-mortem clot filling the left auricle, in a case of stenosis of the tricuspid and of the mitral valves Exhibited by Wm. Ewart, M.B. 52
5. Aneurysms of the left ventricle of the heart By J. Wickham Legg, M.D. 54
6. Aneurysm of the right auricle By J. Wickham Legg, M.D. 57
7. Mitral stenosis; thrombosis of left auricle; embolism of left inferior parietal lobule; thrombosis of femoral arteries; gangrene of lower extremities By W. Cayley, M.D. 60
8. A case of rupture of the aortic valves By J. Burney Yeo, M.D. 62

PAGE

9. Obliteration of the aorta; dissecting aneurysm; two semilunar aortic valves By J. Wickham Legg, M.D. 65
10. Case of aneurysm of the arch of the aorta which opened externally . . By Thos. B. Peacock, M.D. 68
11. Aneurysm of the aorta bursting into the pericardium; popliteal aneurysm cured four months previously By W. W. Wagstaffe 72
12. Old spinal disease, with amyloid viscera; distortion of the aorta from spinal curvature, with dilatation of the heart and ante-mortem coagula in the left ventricle By James F. Goodhart, M.D. 78
13. Aneurysm of abdominal aorta; rupture and formation of a traumatic aneurysm (left kidney and left renal vein compressed by the latter; albuminuria) By J. Pearson Irvine, M.D. 79
14. Aneurysm of the cœliac axis, caused by diffuse suppuration in the retro-peritoneal tissues, consequent on concretions in the kidney: pyæmic changes in the lungs and elsewhere . . By J. Pearson Irvine, M.D. 85
15. Cases of aneurysm of the cerebral and brachial arteries By W. S. Greenfield, M.D. 91
16. Thrombosis of the superior mesenteric artery, with plugging of the left femoral, external and common iliac arteries; gangrene of the leg; severe ulceration of the intestines By H. G. Howse, M.S. 101
17. Aneurysm of the anterior communicating cerebral artery By J. Wickham Legg, M.D. 106
18. A case of thrombosis of the vena portæ, leading to cirrhosis of the liver, after thrombosis of the vena cava: with secondary acute nephritis and acute abscess in the right lumbar region By Samuel West, M.B. 107

IV. DISEASES, ETC., OF THE ORGANS OF DIGESTION.

(A) DIGESTIVE CANAL.

PAGE

1. Spontaneous rupture of the œsophagus By WILLIAM ADAMS. 113
Report. By W. CAYLEY, M.D., and W. S. GREENFIELD, M.D. 114
2. Imperforate anus By EDWARDS CRISP, M.D. 115
3. Congenital occlusion of small intestine By N. DAVIES-COLLEY 115
4. Ulceration of the bowel as a consequence of renal disease By W. HOWSHIP DICKINSON, M.D. 117
5. Case of acute intestinal obstruction; perforation of a diverticulum By ALBAN DORAN 122
6. Two specimens of epithelial cancer of the rectum By W. H. CRIPPS 123
7. True diaphragmatic hernia By GEORGE GARLICK, M.D. 125

(B) DISEASES OF THE LIVER.

8. Aneurysm of hepatic artery in the cavity of an abscess of the liver; perforation of the stomach and rupture of aneurysm into it By J. PEARSON IRVINE, M.D. 128
9. Small aneurysm of the coronary artery in an ulcer of the lower curvature of the stomach By R. DOUGLAS POWELL, M.D. 133
10. Softening of syphiloma of liver By SAMUEL WILKS, M.D. 135
11. Case of congenital malformation of the ductus communis choledochus By JOHN H. MORGAN 137
12. Ulcerative escape of biliary calculi from the gall bladder into the duodenum By ARTHUR E. BARKER 142
13. Peritoneal cysts, with blood cyst of left ovary By J. KNOWSLEY THORNTON, M.B., C.M. 145

V. DISEASES, ETC., OF THE GENITO-URINARY ORGANS.

(A) KIDNEYS, BLADDER, &C.

1. Case of so-called phosphatic diabetes By CHARLES HENRY RALFE, M.D. 151

PAGE

2. Conclusion of a case of cystine calculi
By CHRISTOPHER HEATH 154
3. Indigo calculus from the kidney
By WILLIAM M. ORD, M.D. Lond. 155
4. Calculus containing carbonate and phosphate of lime
By W. M. ORD, M.D. Lond. 160
5. Spontaneous disruption of calculi within the bladder
By W. M. ORD, M.D. Lond. 161

(B) MALE GENITAL ORGANS.

6. Large single cyst of the testicle By ALBAN DORAN 163
7. Cases of prostatic tumours removed in the operation of lithotomy, followed by recovery
Communicated by THOMAS BRYANT 164

(C) FEMALE GENITAL ORGANS.

8. Solid tumour of left ovary and slightly enlarged right ovary
Exhibited by J. KNOWSLEY THORNTON, for HENRY TAYLOR, Guildford 168
9. Cysts in connection with the ovaries occurring in twin infants By ARTHUR LEARED, M.D., F.R.C.P. 171

VI. DISEASES, ETC., OF THE OSSEOUS SYSTEM.

1. Hyperostosis of the lower jaw, right parietal bone, left clavicle, and tibiæ; cancer of the lung
By W. CAYLEY, M.D. 172
2. Two cases of hyperostosis and tumour of the bones
By JAMES F. GOODHART, M.D. 175
3. Hyperostosis of the tibia By T. W. NUNN 181
4. Hyperostosis of the tibia, associated with curvature of the shaft (osteitis deformans) and the development of a spindle-celled sarcoma in the upper epiphysis
By H. G. HOWSE, M.S. 182
5. General hyperostosis with osteo-arthritis in a living subject By H. G. HOWSE, M.S. 184

PAGE

6. Case of impacted fracture of the shaft of the femur
By THOMAS BRYANT 190

7. Very extensive caries of spine leading to fatal pleurisy
By ARTHUR E. BARKER 191

VII. MORBID GROWTHS.

1. Congenital dermoid cysts occurring in the branchial, and other clefts By W. W. WAGSTAFFE 194

2. Specimen of cystic tumour of the thyroid gland successfully removed from the living subject
By JOHN WOOD, at King's College Hospital 206

3. A case of multiple round-celled sarcoma in a boy
By HENRY T. BUTLIN 211

4. Spindle-celled sarcoma in the muscles of the calf, from a child aged five months
By W. J. WALSHAM, for Dr. LEWIS W. MARSHALL 215

5. A specimen of colloid cancer of the breast
By W. SPENCER WATSON 218

6. Colloid cancer of rectum, anus, and buttocks
By R. W. LYELL 220

7. A case of fleshy polypus (round-celled sarcoma) involving the antrum, orbit, and nostril
By W. SPENCER WATSON 223

8. Melanotic sarcoma of the eyeball; secondary growths in the organs of the chest and belly, particularly in the liver By J. WICKHAM LEGG, M.D. 225

9. A case of carcinoma of the orbit recurring fourteen years after its second removal By E. NETTLESHIP 230

10. Sequel to a case of sarcoma of the anterior part of the sclerotic; death from recurrent tumours nearly four years after excision of the eye By E. NETTLESHIP 234

11. Case of epithelioma of the lip in a woman. By GEORGE THIN, M.D. (Introduced by the President.) 236

12. Cancerous ulcer of forty-three years duration
By GEORGE THIN, M.D. 237

PAGE

13. Pathological histology of a case of rodent ulcer of the scalp By GEORGE THIN, M.D. 241
14. Primary cancer of the tonsil By LENNOX BROWNE 243
Report. By J. F. GOODHART and H. T. BUTLIN for *Committee on Morbid Growths* 247
15. Epithelioma of tongue invading the tonsil; living specimen By LENNOX BROWNE 248
Report. By J. F. GOODHART and H. T. BUTLIN for *Committee on Morbid Growths* 250
16. Epithelioma of pharynx invading the larynx; living specimen By LENNOX BROWNE 250
17. Encephaloid cancer of the larynx By LENNOX BROWNE 251

VIII. DISEASES OF THE SKIN.

1. Bromide of potassium eruption in an infant By H. RADCLIFFE CROCKER, M.D. 252
2. A case of "hypertrophic lupus," with an account of the histology of its various stages By A. SANGSTER, M.B. 254
3. The minute anatomy of dysidrosis. By TILBURY FOX, M.D., and H. RADCLIFFE CROCKER, M.D. . . . 264

IX. SPECIAL COMMUNICATIONS.

(A) ON DISEASES OF THE LYMPHATIC SYSTEM, INCLUDING LYMPHADENOMA AND LEUKÆMIA.

1. Lymphadenoma and leukæmia By SAMUEL WILKS, M.D. 269
2. Specimens illustrative of the pathology of lymphadenoma and leucocythæmia By W. S. GREENFIELD, M.D. 272
3. Observations on specimens illustrating lymphatic diseases By W. R. GOWERS, M.D. 304

PAGE

4. Splenic leukæmia with carcinoma
By T. WHIPHAM, M.B. 313
5. Cases illustrating diseases of the lymphatic system, and particularly lymphadenoma or leukæmia lymphatica, and leukæmia splenica
By JAMES F. GOODHART, M.D. 322
6. Two cases of Hodgkin's disease of the glands; leucocythæmia; lymphadenosis. By Surgeon-Major J. H. PORTER, of Netley
(Communicated by the Hon. Secretary) 335
7. Drawings of organs, with microscopical sections, from cases of Hodgkin's disease and allied conditions. By F. C. TURNER, M.D., for Dr. SUTTON (from the Pathological Department of the London Hospital) 342
8. Case of rapidly fatal lymphadenoma
By GEORGE GARLICK, M.D. 358
9. Lymphadenoma By C. MACNAMARA 360
10. Intestines and abdominal lymphatic glands from a case of lymphadenoma By SIDNEY COUPLAND, M.D. 363
11. Hyperplasia of axillary glands with leukæmia
By T. RIDGE JONES, M.D. 368
12. Two cases in which tubercle was associated with, or simulative of, lymphadenoma
By W. HOWSHIP DICKINSON, M.D. 373
13. Idiopathic anæmia By W. HOWSHIP DICKINSON, M.D., with observations by Sir W. GULL 379
14. Cancer in its relations to the lymphatic system
By GEORGE HOGGAN, M.B. 384
15. A case of chyluria By CHARLES HENRY RALFE, M.D. 388
16. Chylous urine By W. HOWSHIP DICKINSON, M.D. 391
17. A case of chylous urine, in which the fatty principles were in part crystallisable, and in which the presence of sugar was satisfactorily determined
By ALEXANDER MORISON, M.B. Edin. 394
18. Fat from a case of chyluria By WILLIAM M. ORD, M.D. 402
19. Elephantiasis of the clitoris By Dr. LONDON, of Carlsbad 404
20. Cases of filarious disease
By J. BANCROFT, M.D., Brisbane, Australia 407

PAGE

(B) ON SPLENIC FEVER.

21. Life-history of *Bacillus anthracis*
By J. COSSAR EWART, M.B. University College 420

(C) ON MEASLES.

22. Researches on measles (Morbilli). By P. M. BRAIDWOOD, M.D., and F. VACHER. (Introduced by the President) 421

(D) ON LACTIC FERMENTATION.

23. On the lactic fermentation, and its bearings on pathology
By JOSEPH LISTER, F.R.S. 425

REPORTS OF THE COMMITTEE ON MORBID GROWTHS.

PAGE

1. On Lennox Browne's case of primary cancer of the tonsil (Jas. F. Goodhart and H. T. Butlin) . . 247

2. On Lennox Browne's case of epithelioma of tongue invading the tonsil (Jas. F. Goodhart and H. T. Butlin) 250

LIST OF PLATES.

	PAGE
I. Figs. 1, 2. Syphilitic Tumour of the Anterior Cerebral Artery, p. 10. (W. S. GREENFIELD) . Figs. 3, 4. Elongated Cavity in Spinal Cord, p. 21. (F. TAYLOR)	10
II. French Millstone-makers' Disease, p. 31. (T. B. PEACOCK)	32
III. Congenital Defect in the Septum of the Auricles, p. 43. (T. B. PEACOCK) . . .	46
IV. Figs. 1, 2. Aneurysm of the Aorta bursting into Pericardium, p. 72. (W. W. WAGSTAFFE.) . Fig. 3. Popliteal Aneurysm, p. 72. (W. W. WAGSTAFFE	72
V. Fig. 1. Adenoid Tumour removed during Lithotomy; microscopical appearances, p. 164. (T. BRYANT) . . . . . Fig. 2. Congenital Occlusion of small Intestine, p. 116. (J. N. DAVIES-COLLEY) . . Figs. 3—6. Multiple Sarcoma, p. 211. (H. T. BUTLIN)	166
VI. Fig. A. Spindle-celled Sarcoma in the Muscles of the Calf, p. 215. (W. J. WALSHAM) . . Figs. 1—4. Recurring Carcinoma of the Orbit, p. 230. (E. NETTLESHIP) . . .	216
VII. Cancerous Ulcer of forty-three years' duration, p. 237. (GEORGE THIN)	238
VIII. Rash from Bromide of Potassium, p. 252. (RADCLIFFE CROCKER)	252
IX—X. Hypertrophic Lupus, from vertical section, p. 254. (A. SANGSTER) . . .	258-60

PLATES—*continued.*

PAGE

XI—XII. Minute Anatomy of Dysidrosis, p. 264. (TILBURY FOX) 266-68

XIII—XIV. Specimens of Lymphadenoma, p. 272. (W. S. GREENFIELD) 292-302

XV—XVI. Figs. 1—5. Sections from the Liver, Spleen, and Pancreas, Lung, &c., illustrative of Leukæmia, p. 313. (T. T. WHIPHAM) . . 316-18

XVII—XVIII. From Photographs of a Soldier with Lymphadenoma, p. 335. (J. H. PORTER) 336-338

XIX. Spleen, from a case of Hodgkin's Disease, p. 342. (H. G. SUTTON) 342

XIXA. Fig. 1. Hyperplasia of Lymphatic Glands with Leukæmia, p. 368. (RIDGE JONES) . . } 352
Fig. 2. Section from Lymphatic Gland, p. 351. (F. G. TURNER) . . . . }

XIXB. Section from a case of Lymphadenoma with Tubercle, p. 373. (W. H. DICKINSON) . . . 374

XX. Lactic Fermentation in its Relation to Pathology, p. 425. (JOS. LISTER) . . . 438

WOODCUTS.

PAGE

1. Miliary aneurysms on a branch of the anterior cerebral artery in a case of apoplexy (T. Barlow) . 8
2. Syringomyelus: elongated cavity in the spinal cord; diagram of the cord with sections at different levels (Fred. Taylor) 22
3. Aneurysm at division of basilar artery, seen from below, the sac resting upon the circle of Willis (W. S. Greenfield) 93
4. Case II. Small sacculated aneurysm, connected with branch of the left internal carotid. Case III. Aneurysm in superficial branch of middle cerebral artery. Case IV. Miliary aneurysm in corpora striata (W. S. Greenfield) . . . 94
5. Impacted fracture of the shaft of the femur (T. Bryant) 190
6. Congenital dermoid cysts in the branchial and other clefts: A.B. showing attachments of cyst to fronto- and to lachrymo-maxill. suture (W. W. Wagstaffe) 194
7. Sketch indicating lines showing the position of the branchial fissures (W. W. Wagstaffe) . . 200
8. Primary cancer of the tonsil (L. Browne) . . 244
9. Epithelioma of tongue invading the tonsil (L. Browne) . 248
10. Epithelioma of pharynx invading the larynx (L. Browne). 250

11–12. Encephaloid cancer of the larynx (L. Browne) . 251

13. Idiopathic anæmia; the spleen pulp containing very few red corpuscles (W. H. Dickinson) . . 382

WOODCUTS (*Continued*).

PAGE

14. Idiopathic anæmia; a drop of blood from the coronary vein of the heart showing excess of white corpuscles (W. H. Dickinson) . . . 383

15. Elephantiasis of the clitoris (Dr. London) . . 405

16. Elephantiasis of both hands and feet (Dr. London) . 406

17. Case of Filariæ in the blood: steatoma over malar bone (J. Bancroft) 412

18. Ditto: tumour under right pectoral muscle (J. Bancroft) 413

19. Filaria, under ¼-in. objective (J. Bancroft) . . 416

20–28. Apparatus for experiments on lactic fermentation (Jos. Lister) . . . 427–49

REPORT.

SESSION 1877-78.

I.—DISEASES, ETC., OF THE NERVOUS SYSTEM.

1. *Pachymeningitis hæmorrhagica in delirium tremens.*

By W. S. Greenfield, M.D.

These two specimens are intended to exemplify the occurrence of hæmorrhagic pachymeningitis in delirium tremens, and to raise the old question of the pathology of so-called hæmatoma of the dura mater.

The first specimen is one of hæmorrhagic pachymeningitis occurring in a man who died of delirium tremens with high temperature, and who had suffered from repeated attacks of delirium tremens.

Case 1.—*Repeated attacks of delirium tremens; fracture of leg; febrile delirium tremens, causing death; old hæmorrhagic pachymeningitis.*

George P—, æt. 39, the driver of a hearse, was admitted to St. Thomas's Hospital on February 19th, 1877, with a simple comminuted fracture of the leg, both bones being broken in the lower third. On the night of the 20th symptoms of delirium tremens set in, which became very pronounced on the 22nd. Chloral and bromide of potassium were given in large doses. On the 23rd the urine was found to be loaded with albumen; the temperature 101·9°; at 7 p.m. convulsions set in, and stertorous breathing; the convulsions continued till 9.45 p.m., when he died. The temperature was considerably elevated before death.

Examination seventeen hours after death.—Weather cold and damp.

Body that of a strongly-built male, with the general fattily-degenerated aspect of an old drinker. Body perceptibly warm to the hand. The fracture in lower third of right leg simple, but with much contusion and blood-staining around it, and some bullæ containing blood-stained fluid over the seat of fracture. No petechiæ on skin elsewhere than in the neighbourhood of the injury. *Subcutaneous tissue with a general excess of fat.

On opening the body the viscera were found to be distinctly warm and steaming, as if death had occurred within only a few hours (hotter, indeed, to the hand than those of another body examined six hours after death on the same day). The temperature was not taken. Blood generally fluid, and of very deep plum colour.

On opening the head the calvaria natural, not thickened, and quite free from any sign of old fracture; the dura mater readily separated. The small veins cut across exuded a general excess of blood.

The dura mater over the left hemisphere was observed to be of somewhat yellowish colour on the external surface, as from old blood-staining, but otherwise there was nothing specially abnormal. This yellowish colour extended from the extreme front nearly to the occipital region. The right half of the dura mater was thick and opaque, but free from discoloration. The longitudinal sinus contained a large quantity of blood and some coagula. The dura mater separated much more readily from the frontal bone and its orbital plate on the left than on the right side, and the bone there appeared of darker colour than on the right side. On cutting through the dura mater in front in the usual manner a quantity of dark fluid blood escaped from a cyst on the arachnoid surface formed apparently between the dura and a false membrane covering its under surface. No blood nor even any signs of blood-staining were seen within the arachnoid cavity or on the surface of the brain, nor could any trace of old hæmorrhage or injury be discovered in the brain itself or in the pia mater.

Brain weighed 3 lbs. 1 oz. Superficial veins full, but not overdistended. Convolutions of vertex much wasted, with consequent accumulation of subarachnoid fluid; on the left side the convolutions very obviously flattened as if from pressure, especially over the anterior half of the hemisphere. Arteries at base entirely free from atheroma. No sign of subarachnoid hæmorrhage anywhere. Lateral ventricles slightly dilated (but only in proportion to the general atrophy). Substance of brain generally firm, the cortical grey

matter everywhere obviously wasted. No excess of *puncta cruenta;* and brain in all other respects normal.

The dura mater when removed presented the following appearances. The whole of the inner surface of the membrane where it covered the convexity of the left hemisphere was of very deep red colour, with the exception of one or two patches near the centre, where it was yellowish white. The inner surface was generally smooth, but on close inspection numerous small radiating white cicatrices could be observed. There was no blood upon this surface. Between the inner membranous layer and the dura mater proper was a cyst containing blood, partly fluid, partly coagulated. The false membrane was firm and tough, measuring about one millimètre in thickness, or at some parts two, but not more; at its edges it adhered firmly to and was continuous with the dura mater, extending a short distance beyond the part containing the blood. On comparing the dura mater subjacent to the blood with the healthy dura it was evidently thickened by the presence of a thin adherent membranous layer between it and the layer of blood, the cyst being thus complete. (The specimen is preserved in the museum of St. Thomas's Hospital.)

On microscopic examination the structure appears as follows:—The vessels of the dura proper are larger than natural and full of blood. Adherent to the fibrous layers and continuous with them is an extremely vascular layer, forming almost a cavernous structure with large communicating blood spaces. This layer consists of imperfectly-formed fibrous tissue, a large part being in an embryonic state, and this is especially the case around the vessels, the walls of some of which appear to be composed of masses of rounded or ovoid cells. A somewhat more fibrillated layer separates this structure from the contained blood clot. The inner layer of the false membrane, forming the part of the cyst wall nearest the brain, has a similar structure to that on the outer surface; but the vessels, though numerous, have a less cavernous arrangement. Towards the cerebral arachnoid there is a distinct endothelial lining, a delicate basement membrane formed of parallel fibrils, and covered by a single or double layer of endothelial cells. There is no hæmatoidin to be discovered near the surface.

A quantity of semicoagulated blood was found in the lower part of the spinal canal, a layer $\frac{1}{12}$th inch in thickness covering the posterior surface both in the dorsal and lumbar regions. No blood

whatever inside the sheath itself. Spinal cord not obviously diseased to naked eye. The condition was probably due to meningeal hæmorrhage occurring just before death; the blood accumulating in the direction of least resistance.

Larynx and *trachea* normal; lungs weigh 22 oz. each; are both ill-expanded and of dark colour; bronchi filled with very slightly frothy bloody fluid of deep purplish-crimson colour, and on squeezing the lung a large quantity flowed out, mixed with some air. On section, the lung tissue throughout was found to be similarly gorged with blood, almost black in some parts, but except in the upper part of right lower lobe, the condition did not resemble ordinary pulmonary apoplexy, but rather general transudation. Numerous petechiæ in subpleural tissue, especially over lower lobes.

Heart 14 oz.; cavities large, distended with dark fluid purple blood. Ventricles uncontracted. Muscular tissue friable, very flabby, soft and greasy. Valves normal. Aorta slightly atheromatous. Liver fatty. Spleen swollen, greasy. Cortex of kidneys swollen. Chronic catarrhal condition of stomach.

CASE 2.—*Fracture of skull. Contusion of brain, hæmorrhage into arachnoid cavity; organization of the clot, with adhesion to the dura mater at the end of three weeks.*

Eliz. J. —, æt. 52, a housekeeper, known to be addicted to drinking (she is called an "habitual drunkard" in the notes), was admitted to St. Thomas's Hospital on Aug. 7th, 1877, under the care of Mr. Mac Cormac, having fallen six feet down some area steps, and received a severe scalp-wound over the occipital region. The wound was dressed with terebine and oiled lint. On the 9th it was noted by the surgical registrar, Mr. Newby, that she was deaf, but also evidently stupid, for when asked any question she rambled about nothing in particular. On the 10th she was in much the same condition, apparently bordering on delirium tremens, watching the opportunity to get out of bed, calling for drink. Pulse 84, very irregular at times, at others very slow. She continued in the same drowsy, rambling condition, becoming, however, less conscious; on the 27th she passed everything under her. On the 31st it was noted that she had been completely insensible for forty eight hours, with heavy noisy respiration, and had become of dusky hue.

She died on Aug. 31st at 5 p.m. Temperatures: Aug. 10th, M., 99·8°; E., 100·4°. 11th, M., 98·2°; E., 98·4°. 12th, M., 98·6°; E., 101.° 13th, M., 98°; E., 100°.

Examination thirty-two and a half hours after death.—Head opened first; dura mater generally reddened, much more so than natural, somewhat opaque and thick. Over the left hemisphere the dura mater appeared externally of somewhat darker colour than over the right, but there was no hæmorrhage on the external surface. The skull was found to be fractured in a nearly horizontal line, commencing just in front of the level of the anterior extremity of the left petrous portion, thence passing backwards with a slight upward inclination to within an inch of the middle line behind, then turning upwards for half an inch. It was a mere fissure through both tables of the skull.

On cutting through the dura mater it was seen that all over the left hemisphere and in the right posterior fossa there were larger or smaller spots of partly organized blood-clot adherent to the inner surface of the dura mater. These were in the form of small spots the size of a split pea, or patches about the size of a sixpence, which were partly coalescent so as to form continuous layers in some places. In part they were deep red, but towards the centre rust coloured, and surrounded by a dark nearly black zone. They adhered intimately to the dura mater, as if incorporated with it. *None of them were found on any part of the visceral arachnoid*, nor was there any sign of blood staining on any part of it. At the tip of the left temporo-sphenoidal lobe the brain was adherent to the dura mater and superficially softened; on the right side in the corresponding situation there were also signs of very slight injury. Nowhere else was there the slightest adhesion, or thickening of the visceral arachnoid, nor any sign of injury to the brain. There was some general wasting of the cerebral convolutions and excess of subarachnoid, and to a slight degree of ventricular fluid. The brain weighed 46 ounces, it was firm, the grey matter well defined, but its substance appeared healthy. Vessels free from atheroma.

With the exception of slight fibroid phthisis, œdema of the lungs and an early condition of granular kidney, there was nothing specially to be mentioned in the state of the other organs.

Remarks.—In the specimen from this latter case we see then a condition which, though less advanced, appears to be precisely the same as in the other. There was contusion of the hemisphere at the tip of the temporo-sphenoidal lobe, blood was effused into the arachnoid cavity, and was, in the course of about three weeks, taken up, as it were, by the dura mater and became partially organized. None

of the blood whatever adhered to the visceral layer of the arachnoid.

The facts here brought forward, and the inferences suggested, have no claim to novelty; but they are less generally recognised than they might be, and there have been no cases of the kind brought before the Society of late years.

The occurrence of pachymeningitis hæmorrhagica in delirium tremens is a fact now established beyond question.[1] But it is less certain at what period it occurs, and the same holds good with regard to its occurrence in some forms of insanity. The point upon which most discussion has arisen is as to the immediate cause of the pachymeningitis. It is well known that this was for a long period a debated subject, some maintaining that a thickening of the membranes occurred, and that hæmorrhage took place between its layers, the blood then organized, and produced further thickening; or it might accumulate and form a blood cyst between layers of the membrane. The true origin was first described by Mr. Prescott Hewett. It would be out of place here to state the various authors who have expressed an opinion upon this subject. It is well discussed by Drs. Wilks and Moxon ('Path. Anat.,' 2nd edition), who are in favour of the view that the membranes arise from hæmorrhages into the arachnoid cavity. Laborde[2] punctured the superior longitudinal sinus in young dogs, and produced extravasation of blood in the arachnoid cavity, which were found to be surrounded by a false membrane on the tenth day. Sperling[3] injected fresh blood into the arachnoid of rabbits, and eight days later found that false membranes were forming; in two or three weeks they were found to be quite organized. One of the most elaborate investigations into the pathology and clinical history of pachymeningitis hæmorrhagica is by Kremiansky[4] of St. Petersburg. He found that it occurred in a number of fatal cases of typhus fever.

By giving large doses of alcohol to dogs for four weeks he suc-

[1] See Magnan 'On Alcoholism.'

[2] 'Sur la Pathogenie des Hæmorrhagies Meningées intra-arachnoidiennes' (Soc. Anatomique de Paris, 1864).

[3] "Centralblatt," 1871. Analysed in 'Gazette Hebdomadaire,' Jan. 12th, 1872.

[4] "Pachymeningitis hæmorrhagica interna." 'Virchow's Archiv,' xlii, 1868, p. 129.

ceeded in producing pachymeningitis. Neumann also found that it occurred in alcoholism.

An important point in reference to Kremiansky's observations is that the condition of the blood in delirium tremens, and especially in the febrile cases, as also the condition of the spleen and other organs, closely resemble that seen in typhus fever. The hypothesis of injury has usually been accepted; but it would seem that there is a peculiar tendency to meningeal hæmorrhage in this state of the blood. In Case 1 there was spinal hæmorrhage, with no injury to account for it.

When once the false membrane adherent to the dura has been formed, we can see, by reference to the microscopic examination, how readily fresh hæmorrhage may occur into the cyst, and how it is that it does not occur on the free surface. The blood-vessels, large and thin walled, their walls in the main composed of embryonic tissue, which lie on the inner surface of the layer nearest the dura mater, would be the most readily ruptured and give rise to fresh hæmorrhage.

The points which I desire to bring out in this communication are:—

1. That hæmorrhagic pachymeningitis occurs in delirium tremens.

2. That hæmorrhagic pachymeningitis is due to intra-arachnoid hæmorrhage from some cause.

3. That the results of traumatic intra-arachnoid hæmorrhage are identical in character with those of the spontaneous form.

4. That the reaction of the two layers of the arachnoid, in respect to blood effused into the cavity, proves that the two layers of this membrane are essentially distinct, structurally and functionally, in fact are but accidental and unimportant parts of the dura and pia mater respectively, and should be regarded as such. In some cases these cysts have been found to adhere to the pia mater, but this is very probably due to a secondary process associated with pressure.

For other points bearing on this subject I may refer to the following list of authors:

Baillarger, 'Du Siège de quelques Hæmorrhagies Meningées,' 1837.
Prescott Hewett, 'Path. Trans.,' vol. vi, p. 10.
Vulpian et Philippeau, Soc. de Biologie, April 6th, 1872.
Virchow, 'Tumeurs.' French Trans., vol. i, p. 138.

2. *Miliary aneurysms on a branch of the anterior cerebral artery in a case of apoplexy.*

By Thomas Barlow, M.D.

This specimen is one of the miliary cerebral aneurysms described by Charcot and Bouchard. It was taken from the brain of a man æt. 52, who had been a heavy drinker, and who was admitted into Charing Cross Hospital on account of dyspeptic symptoms.

These symptoms (pain in left hypochondrium, vomiting and wasting) probably depended on a small scirrhous infiltration at the cardiac end of the stomach which was found *post mortem*. The only nervous signs presented by the patient were a slight thickness of articulation, slight flattening of the left side of the face, and slight collapse of the left side of the nostril.

These signs were thought to be the vestiges of a former hemiplegia; but the man could give no account of any paralytic attack; his dyspeptic symptoms were dominant. On the third day after admission, without any warning, the patient had a bilateral general convulsion, which was slightly more pronounced on the left side, and which lasted ten minutes.

After this he became comatose, his temperature rose to 100°, and he died within twenty-four hours.

Woodcut 1.

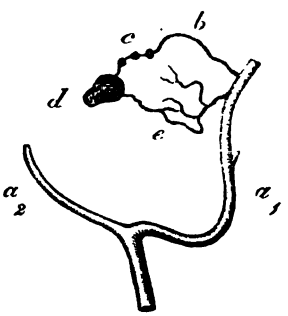

The two anterior cerebral arteries united into a single trunk, which divided into a_1 and a_2. From *a*, which corresponds with the right anterior cerebral, a small branch, *b*, is given off. This had three minute dilatations, *c*, and then formed the aneurysm, *d*, into which also another small vessel, *e*, entered.

At the *post mortem*, besides the scirrhus of the stomach, there were found granular cystic kidneys and hypertrophy of the left ventricle. Along the outer border of the right optic thalamus there was an old, firm, narrow, plâque jaune. There were no recent changes near it and the cortex was natural. In the substance of the anterior lobe, viz. at the root of the right superior frontal convolution, there was a cerebral hæmorrhage about the size of a hazel nut. In the centre of this was a small ruptured aneurysm the size of a hemp seed. It was composed of two parts—viz., a hard spherical nucleus and an outer shaggy portion.

It was situated on a minute vessel about half an inch long—a branch of the right anterior cerebral (Woodcut 1, *d*). On the proximal side of the aneurysm, quite close to it, were found, subsequently, three minute dilatations (*c*), each bigger than a pin's head, which must also be regarded as aneurysmal. Another small dilatation was found on a minute vessel in the neighbourhood. From the aneurysm before described another minute vessel also derived from the anterior cerebral was traced. No old softening was present in this region.

All the vessels of the circle of Willis, except the anterior cerebrals, were extensively atheromatous. Although atheroma was present no actual roughness of the inner surface of the vessels was made out, and there was no valvular disease whence emboli could have been swept. It seems to me probable that the aneurysmal condition arose from primary disease of the arterioles; at all events there is no evidence of its being set up by embolism.

The lesson of this case seems to be that given cerebral apoplexy, granular kidney, and hypertrophied left ventricle, we are bound to investigate the local condition of the small vessels in the neighbourhood of the apoplexy before taking refuge in the convenient and often invoked hypothesis of increased arterial tension.

Note.—Subsequent microscopic examination showed in sections of the aneurysm itself different layers of thrombus. Sections of the anterior cerebral showed no morbid changes, whilst the walls of the arterioles were decidedly thickened. *Oct.* 16*th*, 1877.

3. *Report on a case of syphilitic tumour of anterior cerebral artery.*

By W. S. Greenfield, M.D.

In October, 1875, I brought before the Society a specimen of a tumour on the left anterior cerebral artery, which I believed to be of syphilitic nature (see vol. xxvii of the 'Transactions,' p. 5). At that time the tumour could not be examined microscopically, owing to the lack of specimens of syphilitic disease of arteries in the museum of St. Thomas' Hospital. But an opportunity having occurred for examining it, I now report the results.

The tumour was about the size of a pea, situated upon the vessel just behind the anterior communicating artery, which it appeared partly to surround; but projecting chiefly upwards and forwards. Sections were made parallel to, but not through the vessel. On examination with a low power the tumour appeared to consist of an external fibrous capsule, somewhat thin, surrounding the mass of the tumour, which was composed of two distinct zones; an inner part nearly amorphous and resembling caseous substance; an outer having a distinct cellular structure. Between these two layers a somewhat more fibrous zone appeared, containing a considerable number of more or less completely obliterated vessels. (See Plate I, fig. 1.) The outer layer also contained a considerable number of vessels. Examination with a higher power showed the outer part to consist of a structure in the main composed of small roundish cells, imbedded in an intermediate substance which in many parts formed a distinct stroma; it was somewhat rich in vessels, and resembled, in every respect, the earlier stages of a syphilitic gumma (fig. 2). In the interior part the structure could hardly be made out; it consisted of granular débris and more or less distorted cells, with traces here and there of vessels.

The intermediate zone presented the most marked and distinctive features, owing to the presence of a considerable number of vessels with much thickened walls, many of them more or less obliterated. The several stages of obliteration or obstruction could be well traced, and were due to a concentric cell growth around the interior of the vessel gradually encroaching upon, and closing the channel. It appeared to proceed in some cases from the endothelial or sub-endo-

DESCRIPTION OF PLATE I.

Figs. 1 and 2 illustrate Dr. Greenfield's report on a case of Syphilitic Tumour of the Anterior Cerebral Artery. (Page 10.) From drawings by himself.

FIG. 1 shows under a low power (1½ inch) the arrangement of growth around the small vessels, most of which are obstructed.

FIG. 2 shows the general appearance in complete stage before degeneration has set in. ($\frac{4}{10}$th obj.)

Figs. 3 and 4 (with woodcut 2, page 23) illustrate Dr. Taylor's specimen of Elongated Cavity in the Spinal Cord. (Page 21.) From drawings by himself.

FIG. 3. A transverse section from the lower dorsal region, magnified 10 diameters. It shows the irregular quadrangular cavity occupying the right posterior cornu and column. The central canal is of rather large size, but quite separate from the cavity. The posterior vesicular columns are normal in size and structure. The fibrous tissue bordering the cavity is seen especially at the inner and posterior margins.

FIG. 4. Portion of the wall of the cavity taken from *c* in fig. 3, magnified 300 diameters. It shows a structure consisting of very fine fibres and nuclei, with tortuous vessels running parallel to the surface. There is no epithelium.

Fig 1



Fig. 2.

Fig. 3

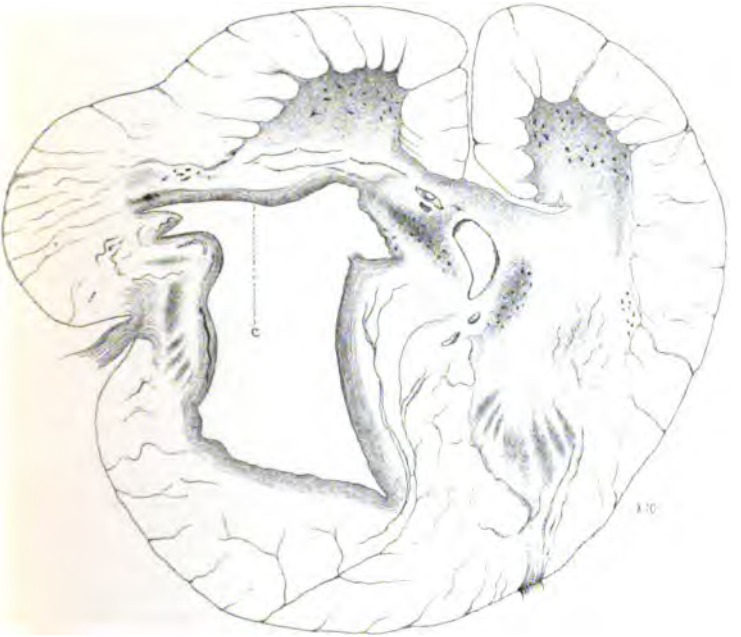

Fig 4



thelial cells; but in many of the cells, apparently of new formation, there was no differentiation of the coats (which were merely embryonic tissue as in granulation tissue or sarcoma), and all that could be seen was a growth of this inwards, so as to occlude the vessel.

The interest of this specimen lies not merely in the relation to the cerebral artery; but in the illustration which it affords of the mode in which the caseation of syphilitic growths appears to be produced, viz., by the rapid obliteration of vessels at the margin of the growth by a cell-growth in their interior, and consequent loss of nutrition. In a previous communication[1] I drew the attention of the Society to this point in the history of syphilitic gummata, and the specimen now shown is one of the best examples I have seen, the change being in active progress.

November 20th, 1877.

---

4. *Multiple tumours of the brain; tuberculosis of lungs and kidneys; caseous degeneration of bronchial glands; obstruction of the pulmonary artery.*

By J. Pearson Irvine, M.D.

A boy, æt. 7 years, came under observation in Charing Cross Hospital on August 18th, 1877. He was one of a family of delicate children, and had himself never been strong. His father died of Bright's disease, and his mother was always ailing. In 1876 the patient had measles, but seemed to make a good recovery, and it was not till the middle of June, 1877, that he began with his present illness, the early symptoms being no more definite than those of a general sense of distress with, at times, pains in the head. The headache, however, shortly became more severe and persistent, and localised just below the left frontal eminence. Vomiting next set in: it came on most frequently after food, and ceased with the emptying of the stomach, but sometimes occurred apart altogether from food. The boy did not waste much; he was always restless

[1] 'Path. Trans.,' vol. xxviii, p. 279.

at nights, moaning and starting and complaining of his head, and later on of pain in one or other of the limbs. The appetite was bad, but there was no diarrhœa. These various symptoms went on for about six weeks, when the vomitings became less frequent, and the child seemed to be generally improved. A fortnight before admission his mother noticed that his right eye was turned inwards, and the patient complained of double vision.

The patient on admission was found to be a black-haired, sallow child of dreamy expression. His limbs were fairly nourished, and he could walk with precision, but in his walk had a slight lateral nodding of the head. There was no enlargement of external glands. The eyes were prominent and large; the right lid drooped a little; there was right internal strabismus; the pupils were dilated and equal, and the boy complained of pains in the left frontal region. A loud systolic murmur could be heard all over the cardiac region. The abdomen was natural; digestion and respiration almost those of health; and the urine, charged with phosphate, was free from albumen.

A few days after admission an ophthalmoscopic examination was made, and the note says:—"The discs have a blurred look, without any distinctness of outline; 'fluffy;' arteries disappear here and there; veins enlarged." The boy was quiet, did not speak unless spoken to, and did not mix with other children in the ward. On August 23rd, after breakfast, the right side of his face began to twitch; these twitchings, which drew the face to the right, gradually extended until the whole right half of the body became generally convulsed. The temperature rose to 102·5° Fahr. The spasms lasted five hours. The boy became cyanotic and his body was bathed in perspiration. There was complete loss of power on the right side afterwards, and the right half of the face flushed scarlet, the left remaining pale. Vomiting became again troublesome after food. Ten-grain doses of bromide of potassium were given, and on August 24th there was slight return of power in the affected hand and foot. The conjunctival capillaries (right) were much injected, and there was some photophobia. The boy was drowsy, but easily aroused into complete consciousness. Vomiting had ceased and iodid. potass. (gr. ii, t. d. s.) was ordered. On September 4th there had been no return of convulsions, and the face-changes were as before noted. He had no pain, no facial paralysis, no deviation of the tongue, and the paralysis of the right side could now be described as "slight weakness" with "slight" anæsthesia on

the same side. The pulse was regular and fairly strong; the cardiac murmur was loudest over the aortic cartilage, was inaudible at the angle of the scapulæ, but could be heard between the spines of the scapulæ, and was harsh in character. The eyes had undergone no change, but on September 15th the patient had general convulsions, and afterwards his vision generally failed, so that on October 14th he was quite blind. Soon after admission his speech, though distinct, became slow and hesitating, but he was never aphasic nor had any loss of memory. Early on while in hospital he was in the habit of "bolting" his food, but towards the end he took half an hour over an ordinary meal and complained of difficulty in swallowing. Beyond these things there was no marked change in his state up to his death, which occurred on November 15th, somewhat suddenly, about three weeks after his admission, and five from the beginning of noticeable symptoms.

He died in this way:—After being washed he appeared to be "different," but before the resident medical officer (Mr. Steedman) could be summoned he was dead. It should be added that he never exhibited any bending of the trunk to either side; did not assume one position in bed in preference to another, and never had diarrhœa or a trace of albumen in the urine. He had not at any time, soon or late, any cough. His chest was examined about the end of August, and the lungs were found then quite natural. His temperature during the first month in hospital was almost always normal (it rose with the first convulsion, but sank rapidly); for the next ten days it fluctuated from normal to between 99° and 100° Fahr.; then for a few days was normal morning and evening. From the beginning of October up to the time of death there was usually a nocturnal elevation (100–101° Fahr.); from October 17th to 22nd it rose gradually from 98° Fahr. to 103·4° Fahr., and thenceforward fluctuated between normal and 100·5° as before.

The autopsy was made about twenty hours after death. Rigor mortis was marked and the body emaciated, but not greatly. The right auricle was dilated and filled with dark clots; the tricuspid orifice natural; the right ventricle hypertrophied, the columnæ carneæ and the musculi papillares being well developed. The pulmonary orifice was distinctly contracted, each flap of the valve being thickened, and its edges tumid, opaque, and contracted. The foramen ovale was closed; the fossa very thin and unusually transparent; the left heart was quite healthy.

On the trachea beneath the thyroid body and extending below its lower border was a "tumour" as large as a walnut, which contained pus surrounding a caseous central mass. The bronchial glands were swollen, caseating or in earlier stages of this change. The upper lobes of both lungs were thickly sown with grey granulations in various stages; some being as small as a pin's head and translucent, others larger and grey or greyish yellow, others undergoing more advanced caseation. The upper lobes generally showed a bright scarlet injection, and there was an early pneumonia evident around the "tubercles," and pieces cut out partially sank in water. In the lower lobes were found scattered tubercles, surrounded by a deep injection, they being least numerous towards the bases. The abdominal viscera were healthy, except that both on the surface and on section of the kidney were found scattered grey tubercles. There were no caseous masses in them.

On removal of the skull cap, which was thin, the brain bulged. There were no adhesions, the convolutions on the upper surface, which was very pale, were much flattened, and at the base of the skull was found a serous effusion, as much as six or eight ounces .Near the posterior end of the falx cerebri, on its left aspect, was a rounded mass about the size of a large Barcelona nut, which fell off in the process of removing the brain. There were no tubercles at the base or such lymphoid exudations as are often met with in tubercular meningitis. In the cerebrum were numerous tumours like that on the falx, varying in size from a marble to a small walnut. Many of the tumours were distinctly connected with the pia mater, and had firm fibrous capsules, from which they could be easily enucleated. On section some showed signs of change; their centres were softened into greenish-yellow liquid matters, while more externally they were firm and of yellowish-grey colour. Many of them exhibited distinct concentric layers, especially those which were the least changed. One tumour, the side of a walnut, was found on the velum interpositum, near the front of the roof of the third ventricle; others lay deep in the centre of the brain, encroaching on the brain tissue by displacement only.

Tumours were also found in the right half of the cerebellum, and they encroached more than the others, though equally enucleable, out of a distinctly bounding capsule; one sprang from the pia mater on the under surface of the left cerebellum, and did not invade the brain tissue at all. It was a loosely hanging body, the

size of a large hazel nut, springing from the pia mater, but encapsulated like the other tumours. In the right cerebellum the tumours were three in number and these (each the size of a small walnut) were distinct and separable, each having its own bounding capsule. They all, too, touched the surface, and one encroached towards the base of the cerebellum, another towards the median fissure. These tumours showed particularly the concentric layers to which I have alluded, and had undergone little secondary change. In the right lateral ventricle were found two loosely-lying tumours, the size of small marbles, near its anterior extremity; in the left three similar masses near its posterior end, all distinctly connected with pia mater. The ventricles contained about two ounces of serum, and the optic thalami and corpora striata were flattened.

It is worthy of note, in regard to the pain complained of in the left frontal region, that a tumour was found, in no respects differing from the rest in the second left frontal convolution, and another in the anterior median fissure. Both were connected with the pia mater. Many of the tumours in the cerebrum readily slipped from their places during the examination, the brain having undergone rapid *post-mortem* softening. There was nowhere a trace of meningitis.

On microscopic examination the tumours exhibited the characteristics of "tubercular" tumours of the brain. They were made up of a small cell growth, which had degenerated more or less and become granular towards the centres of the masses. The vessels were enlarged, and for the most part blocked by fibrinous coagula, they being surrounded by closely-packed cells of the kind abovementioned. Cornil and Ranvier state that tubercular tumours of the brain are not enucleable, and rely on this fact as bearing on their pathological diagnosis. Niemeyer states that they are often enucleable, and adds that enucleability is due to stoppage of their growth. Most of the tumours sprang directly from the pia mater, and in all respects, except size, resembled the growths of tubercular meningitis. The smaller growths, those not larger than marbles, were rounded and smooth on the surface, especially those lying loosely attached in the lateral ventricles. The larger, which were evidently older, had undergone more secondary central change, and were uneven on the surface as if from partial contractions. All these gave one the idea that they had ceased to grow. In the lungs and kidneys the grey granulations were typical: in the former

the pneumonia which surrounded the granulations was quite recent, and could not indeed have existed longer than a few days.

I venture to ask whether it is not likely that the boy after his attack of measles, far from really gaining true health, experienced insidiously, as happens in children of all classes unless the cases are under constant observation, vast changes in the bronchial glands? The case is one of interest as regards the question of the sequelæ of caseous degeneration, especially of the bronchial glands. There is no doubt that here the evidence of disease in them was older than that of disease in the brain or elsewhere. Possibly the order of events was caseation of bronchial glands, tubercular tumours in the brain, tubercular disease of the lungs and kidney, and, secondary to the lung disease, a catarrhal pneumonia. It is clear, at any rate, that the lung mischief was entirely secondary as regards time to that in the bronchial glands and that within the skull.

The systolic murmur heard in this case must have been due to pulmonary obstruction, though it had not the distribution of pulmonary murmurs, and was loudest over the aortic cartilage. It could be heard between the spines of the scapulæ, but the pulmonary orifice only was found narrowed, this narrowing being in all likelihood congenital.

In spite of the number of the tumours found in the brain, the symptoms were scarcely so severe as those met with in many cases where there is but a single growth. Unilateral convulsions occurred; then general convulsions: the boy had double vision, his optic discs showed changes and towards the end he became blind: for a time he had right hemiplegia without aphasia, and slight right anæsthesia, and from these he partially recovered. He had distinct signs of partial paralysis of the sixth and third nerves on the right side, and towards the last some of the eighth pair of nerves suffered, as was shown by his dysphagia and slowness in speech as well as in swallowing. He had also, early on, pain in this limb or that, though he was never ataxic, and from the first had a lateral nodding of the head while walking. It is not so easy as one would wish to explain these symptoms, for many of the tumours in spite of all care slipped from their places in the diffluent brain during its examination. However, the paralysis of the nerves of muscles of the eyeball explain the double vision, and the changes in the optic discs are equally well explained by the effusions at the base and into the ventricles, and by the pressure of the tumour

over the velum interpositum on the optic chiasm. In the absence of the latter the impediment placed on the circulation from the retina by the effusions would explain the gradual loss of vision, in part at any rate. Many of the symptoms which came on late must be ascribed to the growths in the cerebellum, especially the right unilateral convulsions and right hemiplegia, on the side in which tumours were found. These tumours, which showed least secondary change, and which, though large, were probably of more recent growth than many smaller ones in the cerebrum, must, *bound down by the tentorium*, have caused great pressure, and not only have excited convulsions, but have so compressed the eighth pair of nerves as to have given rise to the dysphagic symptoms which the child showed towards the end of the disease. In two other cases, where a somewhat similar group of symptoms existed, it was possible to diagnose the situation of the tumour—one a case of syphiloma, the other of tubercular disease. To the pressure on the eighth pair of nerves was due also probably the slowness in speech. It is worthy of note that the intellect was not interfered with, and that the cerebrum was really little compressed or changed by the many tumours found in it. *December 4th*, 1877.

---

5. *The pathology of a case of paralysis agitans, or Parkinson's disease.*

By T. S. Dowse, M.D.

Catherine Dage, 52, was admitted into the Central London Sick Asylum at Highgate on the 29th of September, 1871, and died on the 28th of February, 1876. I give the clinical details of this case somewhat minutely, for the reason that even at the present time there exists a difference of opinion as to what are the especial signs particularly characteristic of this disease. There does not appear to have been any marked causation in this case. She said that her health was good until she was forty-three years of age, when she became weak and suffered from lowness of spirits. Her head first began to shake, then the right arm, then the left arm, and finally

the legs. When she first came under my care the tremor of the limbs had been increasing for nine years, excepting when she was asleep. It was of that rhythmical kind so peculiar to this disease, and distinct from other forms of tremor, which are so much influenced by position, by rest, and volition, notably the tremor of disseminated sclerosis. She could stand erect and preserve equilibrium, but the power of progression was lost; she could not even be impelled forward in the manner which is common in these cases, but she would go backwards with an increasing speed until she fell heavily upon the floor, having no power whatever to stop herself. The body was more or less rigid and slightly inclined forwards; the neck was so stiff that the head looked as though it were fixed in a vice. The features were without expression, and the way the eyes were turned outwards to follow an object whilst the head remained fixed, with the complete absence of nystagmus, was an especially pathognomonic sign. When she closed her eyes it was with some difficulty that she raised the lids, and these then became tremulous. There was no real difficulty of speech or dribbling of saliva. Both mastication and deglutition were performed slowly, but without impediment. All the special senses were good, with the exception that at times she suffered from colour blindness; everything then appeared to have a blue tint. The sense of taste was impaired; food tasted like a compound of nasty medicines. The shoulders were somewhat raised, the upper extremities in a state of flexion, and the characteristic relationship of the thumb to the forefinger was well shown. The lower extremities were fairly movable and free from distortion. She complained of intense heat, so that in the coldest weather she was satisfied with merely a sheet to cover her, yet the temperature of the body was rarely above normal. At times she had severe aching pain in the occiput, extending down the spine. The bowels were obstinately confined, but the secretions were otherwise normal, as far as one could judge. Sensation and sensibility everywhere normal, as well as electro-muscular contractility. The faradaic current stimulated the muscles more readily than the induced continous current.

On May 11th, 1875, the following note was made:—"She is unable to stand or help herself in any way; the body is bent forward, and both arms and legs are flexed and almost devoid of voluntary power. The nurse rolls her about bodily, as though she were a living automaton, but the flexor muscles evidently are more under her

control than the extensors. For instance, she can flex the arms and legs slightly, but she has to ask the nurse to extend them for her. The flexor muscles of the calves of the legs stand out like iron bands. The intellect seems clear, but the memory is undoubtedly failing. In other respects her health is good; her appetite rarely fails. She gives the night nurse a great deal of trouble, for she is constantly calling out to have her position changed."

This was her condition until a few weeks previously to her death, when she became obtuse, and did not care for her food. The sphincters were incompetent, and bed sores formed about the sacrum. For three days previously to her death no tremors were noticeable.

At the *post-mortem examination*, made twenty-four hours after death, there was no cadaveric rigidity. When the thorax was opened the right lung was seen partially collapsed, and contained some hard, nodular, cheesy masses at the apex. The left lung was completely collapsed and laid flat to the inner and upper part of the cavity. The heart was fatty and the left ventricle considerably hypertrophied; the valves were healthy, the aorta atheromatous; the liver, spleen, and kidneys, had undergone no especial degenerative gross change. The skull and the membranes of the brain were pale but healthy. The brain weighed 53 ounces; the convolutions were of normal depth and development, and so was the grey matter. The arteries at the base were slightly atheromatous. The nerves were remarkably firm. Upon section the substance of the hemispheres was pale, tough, and glistening. The parts entering into the formation of the motor tract felt unusually hard. The spinal cord was equally as firm, and weighed ten drs. avoirdupois. There were no gross lesions visible to the naked eye in either the brain, medulla, or spinal cord, beyond what has been stated. The following are the microscopic appearances as found by Mr. Kesteven, to whom I am indebted for them:

"At the decussation of the anterior pyramids the following marked appearances were noted:—The nerve-cells have undergone atrophic granular pigmentary degeneration, and that form of degeneration called fuseous, in which the nucleus and nucleolus take the carmine staining brilliantly, but the rest of the cells remain of a granular yellow appearance. There is cortical sclerosis of the posterior and right lateral columns, and millary as well as colloid

degeneration. As we ascend in the examination of the medulla, we find the above morbid appearances still well marked. The nerve-cells of the olivary bodies are atrophied, and undergoing fuseous degeneration. A few of the cells in the nucleus of the ninth nerve appear to be hypertrophied (incipient pigmentary degeneration). In the nucleus of the eighth nerve the cells are deeply pigmented, and in many their processes have quite disappeared. The fibres of the roots of the auditory nerve are in some places almost destroyed by miliary degeneration. At one spot in the middle of the lower portion of the nucleus of the fifth nerve there is an aggregation of colloid bodies lying in cavities larger than themselves and apparently formed by them. The nerve-cells of the corpus dentatum and folia of the cerebellum abound in fuseous degeneration, and the white matter gives evidence of miliary changes. The corpora striata are honeycombed with miliary degeneration. In the thalami optici some miliary changes are met with, but these are slight when compared with those of the striate bodies. The miscroscopical appearances presented by the spinal cord show similar degeneration to those found in the brain and medulla. The cells in the anterior horns are particularly the seat of the various forms of fuseous degeneration. The vessels are in some places thickened, in others sacculated with well-marked perivascular spores."

From this account of the pathological appearances of the brain and spinal cord in this case of paralysis agitans it remains to be considered how far the agitating palsy was due, or whether it was in any way due to these degenerative changes. For my own part I am led to the belief that these changes have little or nothing to do with it, for the same conditions of brain and spinal cord have been noted where none of the signs of this disease have existed, and again agitating palsies, according to M. Charcot, have existed when upon *post-mortem* microscopical examination no lesion whatever could be detected. *Tuesday, November*, 1877.

6. *Elongated cavity in the spinal cord* (*Syringomyelus*).

By Frederick Taylor, M.D.

Florence B—, æt. 18 months, was admitted under my care into the Evelina Hospital, November 19th, 1877. The child had been well until the age of five months, when it was observed that it could not hold up its head, and from that time the head enlarged. A fortnight ago, on admission, the arms became completely paralysed.

The child presented the characteristic large head of chronic hydrocephalus: it measured round the forehead and back of the head, at the widest part, 20¾ inches; from ear to ear, over the vertex, 12¼ inches; from the base of the nose to the occipital protuberance, over the vertex, 14¾ inches. The anterior fontanelle and anterior sutures were widely open; the eyeballs prominent but without oscillation. The optic discs were white and the vessels about the usual size. Both arms were completely motionless and flaccid, but the legs were slightly though distinctly rigid.

It was proposed to puncture through the fontanelles and withdraw some of the fluid, but an eruption of measles showed itself on the 26th November, broncho-pneumonia followed, and of this the child died on December 5th.

Post-mortem.—There was recent pleurisy on both sides without effusion, and at both bases, but especially the right, there was lobular pneumonia. Before the calvarium was removed more than a pint and a half of clear fluid was obtained by a trocar and canula introduced through the anterior fontanelle. The ventricles of the brain were greatly distended by the fluid, the aqueductus Sylvii was dilated, and the fourth ventricle was large enough to have held a small walnut.

The membranes of the spinal cord were healthy. The cord itself measured, from the point at which it was separated from the medulla, 7 inches in length, ⅔ inch in its greatest breadth. The cervical and lumbar regions had their usual consistence, but the dorsal region was quite flaccid, and on making transverse sections it was seen that in this region the cord was hollowed by a considerable cavity. The largest cavity (for there were altogether three) was of irregular size and shape, and altogether extended from the lowest part of the cervical to the highest part of the lumbar region, and was 2½ inches

WOODCUT 2.

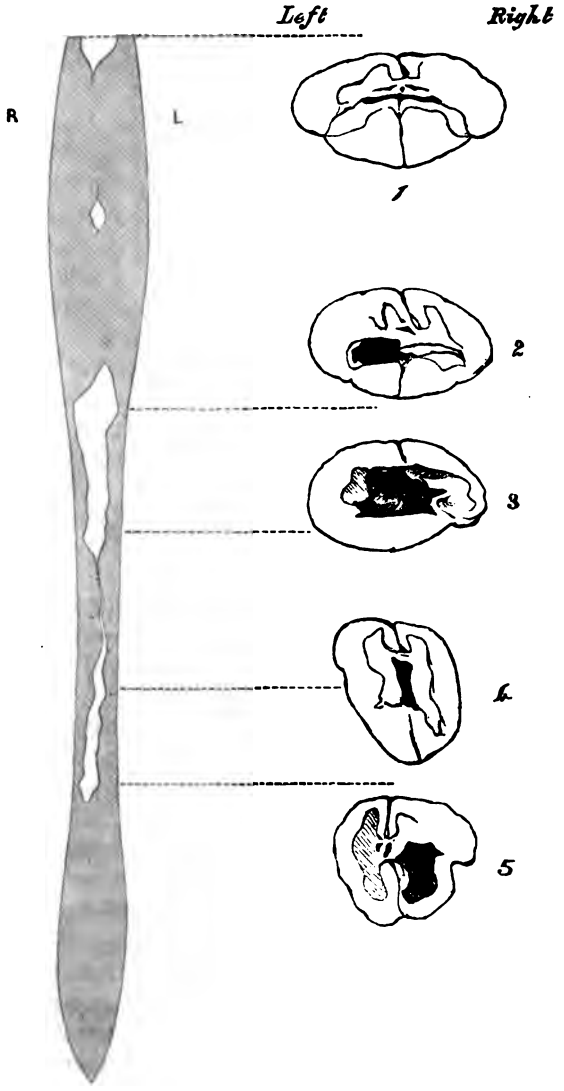

Syringomyelus. Diagram of spinal cord ($\frac{4}{5}$ths actual length), with sections at different levels; (1) at upper end of cervical enlargement; (2) at junction of cervical and dorsal portions; (3) at middle dorsal portion; (4) lower dorsal, and (5) lowest dorsal region.

in length. It invariably occupied either the posterior white columns, or the posterior cornua, or the posterior grey commissure, and never invaded the anterior or lateral columns or the anterior cornua. The highest section showed it as a cavity running transversely across the cord from cornu to cornu along the front of the posterior columns, but behind the central canal, and quite distinct from it (woodcut, fig. 1). It ran thus for nearly an inch down the cord, when it became irregular in shape and involved the central canal, reaching forward close behind the anterior median fissure (fig. 2). A little lower down the cavity was much narrowed and partially divided by septa projecting into it (fig. 3). In the lower third of the dorsal region the cavity was again becoming larger, measuring 2 mm. by 1 mm. transversely, and still involved the central canal (fig. 4). Below this the cavity became separated again from the central canal, and occupied the greater part of the right posterior cornu (fig. 5); it was here traversed by numerous fine bands, and two or three millimètres below this it terminated.

As will be seen from the figures, the outline of the cavity was very irregular, sometimes elongated transversely, sometimes from before backwards, sometimes irregularly quadrangular. The wall was not separable as a distinct membrane, nor to the naked eye distinguishable from the rest of the cord. On microscopic examination of sections taken from all parts of the cavity, it was seen that for the most part there was no epithelial lining, but it was present in the sections from one particular level, namely, the upper third of the dorsal region (between figs. 2 and 3.). There the cavity ran transversely across the centre of the cord, including the central canal; on its anterior wall, for 1½ mm. on each side of the middle line, was a single layer of epithelial cells precisely resembling those of the central canal. The tissue immediately bordering the cavity consisted of closely-packed fine fibres, running, for the most part, parallel to the surface, and giving a rather densely fibrous appearance; interspersed were a few oval nuclei, and small tortuous vessels. This narrow border was pretty sharply defined from the white matter, and still more so from the grey substance. The contents of the cavity escaped my notice; even before cutting the cord it was perfectly flaccid, and though I have little doubt it contained fluid, I do not know that the cavity was actually distended by it.

Besides the cavity in the dorsal region, there were two smaller cavities, presenting the same general characters, one in the upper

cervical region, a transverse slit behind the central canal (fig. 1), and another, one eighth of an inch in diameter, in the middle of the cervical swelling.

The examination of the structure of the cord generally was not altogether satisfactory, as the peculiarities it presented were pretty certainly due to commencing decomposition. The tissue of the grey matter was remarkably delicate, scarcely staining with the usual reagents, and seeming to consist only of a fine network of fibrils, with scattered nuclei, cells, and tortuous vessels, while axis cylinders and ganglion cells had almost entirely disappeared, except in the most forward parts of the anterior cornua, and in the posterior vesicular columns, where the cells appeared normal. In the white matter also many axis cylinders were only faintly visible. The central canal, where separated from the larger cavity, showed the usual epithelial cells.

This condition of both grey and white matter was found not only in the neighbourhood of the abnormal cavity, but also in the cervical region, and in the pons and medulla oblongata. But with the exception of the cavity itself, and the condensed tissue immediately bordering it, there was no evidence of inflammation, degeneration, or new growth; there was no increase of connective tissue elements, nor granule corpuscles, nor tumour elements, nor any special affection of the tissue around the central canal.

Sections from the upper and lower dorsal regions, with the details of the cavity, are figured on Plate I, figs. 3 and 4.

Remarks.—Though found in association with distension of the ventricles of the brain, it is clear that the above-described cavity was not a simple dilatation of the central canal. Several cases are now on record of such irregular cavities existing in the cord independent, wholly or in part, of the central canal; and both Leyden and Erb deal with the subject in their works on the spinal cord. From the former [1] it appears that the cavities have been mostly found in the lower cervical or upper dorsal portion of the cord, mostly situate behind the central canal, occupying either the front part of the posterior column or the posterior grey commissure, or one or other of the posterior cornua. Their shape has been irregular, and they have been bounded by a more or less dense layer, consisting of fine fibres and nuclei; sometimes they have been found lined with epithelium. Opinions have differed with regard to the origin of the cavities. In

[1] 'Klinik der Rückenmarkskrankheiten,' vol. ii, p 447.

one or two cases the cavity has been associated with the growth of a distinct tumour in the cord, so that it seemed as if it resulted from the softening of the tumour. Some authors saw a resemblance between the tissue bordering the cavity and that around the central canal, and inferred a hypertrophic new growth of this last tissue, subsequently softening down. A third opinion was that the formation was due to inflammatory changes. The symptomatology has been uncertain; in those cases where the disease was connected with spinal symptoms at all these have been mostly such as would be explained by pressure on, or lesion of, the grey matter; and muscular atrophy has been the most frequent decided effect. In its main features the present case agrees with the picture above given; but it does not give very decided information as to the causation of such cavities, the evidence being chiefly of a negative kind.

May 21*st*, 1878.

---

7. *A case of diabetes; morbid appearances met with in the brain, spinal cord, lungs, and elsewhere.*

By Alexander Silver, M.D., and J. Pearson Irvine, M.D.

The specimen was removed from the body of a male, æt. 19, who died in Charing Cross Hospital in February, 1878. The patient had been the subject of marked diabetes for some time, judging by the history given, and had suffered from occasional cough for several years. He had been an out-patient at different hospitals, but not till 1877 was anything characteristic of a particular disease detected. In November, 1877, he came to Brompton Hospital, and was under the care of Dr. Bruce, who found large quantities of sugar in the urine. The patient at this stage of his disease gave a history of occasional cough and also of hæmoptysis, but nothing was discovered on physical examination of the chest. The abdomen was swollen and especially towards the iliac regions, where hard lumps could be felt, and these seemed continuous with swellings along the spinal column. Careful inquiry showed, when the patient was admitted into Charing Cross Hospital, February 6th, 1878, under the care of Dr. Silver, that for three years at least he had been passing excessive quantities of urine, and

that, though his general state had varied, he had rarely been during that period free from a distressing sense of weakness and languor. His cough, though not constant, had compelled him at times to seek advice.

It is not necessary to discuss with any minuteness the early history this case; nor is it necessary to dilate upon the symptoms of the patient after his admission into hospital. For he had no extraordinary symptoms beyond those met with in most diabetics; he was wasted greatly, had a constant thirst, a capricious appetite, a rough and dry skin, and evidences of disturbances in the gastro-intestinal tract. He had also disorders of vision; he could see and define objects clearly at a single glance, but when his attention was strained he complained of a sense of constriction in the eyeballs, and could not discern objects with the usual freedom. During the last few months of his illness it was noticed that his intellect became dulled and that he betrayed an impediment in his speech. But during his stay in hospital no peculiarity was noted as to the state of his chest, and it may be said that there was an entire absence of the signs of the vast pulmonary changes so frequently met with in diabetes. He passed while in hospital 140—160 ounces of urine daily, and of specific gravity between 1039 and 1045. The confusion of vision when strain was put upon the eyes became more and more decided. The temperature of the patient was usually subnormal for a fortnight after admission (between 95° and 97° Fahr.), but during the last four days of life it rose rapidly and continuously from 95° Fahr. to 104·5° Fahr., death occurring somewhat unexpectedly on the eighteenth day of the patient's stay in hospital.

The *post-mortem* examination was made by Dr. Pearson Irvine. The patient was much emaciated and weighed little more than six stone. The brain was fairly normal, but the membranes were here and there opaque, and there was some fluid beneath them. The left frontal convolutions (and the island of Reil especially) were somewhat soft, but the medulla oblongata was healthy, and no change could be detected in the fourth ventricle. In the spinal cord were found two softened portions, one in the neck, extending from the level of the third to the fifth cervical vertebræ, and another from the seventh cervical to the second dorsal vertebræ. In this latter portion the softening was more decided than in the former, and outside the sheath of the cord adjacent to this patch of softening

was found a well-marked blood-clot, between two and three inches long. A fine capillary injection of the pia mater was found in the middle dorsal region, and also on the lumbar region, especially on the posterior aspect, though the body had been on the face for some time before the *post-mortem* was made. In the lower lumbar region, outside the membranes of the cord, was discovered a quantity of a peculiar red currant-jelly-looking substance, which on microscopic examination seemed to consist of areolar tissue infiltrated by changed blood and its colouring matters. It entirely surrounded the cord and filled the spinal canal for a distance of two inches.

The lungs were much diseased. The upper lobe of the right lung was converted into a large cavity, the walls of this cavity being irregular and worm-eaten, and pointing to a recent and rapid change. The cavity contained solid and fluid grumous matters, which were free from odour. They seemed to consist (microscopically) of broken-down lung tissue and disintegrated blood, and to be remarkably free from pus. The apex of the left lung contained numerous patches of catarrhal pneumonia, mostly in the caseous, but some in the earlier stages of this disease. The lower lobes of both lungs were diseased; in them the pneumonic patches were recent but still decided. On the pericardium and encircling the base of the heart there were quantities of gelatinous material, like that found in the spinal canal; and even around the kidneys, which were congested, the same appearances existed. The liver was large but smooth, firm on section, hard to the touch, and dark in colour. The stomach and bowels were normal, but the pancreas was hard, nodulated, and atrophied.

Dr. Silver pointed out that the main interest of the case lay in blood-clot in the spinal canal and the softening of the cord. This softening occurred first at the spots where, on theoretical grounds, it might have been expected, inasmuch as by repeated experiments it has been shown that the special controlling nerve-fibres of the liver follow a course which is intersected by the softened tracts met with in this case. The course followed by these fibres is from the medulla oblongata on the floor of the fourth ventricle by the spinal cord to the level of the vertebral artery; and thence along this vessel they run to join the second and third cervical ganglia of the sympathetic. After forming a ring round the subclavian artery (the annulus of Vieussens) they join the first dorsal ganglion, and thence pass downwards by the dorsal gangliated cord and splanchnics

to the cœliac plexus and the liver. In some cases the fibres leave the spinal cord lower down, at about the level of the first and second dorsal vertebræ.

The existence of such extensive lung disease without marked physical or general signs is of importance in this case, as is also the temperature met with in association with these changes. Even when by physical signs it is not possible to explain a rapid rise of temperature from subnormal through several degrees in cases of diabetes, we would not hesitate to give a prognosis of immediate danger.

This case is reported as one which may help to elucidate the pathology and morbid anatomy of diabetes. The appearances met with were possibly accidental, but they seemed sufficiently peculiar to justify their exhibition to the Society. The peculiarity of the appearances and the uncertainty of the morbid phenomena found in diabetes are the reasons why, not only the spinal cord but the vertebral column, with the cord *in situ*, has been removed and shown to the Society exactly as met with in the *post-mortem* room.

March 5th, 1878.

II. DISEASES, ETC., OF THE ORGANS OF RESPIRATION.

1. *Diphtheria associated with enteric fever.*

By W. S. Greenfield, M.D.

The fresh specimens shown are from a female child, aged five years, who was under the care of Dr. Murchison with enteric fever, and who died of diphtheria. The symptoms of enteric fever were well marked, and the nature of the disease was shown by the fact that a brother was in the hospital at the same time with the same disease, and other members of the family also suffered.

The symptoms of the case need not be detailed; they were the ordinary ones of enteric fever.

Post-mortem examination.—Body of well-nourished, well-formed child. No petechiæ or ecchymoses on skin.

Throat, &c.—Tongue natural. Tonsils and left palate, as seen from front, swollen and congested, but free from ulceration. On left tonsil, one or two minute flecks resembling false membrane. Posterior surface of soft palate, and mucous membrane in upper part of pharynx around posterior nares, covered with a thin pellicular layer of false membrane, of somewhat irregular thickness,—mucous membrane around and subjacent of deep red colour; glands, especially those around orifices of Eustachian tubes, much swollen. A small quantity of false membrane was present as a very thin pellicle at the posterior base of the pharynx at its upper part, but more on that below level of velum palati.

Upper part of larynx with epiglottis and mucous membrane immediately around orifice swollen and much congested, false membrane covering the edges. On laying open the larynx and trachea they were found to be filled with thick muco-purulent layers; the cavity of the tongue and the upper part of the trachea lined with false membrane of the usual diphtheritic character. In the larynx is a

thin tenacious, fibrous-looking lamina, especially adherent about the glottis. In the upper half of the trachea a similar layer, readily separated from the intensely congested subjacent mucous membrane. One or two small flakes were found lower down in the trachea, beneath one of which a small superficial ulcer existed.

Glands beneath jaw much swollen, congested, with pale mottled patches. Tissues around larynx generally swollen.

Pleuræ.—Free from adhesions and effusion. Very numerous small ecchymoses scattered over visceral layer, especially over lower lobes and posteriorly.

Lungs.—Right weighed 11½ oz., left 10 oz. Very extensive consolidation of both. Bronchi, even to the minutest ramifications, filled with puriform fluid, their mucous membrane not much congested in the smaller branches.

On section of the lungs where consolidated, they presented the usual appearances of broncho-pneumonia, but in various stages. At some parts the appearance was that of extensive tracts of lobular collapse, with here and there intense almost hæmorrhagic congestion, these portions usually surrounding small bronchiæ filled with pus. Elsewhere ordinary lobular pneumonia in various stages, apparently arising from collapse.

Heart weighed 3 oz.; healthy.

Peritoneum, natural.

Liver weighed 1lb. 10½ oz., pale, rather soft; lobules apparently swollen, their outlines of very pale yellowish colour (parenchymatous swelling).

Spleen, 4 oz., deep red, soft on section, much congested, friable.

Kidneys, 6 oz., cortex slightly swollen and pale, otherwise natural.

Stomach.—Slight catarrh, otherwise normal.

Intestines.—Small intestines in greater part of their extent healthy, containing but little pale yellow fæcal matter. The disease changes were entirely limited to the lower eight or nine inches of the small intestine.

Peyer's patches and solitary glands in lower three inches swollen and congested, forming a somewhat irregular mass of swelling, on which were seen seven or eight small round sharply excavated ulcers, each with a central yellow slough, or shreds of sloughs. These ulcers were of nearly uniform size and shape, measuring only 3 to 5 mm. (⅕th inch) in diameter; none so large as a split pea. The slough in no case extended deeper than the mucous membrane.

For about three inches above this, some of the solitary glands and some small portions of Peyer's patches presented very slight swelling. often only one or two follicles being a little more raised than the rest, and of slightly pinkish colour. Three or four small superficial ulcers, like those below, or only shallow excavations of the upper layers of the mucous membrane, existed at this part.

Above this the glands were entirely free from swelling or redness and perfectly healthy.

Cæcum and colon.—Mucous membrane pale and healthy; not the slightest swelling of any of the glands in caput cœcum.

Mesenteric glands in the neighbourhood of lower part of ileum swollen, congested, with pale mottling, but free from softening or suppuration. *November 6th*, 1877.

---

2. *Millstone-makers' disease; siliceous matter found in the lung.*

By T. B. Peacock, M.D.

Benjamin G—, æt. 29, a French millstone maker or builder, admitted into the Victoria Park Hospital for Diseases of the Chest, December 7th, 1877.

He stated that he had been apprenticed to the trade at 15, and had continued to work at it ever since.

His father died of smallpox, but his mother and three brothers and three sisters were living and healthy.

He had never had any illness before the commencement of his present attack. He stated that he had always been a temperate man, but subsequent information threw doubt on this assertion.

His illness commenced nine months before his admission into the hospital, after he had been working in wet clothes. He had spat a single clot of blood five months before he applied at the hospital, and lost his voice four months before.

When admitted he was much emaciated, his hands were livid and his lips purple, and he had a hacking cough and much expectoration, and his voice was completely abortive, His appetite was very defective, and he had sickness after food and was restless at night.

The pulse was 124, the temperature 103·8°; the urine had a sp. gr. of 1020, and contained much lithates but no albumen.

The movement at the upper part of the chest was very defective on both sides, and there was marked want of expansion under the clavicles, especially on the right side, where also the resonance on percussion was much impaired, and there was loud bronchial or cavernous respiration. There was also dulness on percussion in the right dorsal region, and a loud souffle with the cough, and much rhonchus was heard in all parts of the chest.

On the 17th, without any obvious cause, he had a severe attack of dyspnœa, and became very much exhausted and was very livid. There was a rough systolic sound heard during the time at the apex of the heart. He died on the 20th.

On *post-mortem examination* there were slight adhesions on the left side, particularly towards the apex, and the left lung was extensively consolidated in every part and contained numerous cavities. The right pleura was also adherent, especially towards the apex, and there was there a large irregular cavity. The posterior part of the middle lobe was in a state of grey induration, being hard, so as not easily to break down.

The right vocal cord was almost entirely destroyed, but the mucous membrane of the larynx was pale and smooth; the bronchial mucous membrane was generally red and villous.

Some of the bronchial glands were much enlarged, and were hard and gritty to the touch.

The heart was large, weighing 12½ oz., but was not otherwise abnormal. The kidneys were healthy; the liver somewhat small.

Portions of the indurated right lung were subjected to analysis in Dr. Bernays' laboratory at St. Thomas's Hospital, and the ash was found to contain 0·406 per cent. of silex. A portion of the consolidated lung was examined microscopically by Dr. Sharkey, who furnished the following report:—

"The portion of lung, which had a marbled white and grey appearance to the naked eye (Plate II), appeared to have been compressed artificially to a considerable extent, and this was verified by the microscopic examination, which showed the bronchi so flattened that their lumen appeared as a slit, and the alveoli, which could be made out, were converted for most part into longitudinal compartments. The compression made the examination very difficult.

"There were various morbid processes going on in different parts.

DESCRIPTION OF PLATE II.

This plate illustrates Dr. Peacock's case of French millstone-makers' disease. (Page 31.)

FIG. 1. Drawing of lung as seen with the naked eye.

FIG. 2. Section of diseased lung magnified 120 diameters. (*a.*) Bronchi denuded of their epithelium and with walls greatly thickened by concentric growth of fibrous tissue, which extends far into lung tissue at *c*. (*b.*) Growth of young cells, some of which develop into fibrous tissue. A considerable amount of black pigmentary deposit is seen, in some parts in the young cells, in others in the fully formed connective tissue.

Fig. I.



Fig II.

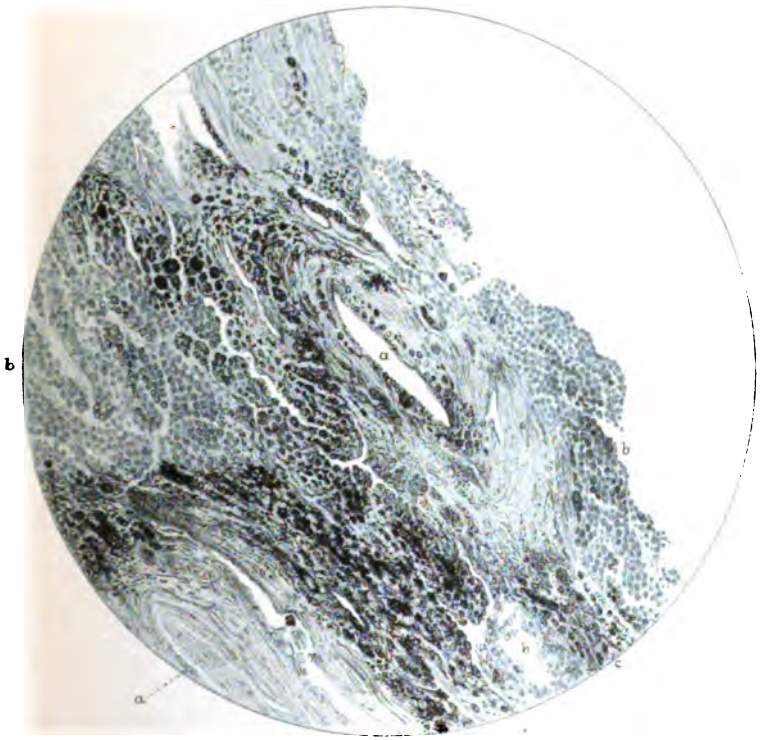

× 120

E. Burgess del et ch lith.

W West & Co. imp

1. The bronchi generally were much thickened, the epithelium gone. The thickening was due to fibroid changes, and the fibrosis extended into other parts, so that very thick strands of well-developed connective tissue could be seen (Plate II). This, however, affected the alveolar walls to a very small extent. 2. Here and there in the connective tissue there were streaks or foci of small celled growths, probably recent. 3. The alveoli appeared to be in three different conditions—(*a*) some parts were full of granular, very firm matter, which did not stain (caseous degeneration); (*b*) others were filled more loosely by catarrhal products, large nucleated cells, and small granular white cells; (*c*) others, again, were firmly filled with small granular cells, which took the staining well, and were held tightly together, and in some places distinct strings of fibrine could be seen amongst them. The dark pigment was contained both in the cells within the alveoli, where it produced an irregular, smudgy appearance, and in the connective tissue strands, where it ran in streaks, owing to the elongated condition of the cells" (Pl. II, fig. 2).

Dr. Bristowe has also examined the specimen, and confirms the report of Dr. Sharkey.

The present is the third case in which siliceous matter has been found on chemical analysis to exist in the lungs of French millstone builders who have died under my care.

The *French millstone makers*, or *builders*, as they perhaps more properly call themselves, are employed in the manufacture of stones for the grinding of wheat and other hard grains, from the "*French burr*," a peculiarly hard form of silex which occurs in fresh water formations of the tertiary strata of the Paris basin. Of this the best kind is at present obtained at La Ferte Bernard, near Le Mans. It is of a yellowish-brown colour, translucent, and somewhat cellular, and is imported in masses of about a foot in length, six inches wide, and six inches deep, and as the ordinary millstones are about four feet six inches wide, each finished stone is composed of twelve to fourteen or sixteen of these masses or angular blocks fitted and cemented together, and bound round with iron bands or tyres. The stones are first roughly dressed or shaped with a steel chisel and hammer, and the blocks are then finished, and the grooves in the grinding surfaces formed with an instrument called a "bill and thrift." In the last part of the work a large quantity of rough grit and particles of metal is thrown off, and it is doubtless from the inhalation of this grit and the metal that the occupation

becomes so injurious to the men. The backs of their hands are covered with dark marks, produced by the particles of metal which are thrown off and become embedded in the skin, and the dust collected in the shops contains numerous sharp metallic spiculæ.

When my attention was first attracted to the frequency of pulmonary disease among the French millstone builders,[1] I was told that, when boys were apprenticed to the trade, they survived only for a few years, and that even when persons take to the occupation later in life and after reaching their full powers, their lives are of very short duration, few attaining or exceeding the age of forty; the observations I have been able myself to make confirm these representations. The men engaged in the trade in London are only a very limited number, yet I have seen several cases of fatal pulmonary disease among them. The two patients whom I first saw died at the ages of twenty-three and thirty-seven; a third, a portion of whose lungs I exhibited at a former meeting of the Society, died at the age of forty-eight, and another patient, who was at the Victoria Park Hospital under Dr. Andrew, and whose case is referred to by Dr. Shepherd in his Gulstonian lectures, was forty-five. The subject of the present case was only twenty-nine. When the men attain more advanced ages, it is generally found that they have not been constantly engaged at the trade, but finding their health failing had left it to act as engineers in corn-mills, where they are only occasionally employed in dressing the stones, or to follow some other occupation which is less injurious.

May 21*st*, 1878.

---

3. *Miliary tubercle of the lungs in an infant aged three months.*

By Edwards Crisp, M.D.

This case I examined with Dr. Haynes about three weeks since. The child, aged three months, was found dead in its bed in the morning about five o'clock, and a coroner's inquest was held in consequence. It had been a delicate child from its birth, was rather thin and pale, had occasional cough, but presented no very marked symptoms, and the day before its death was as well

[1] 'British and Foreign Medico-Chirurgical Review,' Jan., 1860.

as usual. The mother died of pulmonary phthisis about a month before the child. On her side (the mother's) there was hereditary predisposition to tubercle, but not on that of the husband. The parents have had four children; three, including the one whose case I am describing, have died of supposed tubercle of the lungs, and the one living, the eldest, a girl, seven years of age, has, I believe, from the examination I have made, tubercle in both lungs.

Externally the body presented nothing remarkable; it was rather thin, the skin blanched, and the integuments and muscles lax.

The brain was very carefully examined and sliced throughout, and with the exception of the presence of about three teaspoonfuls of serum in the lateral ventricles no abnormal appearance could be detected. It was not subjected to microscopical examination. The stomach, intestines, spleen, liver, and kidneys as far as could be ascertained, were in a healthy condition and free from tubercle.

The lungs were studded in all directions, both externally and internally, with miliary tubercles of a light, yellowish colour, generally about the size of a pin's head; probably in both lungs the number would amount to two or three thousand. Under the microscope, as shown in the drawing, they present the ordinary appearance of this form of tubercle; granular matter, refractive nucleoli, and nucleated cells.

At the root of the lungs one of the bronchial glands (as will be seen in the specimen), about the size of a marble, is converted into a soft caseous substance of a yellowish colour, and this probably was the source of the lung infection.

The wax casts which I have taken exhibit the appearances when first seen, which are almost entirely lost after immersion in spirits.

The early age of the patient, the family history, the isolation of the tubercle, and the caseous gland, are all, I think, matters of especial interest.

In the fourth volume of our 'Transactions,' 1852, page 42, I have recorded the case of an infant of the same age (three months) that died of miliary tubercle of the lungs and spleen, with fatty liver. In this instance there was no family history of tubercle; the child was in good condition, and exhibited no symptoms commensurate with the gravity of the lesions found. *November 6th*, 1877.

4. *Destructive pneumonia due to compression of bronchus by aneurysm of aorta.*

By J. Pearson Irvine, M.D.

A labourer, æt. 43, was admitted into Charing Cross Hospital, under Dr. Silver, on April 17th, 1877, and died in July of the same year. His family history pointed to no hereditary disease, and it may be especially mentioned that chest affections were unknown in his family. He was a steady, industrious man, but his work was heavy and laborious; and to an over-straining in that work at the end of 1876 he attributed his illness. About Christmas, 1876, he began to suffer from hoarseness and dyspnœa, and a month or two later from pains of cutting character over the left side of the chest.

His subsequent history up to the time of admission was one of cough and dyspnœa, of difficulty in swallowing, with sense of pain behind lower third of the breast-bone, and of loss of flesh. Three weeks previous to admission orthopnœa became severe, and the pain extended down the left arm. He had not had syphilis.

On admission his orthopnœa was found not to be great, and he could lie more easily on the left side than in any other position. He was a little cyanotic and somewhat wasted. His pupils were equal; there was no arcus senilis, but marked evidences of degeneration in the arteries of the extremities. The pulse at the left wrist was weaker than that of the right. He complained of pain in the left arm, in the left chest, and between the shoulders, of a dull heavy character, and of dyspnœa, which, like the pain, was increased by the least exertion.

The surface veins of the chest were slightly enlarged, and the sternum and second and third cartilages on the left bulged. There was marked impulse over the inner two inches of the second left space, and one over inner inch of the second right space, with an indistinct wave of pulsation over the cardiac area and sternum adjacent. In the second left space the impulse was distinctly heaving and expansile, and was systolic, though there was besides a slight diastolic impulse. There was no thrill. Dulness existed over the sites of pulsation mentioned, and this dulness ran into that of the

general cardiac area. A systolic murmur could be heard over the same positions, and in some places a very faint diastolic murmur, while generally the second sound was clear and accentuated. The systolic bruit could be heard in the carotids and in the left vertebral groove in the dorsal region.

At the time of admission no serious mischief was discovered in the lungs, though air entered less freely the left base than the right, and cough was easily explained by the signs of aneurysm. The man was hoarse, but his throat was not sore; his voice was weak, but not toneless; after excitement he had attacks of intense dyspnœa, accompanied by larynyeal breathing. He improved to all appearances shortly after admission, deriving benefit from belladonna plasters, and liniments of opium and belladonna. But soon afterwards it was observed that the left lung was undergoing change, a gradual but rapid change, and the case was diagnosed as identical with one in the hospital the previous year, the pathological results of which I have shown to this Society (1877).

Diagnosis of the lung change was made from analogy. The physical signs were those of a progressive consolidation, not of sudden collapse, for the side never sank, though the left back became gradually dull throughout, and the left front also, high on the second space. Weak bronchial or amphoric breathing—both very distant, with equally distant obscure râles—became audible, and it seemed likely that these were conducted through a consolidated lung, into which but little air was entering. The patient had no expectoration except of a little bronchial secretion, and none of the severe general symptoms which attend destructive phthisis of the ordinary type, but his temperature during the last six weeks was always above normal, varying from 99° to 101·5° Fahr., and the evening exacerbations were often as much as three degrees. The physical signs of the aneurysm underwent no marked change, but the man suffered considerably towards the end and required hypodermic injections of morphia. He died on July 15th, three months after admission.

The body was found considerably wasted at the post-mortem examination, and when the thorax was opened grumous reddish fluid escaped in large quantities from the mouth and nostrils. The anterior edges of the right lung were distinctly emphysematous. The heart was but little enlarged. On the ascending aorta was an aneurysm, the size of a large orange, springing in the form of a

pouch or sac about an inch above its origin, and growing backwards and to the left. It communicated with the vessel by an orifice, the size of a half-crown piece, and was overlapped by the left lung, so that but little of it was in direct contact with the chest wall. It had grown in such a way as to compress slightly the trachea and œsophagus, but greatly the left bronchus immediately beyond the bifurcation. This compression had destroyed the tissues of this bronchus; the inner surfaces of the air-tube exactly opposite it were ulcerated and the cartilages eroded; the bronchus had been compressed where it could not yield, and in consequence nothing remained to guard the aneurysm from rupture except a large compressed gland lying in the angle of bifurcation, the softened bronchial walls, and a thin though firm layer of fibrin which lined the otherwise empty aneurysm.

The left lung was much larger than natural; it was smooth on the surface (except in one spot, where there was a cicatrix-like patch); its pleura was uniformly thickened and discoloured, and the lung itself was hard and firm to the touch, heavy, and more like a solid viscus than lung when handled. It bore the impression of the ribs and was adherent, especially its upper lobe, posteriorly and laterally. On section this lung was found more or less completely disintegrated, and consisted mainly of a mass of cavities filled with the reddish grumous fluids mentioned, which were perfectly free from any bad, much less gangrenous, odour, and resembled pus and disintegrated blood mixed. The cavities, cribriform in kind, were crossed by fibrous bands, the remnants of lung tissue; but in other parts were bands or masses of a gelatinous character, consisting of a recent growth of fibre-tissue, like that met with in ordinary interstitial pneumonia. The bronchi beyond the seat of compression had yielded more or less and their walls had broken in various places, so that their dilatations formed a part of the numerous cavities. The changes described were most marked in the lower lobe, and that part of the upper lobe which overlapped the tumour, and was subjected most of all to direct pressure by it, was the healthiest part of the lung. In it some air-breathing tissue was left, and the secondary changes looked like an early stage of advanced destruction in an emphysematous lung, such as were found in the lower lobe. The right lung was simply emphysematous and showed not the least trace of pneumonic change, aud its bronchus was not compressed by the aneurysm.

The liver was a little enlarged and fatty, but no other morbid sign of consequence was met with. In the case reported last year, as in this, the contents of the cavities of the disintegrated lung were free from odour—facts which indicate that air had not entered these cavities for a long time. The contents consisted of débris of lung tissue, disintegrated blood, and sweet pus. Caseous, solid masses were found amongst the liquid contents. In neither case was there any expectoration of such matters during life.

The following facts are worthy of notice:—(1) The left lung was larger than natural; (2) it had undergone decided destructive changes; (3) its bronchus had been directly compressed by an aneurysmal tumour; (4) the aneurysm contained scarcely any clot. The first fact tends to prove that collapse could not have been the first result of the bronchial impediment, and I would adduce this case as a proof of the view which I advanced in the 'Transactions' last year, that probably emphysema is the primary consequence of bronchial pressure. In a case of aneurysm pressing on an air-tube the effects must be long and of steady growth, and the tendency be rather to obstruction of the exit than entrance of air. Inspiration, by dilating the bronchi, must assist in overcoming outside pressure on them, but expiration would have an exactly opposite result; it causes the tubes to collapse, and thus, no matter what occurs in the case of tubes obstructed within, it must, by increasing its own efforts, have made the difficulty of exit greater. Besides, expiration is more powerful than inspiration, and it is clear from a mechanical point of view that under the circumstances named emphysema of the lung must have been the first occurrence. Then the obstruction becoming more and more complete secretions must have accumulated in the air-tubes beyond; these must have excited a certain amount of bronchitis, followed by further secretion, until by-and-bye the whole of the lung beyond the obstructed bronchus became filled with these—they displacing the air and leading to its absorption. It is not difficult to understand that, this condition arrived at, the lung tissue, thus completely shut off from the external air by bronchial occlusion, must have endured intense compression from within, that its vessels must have been occluded, that its nutrition must have been completely interfered with, and destructive changes readily started in it.

Affection of the peribronchial tissues were the beginning of the

changes (as examination of the least affected parts of the lung showed), and an interstitial pneumonia of marked kind was set up, which ended, not only in formation of fibre tissue, but in vast destruction. I venture to think that in this alone lies the explanation of all met with in the lung described. The explanation is just as applicable to the case reported by me last year, the only difference being that in it there was less destruction (equal consolidation, but less disintegration, with resulting cavities), because the process was much more chronic. The two cases prove that destructive pneumonia is a consequence of pressure on the bronchi rather than of pressure on the nerves. It is true, however, that in some cases of bronchial compression collapse does occur suddenly, and that subsequent changes may be due to the mechanical effects of accumulating secretions in such collapsed lungs; but the clinical history, as well as the *post-mortem* appearances, is clearly against the sudden occurrence of collapse in the above case. I would suggest that the absence of clot from an aneurysm has an important bearing in these cases. Is it not likely that an empty aneurysm would exercise a more decided pressure than one filled by firm clot? I only suggest this view because I have heard the opposite opinion advanced; however, in my case the aneurysms were empty, and it is certainly the case that oftentimes aneurysms have compressed bronchial tubes without causing the marked changes described.

I alluded last year to the similarity of the changes in destructive pneumonia, arising in the manner given, with those met with in some cases of so-called syphilitic pneumonia. In many of these the bronchial tubes have been found invaded by fibrous growth, which has narrowed or twisted them in such a way that there must have been great bronchial obstruction. In such I believe that the lung changes are not specific, but are instances of a mechanically induced interstitial and destructive process in every way identical with those described. The lung, at any rate, suffers only on the side of the bronchial mischief; the opposite lung simply shows evidences of a consecutive emphysema. It is worthy of note, also, that in these cases of syphilitic pneumonia there is no mention made of the occurrence of collapse, the lung being large, as in my cases.

October 16*th*, 1877.

5. *Case of aneurysm of a branch of the pulmonary artery; death from hæmorrhage.*

By Samuel West, M.B.

The patient was a woman, æt. 46, who was brought in dead to the hospital, having been found in the streets lying in a pool of blood. She had, it transpired, been an out-patient for a few days previously, suffering from slight hæmoptysis. The friends stated that she had never been a very strong woman, but that, with the exception of a slight cough for some years, had always been in tolerable health. She was the mother of twelve children.

The *post-mortem* examination proved the hamorrhage to have come from the lungs, which were found in the following condition:

Condition of the lungs.—Left lung: pleural cavity obliterated by old adhesion. No consolidation anywhere; contained air in all parts, and abundant blood mixed with the air in the alveoli and bronchial tubes. Nothing in the nature of an infarct.

Right lung in the same condition, except in two places, where patches of induration were felt. The one at the apex involved only a small portion of the lung; was of an irregular wedge shape, with its base upon the surface of the lung. It was formed of dense connective tissue, following the divisions of a small bronchial tube. These branches were in the condition of chronic inflammation, the mucous membrane almost entirely destroyed, and the network of elastic and fibrous tissue exposed. The new growth of connective tissue was chiefly peribronchial, and in the denser portions several bronchiectatic cavities lay.

The pleura was adherent over the whole lung; but was most thickened over the patch of induration just described.

The second, in the base of the lung, was of much greater extent, forming a roughly globular mass about the size of a small orange (2 inches in diameter.). It lay deeper in the substance of the lung itself, and not, like that at the apex, near the surface. The changes here were the same as at the apex, but the cavities were somewhat larger and more numerous. The smaller were clearly dilatations of bronchi, while the larger had lost their bronchial characters, and the walls were formed of altered lung tissue. The

largest, in fact, the only really large cavity, was about the size of a walnut. This was filled with blood, with a few clots, and in the neighbourhood the lung was most densely choked with blood.

Hanging into this cavity was found a globular, soft, fleshy sac, ruptured in that part nearest the centre of the cavity. A probe passed through the aperture easily into a large vessel (artery) running at the side of the bronchus, of which this cavity had been evidently originally a dilatation.

This was the source of the hæmorrhage. Heart and blood-vessels, with this exception, were healthy, and the *post-mortem* presented no other features of interest.

The sequence of changes was, I believe, bronchitis and peribronchitis chronica, with induration and condensation of the lung tissue round the affected bronchi; and the formation of bronchiectatic cavities, in one of which the aneurysm, found ruptured, had subsequently developed.

This case is of great interest, as showing how very localised these changes may occasionally be. There was, however, no cause found sufficiently to explain the fact that in this case the changes were so limited in extent. *May* 21*st*, 1878.

DISEASES, ETC., OF THE ORGANS OF CIRCULATION.

1. *Malformation of the heart; large aperture in the septum of the auricles; with the foramen ovale closed.*

By T. B. Peacock, M.D.

Emily P—, æt. 10, residing at Battersea, admitted into Alice Ward, St. Thomas's Hospital, November 28th, 1876. She was a puny delicate-looking child; her father was living, at the age of forty, but was said to be consumptive; her mother was also alive and healthy, aged thirty-six. Their family, six in number, were all living and, except this child, healthy. She had suffered from shortness of breath and pains in the chest from infancy. Her cheeks were flushed and her lips purple, and she had great dyspnœa on exertion, and the feet were slightly œdematous; the fingers were not clubbed and the hands not livid.

The pulse was 108 and somewhat irregular both in force and frequency; the respirations short and rapid, 48.

She had an extremely deformed chest, the sternum being very prominent, and especially at its lower end; the parietes were also prominent on each side of the bone below, and especially on the left side; where, indeed, the præcordial space formed a distinct tumour, which exactly indicated the position and size of the heart.

The dulness on percussion commenced about a finger's breadth below the clavicle, and extended in the transverse direction from the line of the nipple on the right side of the chest to beyond the corresponding line on the left side. There was a marked purring tremour over the whole of the dull space, but it was most distinct below the left nipple. The apex of the heart appeared to beat in the fourth interspace near the nipple. There was a loud murmur audible with the systole at the base of the heart, along the upper part of the

sternum, and on each side of that bone, but it was most loudly heard over a limited space on the right side of the sternum at the level of the junction of the upper and middle third of the sternum; a loud twanging sound was heard in the corresponding situation in the left side, and this sound extended in a line towards the middle of the left clavicle; a similar sound was audible, but less intensely, at the apex, and still more feebly behind. The jugular veins were distended and pulsated. The hepatic dulness descended into the abdomen to the level of the umbilicus. The respiratory sound was puerile. The temperature was low, 96·4°.

She was directed to have a mild alterative powder and to take the stomachic mixture.

On December 6th she was, upon the whole, somewhat better. She had not much cough or expectoration, but the breath was short and hurried, especially during sleep. The temperature had been generally below the natural standard. In the morning it ranged between 97·6° and 96·2°. In the evening between 98·8° and 95·8°. The pulse was 108; the respirations were 44. As she lay upon her back the dulness on percussion commenced immediately below the clavicle and became entire at the second interspace. Transversely it extended from a finger's breadth to the right of the sternum to the same distance beyond the line of the left nipple; the pulsation of the heart was visible in several interspaces, but it was most distinct in the fourth, between the nipple and the sternum; the apex apparently beat in the fourth interspace, immediately below and within the line of the nipple, and there was very marked retraction of the integuments in that situation.

The purring tremor was very distinctly felt over a large space below the nipple, and less distinctly above. There was a loud murmur of a peculiar flapping character heard at the base, and especially on the left of the sternum, and for some distance from that point. It was also heard, but less loudly, at the apex and behind. At the base it was followed by a loud ringing second sound. There was also a blowing murmur heard at the top of the sternum and at the apex.

On January 9th, 1877, she was reported to be somewhat better. The temperature continued low in the morning, ranging between 98·4° and 96·4°, and in the evening, between 98° and 96·4°. She had complained much of pain in the heart, but had been relieved by the application of extract of belladonna. She suffered from paroxysms

of dyspnœa at intervals. The physical signs were much as before. The urine had a sp. gr. of 1031, and did not contain albumen.

The abdomen was more tumid and the lower extremities were becoming more œdematous, and a flapping systolic sound was heard at the base and in the course of the pulmonary artery, and less distinctly at the apex and slightly behind.

On the 7th of February the extremities, which had begun to swell at the beginning of the previous month, became much more œdematous. The urine was also found to be albuminous, but had a sp. gr. of 1020; on the 6th the sp. gr. was 1022, and there was one third of albumen. The face was very puffy and the cheeks had a livid patchy flush. The præcordial space was even more prominent than when she was first admitted into the hospital. She had much pain in the region of the heart, severe paroxysms of dyspnœa occurred at intervals, and there was much bronchitic rhonchus in the chest. She died on the 24th. During the latter part of her life the purring tumour continued to be felt very distinctly below the nipple, but was perceived also at the base, and slightly at the top of the sternum, and on the right side of the upper part of the bone. The murmur was also heard and most loudly at the apex, and it was sometimes preceded by a rougher sound, especially towards the apex.

The *post-mortem examination* took place six and a half hours after death, and was performed by Dr. Greenfield, to whom I am indebted for the following notes:

There was some general anasarca, especially in the lower limbs. The peritoneal sac contained about four pints of clear fluid, and the right pleura about three quarters of a pint, and the left pleura a pint.

The superficial area of the heart extended from the level of the second cartilage to the upper border of the seventh rib, at the point of junction with the cartilage, measuring in the middle line six inches, and obliquely in its greatest length eight inches. The circumference of the ventricles, after the removal of the clot, measured thirteen and a half inches.

The innominate vein was of small size, and the vena cava notably small. The heart was removed to the museum unopened.

The lungs were of very dark colour, and firm, fleshy, and dry, especially the lower lobes of the left lung. There was a narrow

strip of emphysema towards the anterior margin of each lung. The larynx and trachea were healthy.

The liver was extremely dense and tough, and slightly granular. The surface was of a deep purple colour, and on section some parts presented the ordinary nutmeg character, others were pale; the hepatic vessels were dilated. There was great general overgrowth of fibroid tissue. The spleen was rather large and indurated. It weighed six and a half ounces.

The kidneys were extremely indurated and rather pale; they weighed four ounces.

The brain and its membranes were normal and weighed thirty-nine ounces.

The heart was not examined till it had been for some time in spirits. It was very large for the age of the child, but the increase of size depended rather on dilatation of the cavities than on hypertrophy, so that the weight when recent probably did not exceed eight ounces.

The right auricle and ventricle were especially large; the walls of the ventricle were about 2 Paris lines in thickness.

The orifice of the pulmonary artery admitted a ball 33 Paris lines in circumference=74·25 mm. and 2·93 English inches and the trunk of the artery was extremely large; the valves were slightly thickened, but did not present any material appearances of disease.

The walls of the left ventricle measured 3·5, 4·75, and 2 Paris lines in thickness near the base, at the mid point, and near the apex. The left auriculo-ventricular aperture admitted a ball measuring 39 Paris lines in circumference=87·75 mm. and 3·4 English inches. The aortic orifice was very small, but having been cut could not be measured. Both sets of valves were apparently healthy. The aorta was very small throughout its thoracic course, measuring, where it was cut across, about 3 inches below the origin of the left subclavian artery 12 Paris lines in circumference=27 mm. and 1·06 English inches.

The pericardium was quite healthy and presented no appearance of roughness, white spots, or adhesions. In the septum of the auricles there was a large rounded aperture (Plate III, *a*), measuring 39 Paris lines in circumference=89·75 mm. and 3·4 English inches. This opening was bounded by thick bands of muscle, and the endocardium at its edges was somewhat thick and rough. Behind the opening, and between the posterior edge and the entrance into the auricle of the descending cava, there was a small triangular space, covered by a somewhat thin diaphanous membrane, which appeared to represent

DESCRIPTION OF PLATE III.

This Plate illustrates Dr. Peacock's case of Congenital Defect in the Septum of the Auricles. (Page 43.)

a. Aperture in the septum of the auricles.

b. Situation of the closed foramen ovale.

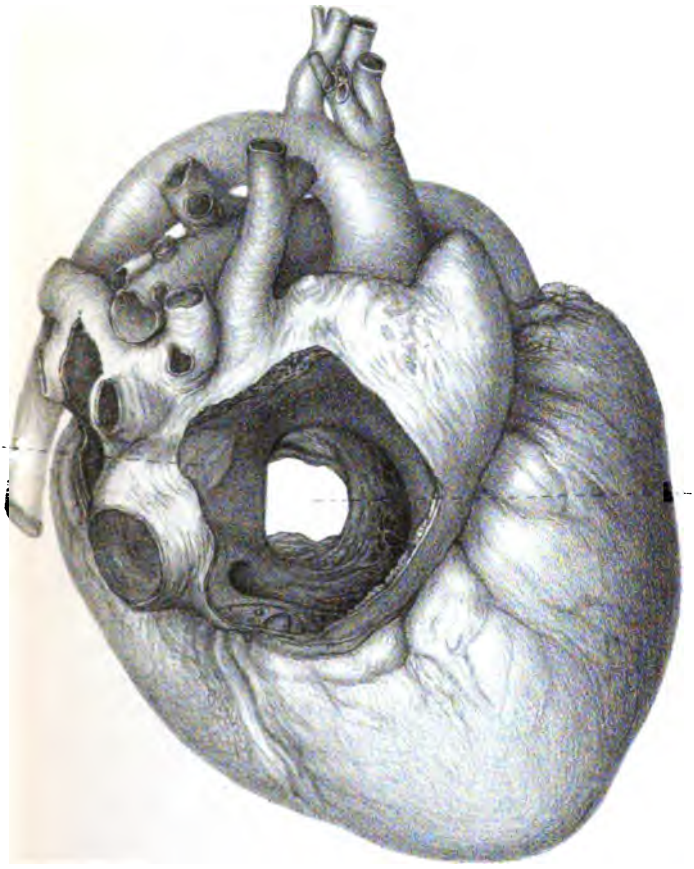

F. Wearne del et lith

W. West & Co. imp

the foramen ovale closed by its membrane (Plate III, *b*). The ductus arteriosus was completely impervious.

The heart not having been examined in this case till it had been some time in spirits, it is impossible satisfactorily to explain the conditions upon which the physical signs which had been observed during life were dependent. It is, however, probable that the murmur heard in the præcordia and at the upper part of the sternum, and the accompanying thrill, were caused by the difficulty in transmitting the blood through the contracted aorta. It is also probable that there was some mitral incompetency.

The lowness of the temperature which was observed is a very interesting fact, as is also the slight degree of cyanosis which had existed, notwithstanding the opportunity for the free intermixture of the currents of blood through the large aperture which existed in the septum of the auricles. *February 19th*, 1878.

---

2. *Defective muscular development of the cardiac ventricular septum; consequent septal aneurysm; displacement of an aortic valve by this aneurysm.*

By J. Pearson Irvine, M.D.

A man, æt. 50, a journalist, died of phthisis, of ten months' duration, in Charing Cross Hospital, on Jan. 24th, 1878. He was in hospital eighteen days, under the care of Dr. Green, and showed the several signs and symptoms of advanced lung disease. He had never had rheumatism, but once suffered from an attack of gout, and in his youth contracted a chancre. His life had been irregular for many years.

In addition to the lung signs, an apex systolic murmur could be heard, rough in kind and conducted but slightly towards the left axilla. This murmur could be heard generally over the cardiac area to the left of the sternum. The pulmonary second sound was accentuated, but there was no other evidence of cardiac mischief. The apex beat was diffuse and the general impulse readily felt, as is often the case in advanced phthisis. It was suspected that the cardiac murmur was not one of actual mitral regurgitation.

On *post-mortem examination* the lungs were found in a condition corresponding with the physical signs. The heart weighed 10½ oz., and all its cavities contained whipped-up fibrinous clots. Generally it seemed to be normal, but immediately below that flap of the aortic valve opposite which the left coronary artery is given off was a pouch in the inter-ventricular septum, as big as a split filbert, and which readily admitted the end of the middle finger. It projected into the right ventricle, and its walls were simply membranous and perfectly transparent—as transparent as a valvular flap. The floor of this pouch was irregular and thrown into net-like folds; its margin (on the left ventricular aspect) was smooth, firm and uniform, and showed no sign of any old inflammatory process, and to it the larger flap of the mitral valve was attached laterally, and the left segment of the aortic valve superiorly. On the side of the right ventricle the pouch could be seen through the auriculo-ventricular orifice, into which it projected, and one of the cusps of the tricuspid was intimately attached to it.

This aneurysmal sac was clearly the result of imperfect development of the ventricular septum, and a consequent increase in the size of the "undefended spot" (*pars membranosa*), which in this country has been particularly described by Dr. Peacock. A triangular membranous patch was found in the septum, and this had yielded so that an aneurysmal pouch projected into the right heart. Thus, this pouch was no doubt due to congenital conditions; the membranous wall had yielded in post-uterine life to the greater blood-pressure in the left ventricle, and besides this, one cusp of the tricuspid valve was attached (in its normal position) to the membranous part of the septum, and possibly had drawn upon it so as to favour aneurysmal protrusion into the right ventricle.

The exact attachment and connection of this cusp of the right auriculo-ventricular valve are interesting, for on more careful examination of the aneurysmal portion of the septum on the right side, it was made plain that the attachment of the valve crossed the middle of the protrusion, and divided it into two distinct parts. The membranous wall had yielded on each side of the attached valve, and thus the appearances agree with those given by Rokitansky, who figures a somewhat similar malformation ('Die Defecte der Scheidewände des Herzens').[1] It is worthy of note that most cases of

[1] Dr. Peacock was kind enough to examine my specimen at Charing Cross

deficiency in the septum have occurred towards its base—that is, in the part last developed during uterine life; and the case stands midway between those of completely imperfect development of the septum with communication between the ventricles at the base and the normal condition of the undefended space.

One other point is worthy of notice. The aorta was atheromatous, in the gelatinous stage, though the aortic valves were healthy in themselves. But the left segment attached to the margin of the sac was displaced downwards, so that the orifice of its coronary artery must have been uncovered in the systole of the ventricle. The segment was carried clear away from it, and it seemed likely that this was due to the gradual formation of the pouch and to the continual traction on it and through it on the aortic segment which the attached tricuspid valve had exerted. This "exposure" of the coronary artery is interesting because it is disputed whether this vessel is filled in systole or diastole. Last session I exhibited a specimen which favoured the view of those physiologists who hold the latter to be true. And here the coronary artery opposite the displaced valve, though no more involved by the atheromatous changes in the aorta than the right artery, was larger than natural and more irregular, suggesting thereby additional or unusual strain upon it. The orifice of the right vessel was almost natural and certainly neither large nor irregular in shape. The aortic flap of the mitral which was attached to the firm edge of the pouch was unusually well developed, so that no regurgitation could have occurred, and it is likely that the murmur heard during life was due to blood-eddies in the pouch with every systole. *February 19th*, 1878.

---

3. *Two cases of loose balls of fibrin in the left auricle, with mitral stenosis.*

By J. Wickham Legg, M.D.

George Joseph T—,a young man, aged 22, was brought dead to St. Bartholomew's Hospital at 8 o'clock in the morning of May 28th, 1877.

Hospital, and at once compared it with one figured in Rokitansky's book, and with another preserved in St. Thomas's Hospital Museum.

The body was examined twenty-eight hours after death.

There was no œdema of the legs or feet; the body was well nourished; the rigor mortis well marked; the face of rather a bluish tint.

Calvaria, dura mater, and sinuses, quite natural. The vessels at base of brain quite natural, but the artery to the Sylvian fissure and anterior cerebral are well filled by a jelly-like unadherent clot, which extends into the carotid. No other clots are found in the arteries of the brain. No embolus can be distinctly made out at the point of bifurcation, but the clot there does look somewhat different from the rest. The brain tissue everywhere quite natural.

The pharynx, gullet, larynx, and trachea, quite natural.

The left pleura obliterated; the adhesions of the base of the lung must be more than half an inch in thickness, and of cartilaginous hardness; the pleura is everywhere thickened, but not to so great an extent as at the base. At the level of the fifth interspace is a cyst in the pleura, which would hold a small orange, marked off by firm adhesions and containing a gelatinous fluid. The right pleura free from adhesions. The pericardium adherent outside to the left ribs; no adhesions internally, but the pericardium contains an excess of clear fluid. The heart very large and dilated in all four cavities; the right ventricle thickened and tough; no disease of the tricuspid or pulmonary valves. On opening the left auricle, which is greatly dilated, two balls of fibrin, clearly *ante-mortem* coagula, fall out of the auricle. They are grey and granular on their surface, and marked by lines resembling the impressions made by the waves on a sandy shore. Both are about the same size, that of a pullet's egg, and irregularly oval, about 50 mm. long by 30 broad. The auricular appendix holds a very firm, adherent, almost cartilaginous clot, which shows a broken-off end projecting into the auricle. It is quite possible that one of the balls may have been joined to this clot in the auricular appendage by a pedicle, as one of them shows a surface which closely corresponds to this broken-off end. The mitral orifice is a mere chink; it scarcely admits the tip of a man's forefinger. It is beset with granulations. Before the heart was opened water poured into the aorta ran rapidly through into the ventricle. The aortic valves are now seen to be grown together at their edges, shortened, thickened, and beset with fine granulations. The left ventricle is dilated and hypertrophied. It holds a few

loose pieces of fibrin, which look as if they had been torn off the balls in the left auricle.

Both lungs are highly œdematous and firm to the feel. The lower lobe of left lung very red, firm, and collapsed.

Spleen large, red, firm; Malpighian bodies very prominent; no infarcts.

Stomach and intestines quite natural. The liver large, firm, nutmeggy.

Kidneys of natural size; tissue very hard; capsule not adherent. On section the striation of the cortex is seem to be quite natural, but the Malpighian bodies are very prominent and red. The pyramids are dark purple.

Bladder natural. Aorta tolerably free from atheroma, but narrow.

This man was brought dead to the hospital by the police, so that nothing is known as to the manner of death. In all likelihood it was sudden and in the streets. The cause of sudden death is not far to seek. A loose thrombus in the left auricle would at any time be ready to act as a ball valve, and stop the circulation through the mitral orifice.[1] The only matter for surprise is that the balls attained so large a size before death took place. In the following case, the preparation of which was given to the Museum at St. Bartholomew's by Dr. Gee, the patient died slowly of the effects of her mitral stenosis; and in a like case, shown by Dr. John W. Ogle to our Society, death was also slow.

Jemima Adams S—, 43 years of age, admitted into St. Bartholomew's Hospital on July 3rd, 1861, died July 18th.

Examination after death.—No anasarca. Lungs extensively collapsed. Pericardium natural. Heart much enlarged, about equally so on both sides. Right ventricle much dilated and hypertrophied. Left ventricle somewhat dilated, not hypertrophied. Left auricle much dilated. Mitral orifice greatly contracted so as to admit not more than the tip of the little finger. In the left auricle there was a round ball, about an inch and a half in diameter, very elastic, very smooth, and without any trace of pedicle, that is, altogether free in the cavity. Other valves natural.

In the kidneys were several large embolic masses.

[1] Since the specimen was shown I have found that in one case at least this was a demonstrable cause of death; for Dr. Van der Byl describes, in a communication to our Society ('Trans.,' 1858, vol. ix, p. 89), a case of sudden death in which one of these balls of fibrin was found sticking in the narrowed mitral orifice.

The mode of origin of these balls of fibrin seems very easy of explanation. In the first place there must be a considerable amount of mitral stenosis. Then a clot forms in some part of the vascular system between the radicles of the pulmonary veins and the mitral orifice; in some cases, as in the first of these, a clot is found in the auricular appendix; or, perhaps, a pulmonary infarction has existed, leading to the formation of a secondary clot in the pulmonary veins. A part of this clot, too large to pass through the narrow mitral orifice, is broken off, and therefore remains in the left auricle, instead of passing into the general system of arteries, and causing infarctions of different organs, as in an unnarrowed mitral orifice might take place. Pent up in the left auricle the clot, at first of irregular shape, is generally overlaid with fresh layers of fibrin, and from the tendency to become round that bodies possess, the clot gradually assumes a spheroidal shape. This process is well seen in Dr. John W. Ogle's preparation in St. George's Hospital.[1] The ball there has been cut across and shows the nucleus to have been a clot, irregular in shape, with layers of fibrin arranged around it. *October* 16*th*, 1877.

---

4. *Large ante-mortem clot filling the left auricle, in a case of stenosis of the tricuspid and of the mitral valves.*

Exhibited by Wm. Ewart, M.B.

Thrombosis of the left auricle, assuming the proportions seen in this specimen, is, I believe, of rare occurrence and has seldom been described. It appears to have been mainly due, in this instance, to an unusual combination of valvular disease, to stenosis affecting the mitral orifice, and also the tricuspid.

The heart was removed from the body of Emma P—, æt. 37, who died in St. George's Hospital, whilst under Dr. Dickinson's care. The clinical history, for which I am indebted to Dr. Isambard

[1] For an account of this case, see the 'Transactions' of our Society for the year 1863, vol. xiv, p. 127. I am told there is a like specimen in the Museum of St. Thomas's Hospital.

Owen, is briefly this:—The patient had suffered from acute rheumatism at the age of twenty-one, and again five years later. The second attack was followed by chronic symptoms of heart disease, palpitations, shortness of breath, and œdema of the legs. She became rather worse in 1876, and she was admitted as in-patient in September of that year. The cough and hæmoptysis were considerably relieved by digitalis and tonics, but the improvement was very temporary. The symptoms returned in an aggravated form in February, 1877, and she was readmitted on April 16th, in a state of dyspnœa such as to forbid any clinical examination. During her first stay in the hospital enlargement of the heart had been recognised, and a distinct systolic murmur had been heard, coextensive with the cardiac dulness, but loudest at the apex. The same murmur was still present, but nothing further could be ascertained during her lifetime on account of the great distress of breathing, which was from the first accompanied by cyanosis. On the morning of May 19th, urgent dyspnœa set in, leading to profuse perspiration, to a high degree of cyanosis, and to absence of the radial pulse. No amendment took place in her condition, and she died on May 25th at noon, six days from the beginning of the worst symptoms. The general *post-mortem* appearances, as observed twenty-six and a half hours after death, were those of mitral disease, with rather less than the usual amount of œdema. The lungs were emphysematous and somewhat congested; the left lung contained a brown-coloured infarct; another, which occurred in the right lung, was smaller and more recent. Cicatrices found in the kidneys were also referred to old infarction.

The heart weighed 24 oz., including the contents of the left auricle. The distension of the right auricle was considerable from the presence of soft clots; similar clots filled the right ventricle, but the slightly hypertrophied left ventricle was empty. The tricuspid orifice was narrowed and reduced to a diameter of $\frac{7}{8}$ths of an inch; the mitral valve presented a higher degree of stenosis, measuring only $\frac{3}{8}$ths of an inch across.

Unlike its fellow, the left auricle was not much larger than normal. Before it was incised it was felt to contain solid material; the incision led to the escape of a few drops of thick pinkish-brown fluid containing grumous particles of fibrin. The section was not completed through the clot in the fresh state, but, as far as it was then carried, it disclosed an opaque buff-coloured fibrin, possessing the friability of breaking down rather than of newly formed deposit.

The auricular cavity appeared to be accurately filled by the fibrinous cast, which sent prolongations into the origins of all the pulmonary veins. The incision was subsequently extended to the very base of the auricle, and a small interval was in this situation discovered between the clot and the inter-auricular wall; another small vacant space existed just above the stenosed orifice; at most other parts the clot adhered to the auricular endocardium.

It was observed that the fibrin was dense and finely laminated at the periphery, forming a thin crust around the central structures, which were soft, spongy, and most irregular. In the neighbourhood of the orifices of the pulmonary veins the clot was faintly stained, and small lacunæ, more deeply blood stained, indicated clearly the last channels followed by the blood current before the ultimate sealing up of the veins.

That the clot was formed before death there can be little doubt; how long before death it is impossible to state with any degree of certainty; but from the clinical context we can infer that it did not attain its formidable development till the 19th of May. The dyspnœa which then set in and lasted till death is, I think, to be referred to the gradual invasion of the pulmonary veins, and, in accordance with this interpretation, I consider that the deposit began in the auricle, probably in its appendix, and was not the result of thrombosis descending from the lung.

October 16*th*, 1877.

---

5. *Aneurysms of the left ventricle of the heart.*

By J. Wickham Legg, M.D.

James T—, aged 38, was admitted into St. Bartholomew's Hospital, under the care of Dr. Black, on May 15th, 1877.

For the clinical notes I am indebted to Dr. Abercrombie, the house physician.

History.—For seventeen years was in the Royal Navy; left the service three years ago. Ailing for at least eight months, and losing flesh all that time. Shortness of breath was his first trouble. Cough and swelling of legs about fourteen days.

On admission.—Pallid; much emaciated. Chest, as to lungs,

natural. Heart: apex beat 1 inch outside nipple line, impulse heaving; dulness not extended to right or upward; no murmur. Liver readily palpable in abdomen; edge not felt. Spleen impalpable. Slight anasarca of legs and ankles.

May 17th.—Urine contains many hyaline and granular casts.

18th.—Feet cold, blue, and pit on pressure. Evening, very short of breath.

21st.—Difficulty of breathing greater, orthopnœa all night. Heart sounds natural, impulse heaving, well outside nipple line. Pulse extremely feeble.

22nd.—Extremities cold. Heart sounds natural. Pulse at wrist too feeble to be counted.

23rd.—Pulse at wrist too small to be counted. Sputa rusty.

24th.—Heart sounds natural. Pulse very feeble in both radials. Sputa more blood stained. Urine, sp. gr. 1012, no albumen. Death at three in the afternoon.

During life he denied that he had ever had syphilis.

Examination twenty-one hours after death.—Legs slightly œdematous; there is some scarring a little below the right groin, on the upper part of the thigh, but it does not look as if the disease had gone deeply. There is no scar on the penis.

The right pleura holds about two pints of a turbid fluid with shreds of lymph. The upper lobe of the lung is solid here and there, with emphysematous vesicles at the apex. The solid part is due to the presence of numberless discrete tubercles, thickly sown together, varying in size from a millet seed to a pin's head; in the lower part of the upper lobe is a small pulmonary infarction. The whole of the lower lobe is solid, plump, firm, sinking in water; on section it shows a red granular surface, from which an airless fluid can be scraped. The finger passes into the lung with readiness.

The upper lobe of the left lung is filled with discrete tubercles like the right; the rest of the lung is emphysematous; in the lower lobe is a large patch, the size of a man's fist, of red hepatisation; characters like that on the right side.

Pericardium much dilated. After being opened, heart weighs 15 oz.=420 grm. On the free surface of the heart, near the apex of the left ventricle, are two rounded bulgings, of a white colour, and covered with a plexus of vessels; these have a soft almost fluctuating feel; a like tumour may be felt along the line

that separates the auricle from the ventricle. The larger of the two bulgings is of the size of a walnut; of the smaller, that of a marble. All four chambers of the heart are dilated, but there are no valvular lesions; on opening the left ventricle there are seen two cavities in the wall corresponding to the bulgings seen without. These cavities are lined with old thrombi. Along the line of the attachment of the small flap of the mitral to the wall of the heart (felt outside) there is great thickening and whiteness of the endocardium; on cutting into this there is seen an irregular, white-yellow substance dispersed in islets amongst the muscular tissue. Just the same appearances are seen near the aneurysms.

The liver is highly nutmeggy. The spleen is small, tough, and wasted. The stomach natural. The small intestines hold two tapeworms. The sigmoid flexure shows excoriations of mucous membrane.

The kidneys show chronic congestion; weigh together 12 oz. = 360 grm.

Aorta not highly atheromatous.

Parts of the cardiac new growth were examined, after hardening in dilute chromic acid, about a month after death.

Towards the edges of the tumour the new growth was found separating the fibres of the heart; it was formed of a transparent matrix, in which a few large rounded nuclei were apparent; more towards the middle the nuclei were much more abundant, and the matrix, in which they were embedded was fibrous rather than transparent. In the very midst no definite structure could be distinctly made out, the section being highly granular, though a few ill-formed fibres could sometimes be seen.

A few years ago I described a tumour, having precisely the same characters under the microscope, as a syphilitic gumma of the heart.[1] In this, as in that, there was no other evidence of syphilis in the body; yet if the histological characters commonly given as those of gummata be trustworthy, there ought to be no doubt about either of the two cases. I must own that I now feel some hesitation in calling the present specimen a syphilitic gumma, without much wider evidence. *October* 16*th*, 1877.

[1] Wickham Legg, 'St. Bartholomew's Hospital Reports,' 1872, vol. viii, p. 183.

6. *Aneurysm of the right auricle.*

By J. Wickham Legg, M.D.

Caroline G—, aged 51, was admitted into St. Bartholomew's Hospital on December 28th, 1877, under the care of Dr. Black.

For the clinical notes I am indebted to Dr. Abercrombie.

History.—Subject to winter cough for many years, but much worse the last eight or nine weeks.

On admission.—Considerable orthopnœa; complexion dusky; lips livid; jugulars distended and cord-like. Slight left lateral curvature. Chest somewhat barrel-shaped, prominent angulus Ludovici. Cardiac dulness diminished; heart sounds natural. No dulness over chest; percussion note high pitched. Some moist sounds at both posterior bases, no adventitious sounds elsewhere; respiratory murmur everywhere feeble. Pulse 108, fair volume, regular; artery not tortuous. Legs and feet not swollen. Urine not albuminous. Coughs a good deal, sputa viscid, muco-purulent. Her dyspnœa gradually increased, and she died about a fortnight after admission.

Examination thirty-two hours after death.—Height 4 ft. 9 in. Plenty of fat under skin. Rigor mortis well marked. No œdema. The external jugular distended. Some coils of the small intestine much injected, almost red, on peritoneal surface.

The tongue, larynx, pharynx, and gullet, natural. The windpipe much injected.

The lungs meet in the middle line and the left overlaps the right. The right pleura holds about a pint of bloody fluid (? if not due to blood from neck running in). Left pleura obliterated throughout.

Pericardium natural; it holds about half an ounce of clear fluid. The right and left ventricles seem equally distended with blood. The right auricle, coronary sinus, veins of the heart, and inferior and superior venæ cavæ seem much distended and dilated. Right auricle holds fluid and clotted blood; so in pulmonary artery and pulmonary veins. Water poured into the aorta and pulmonary artery, after cutting the heart out, does not run through into the ventricles.

On opening the right auricle, the valve which guards the coronary sinus is found much developed. It shows several large threads and

even continuous membrane close to the wall. In the wall of the right auricle, at the back, close to the septum auriculorum and just above the line which separates the auricle from the ventricle, is a rounded, almost hemispherical projection, covered with pericardium. It is about the size of a large cherry, 20 mm. in longest diameter and 15 mm. in the shortest. The projecting surface is of a bluish colour and looks thin; the summit is covered by a whitish, shaggy-looking spot, not adherent to the opposite pericardium, and from this spot pass several white lines. The wall of this projection is only 2 or 3 mm. in thickness. Looking at the auricle from the inside an opening is seen, corresponding to the prejection, in a triangular space formed by two musculi pectinati and the smooth surface which comes between the attachment of the tricuspid valve. The larger opening is about 15 mm. in diameter, the deeper opening is not above 5 mm., and the whole of the projection beyond this deeper opening is filled with *ante-mortem* clot. The tricuspid orifice is much dilated; the valve itself is natural, save some thickening and opacity of the edges. The pulmonary valves are natural. The large flap of the mitral is thickened, so are the edges; the body of the flap shows several patches of atheroma. The aortic valves thickened but otherwise healthy. The muscular walls of the right ventricle are much thickened and toughened. There is some increase also in the thickness of the left ventricle. The greater number of the muscular fibres, taken from the right auricle, and the right and left ventricle show no fatty degeneration under the microscope. Weight 13 oz. = 365 grm.

The lungs are generally emphysematous; the vesicles are to be distinctly seen enlarged and opening into each other; at the back of the lower lobes there are patches, marked off apparently in relation with groups of vesicles, blue in colour and depressed below surface. This appearance is removed by blowing air into the lungs. Weight of right lung 20 oz. = 566 grm.; of left 17 oz. = 480 grm.

Spleen natural in size, firm; Malpighian bodies very indistinct; weight 5½ oz. = 155 grm.

Stomach and intestines show deep injection of mucous surface throughout. No ulceration.

Liver small; edge fibrous, tissue very firm, surface granular. On section shows a distinct nutmeg appearance. Weight 88½ oz. = 1100 grm.

Supra-renal capsules natural. Kidneys highly congested. Left

ovary, formed by a one-celled cyst, the size of a cocoa-nut, is adherent to sigmoid flexure and uterus. The right ovary natural. Uterus and bladder natural.

Two opinions as to the origin of this aneurysm may be held; one that it is a congenital malformation, and in the favour of this there is great development of the valve of Thebesius. I am myself inclined to another opinion. The aneurysm has been caused by the great inter-auricular pressure secondary to the tricuspid regurgitation, and has formed at a spot where there was least support to the wall from the *musculi pectinati.*

Aneurysms of the left auricle, though rare, are not unknown. I have been unable, however, to find any example of aneurysm of the right auricle on record, save the following case of Howitt's, about which some doubts may be entertained. In opening the body of a boy, eight years of age, the following appearances were noticed about the heart:—"The pericardium instantly attracted our attention as appearing very much distended, and on cutting into it there gushed out, as near as we could guess, a pint of grumous fluid and pus, containing a number of curdy flakes, the whole interior surface being lined with a layer of cheesy, scrofulous-looking matter, apparently soft coagulated lymph, one sixteenth of an inch in thickness. On examining the external surface of the heart more particularly, we discovered a rounded eminence, situated just at the junction of the right ventricle, and which was darker in colour than any other portion. Upon making a crucial incision into this prominence, there flowed out about a teaspoonful of ill-conditioned pus, with a few curdy flakes. This small abscess communicated internally by a small ragged opening, with the right auricle, which contained a mixture of pus and blood. There was no communication with the sac of the pericardium."[1] *February* 19*th*, 1878.

[1] Howitt, 'Lancet,' 1846, vol. i, p. 684.

7. *Mitral stenosis; thrombosis of left auricle; embolism of left inferior parietal lobule; thrombosis of femoral arteries. gangrene of lower extremities.*

By W. Cayley, M.D.

Mary F—, aged 52, a widow, was admitted into the Middlesex Hospital, under my care, on January 7th, 1878.

The patient appears never to have suffered from rheumatism, but for the last four years has had more or less bronchitis and shortness of breath, and has occasionally had œdema of the feet.

On January 6th, while sitting in her chair, she suddenly became unconscious, and was found by her friends with the tears running from her eyes and the saliva from her mouth. She remained unconscious for about three hours, and when she came to herself it was noticed that her speech was difficult and her mental faculties impaired; she was not, however, paralysed and was able to walk from one room to another.

State on admission.—A somewhat corpulent, plethoric-looking woman; speech slow and hesitating, as if from defective memory of words; mental faculties confused; no paralysis of the facial or ocular muscles or deviation of the tongue; grasping power of both hands equal, no impairment of sensation; the right foot is constantly being twitched outwards and the great toe drawn backwards; these movements are incessant. Both legs are livid from dilatation and congestion of the venous capillaries; the larger veins are also varicose. The apex of the heart beats in its normal position; the action is very irregular and the sounds rough, but there is no distinct murmur. Pulse, 88; temp. 99·4°. Urine free from albumen.

No material change took place in her condition till the 12th, the twitching of the foot continuing, and the speech remaining impaired. On the 12th she complained of loss of power in the right hand and there was now decided weakness of the grasp. About 12.15 p.m. she was suddenly seized with an acute pain, first in the right, then in the left leg, which she described as being like cramp, and for its relief she insisted on getting out of bed and letting her legs hang down; she became very faint and her breathing laboured. The legs soon became cold from the knees downwards and devoid of sensa-

tion, and it was found that the pulse in the tibial arteries was not perceptible; the pain extended into the lower part of the abdomen. Gangrene of both legs below the knees, with patches in the thighs, now showed itself, and she became very prostate. Albumen appeared in the urine, and she suffered much from dyspnœa, due, apparently, to exacerbation of her bronchitis. On January 20th she was attacked by erysipelas of the face, probably the result of contagion from another patient in the same ward, and she died on January 23rd.

Post-mortem examination.—The only morbid changes found in the cranium, with the exception of some opacity and œdema of the pia mater, were confined to the left inferior parietal lobule. Here, after stripping off the pia mater, two circumscribed patches of red softening were seen; the larger one, which was placed above, was oblong in shape and measured three quarters by half an inch, not involving the whole width of the gyrus and only extending through about half the thickness of the cortical layer; the other patch was seated about half an inch below, and was only about one third its size.

Careful search was made for other lesions, both in the cortex, the white matter, and the central ganglia, but in no other part of the brain could any be discovered. The arteries forming the circle of Willis were atheromatous.

The heart was enlarged, the left auricle much dilated and hypertrophied, and its lining membrane opaque. Depending into the chamber from the appendix was a firm fleshy, partly decolorised clot; it was firmly interlaced with the columnæ carneæ of the appendix, and its free extremity rested on the upper surface of the mitral valve. The cusps of the valve were thickened and calcified, and the mitral orifice much constricted and reduced to a slit-like aperture. The aortic valves were thickened and the aorta atheromatous.

The lungs were pigmented and emphysematous; they did not present any infarctions.

The right kidney was slightly granular on the surface; it presented a wedge-shaped patch, occupying both the cortex and medulla, of a pale greyish-white colour, and contrasting with the vascular, congested appearance of the rest of the organ; a partly decolorised clot was found to block the branch of the renal artery which led to this patch. The left kidney was puckered on the surface and somewhat granular.

The abdominal and iliac arteries were empty. The external iliac

vein on each side was filled with soft black clot. The femoral arteries on each side, commencing at the level of Poupart's ligament, were occupied by firm adherent coagula; above the origin of the profundæ the clots were less firm and adherent than below.

May 21*st*, 1878.

---

8. *A case of rupture of the aortic valves.*

By J. Burney Yeo, M.D.

This specimen is presented to the Society as the sequel of a case brought before the Clinical Society in May, 1874. The patient, at that time, was the subject of a very remarkable cardiac murmur, which had made its appearance under the following circumstances:—About three weeks before he came under my notice, he was coming down a flight of stone steps, when one of his legs suddenly "gave way," and he slid rapidly down eight or nine steps, clutching firmly as he fell at an iron railing, which did not save him, for he fell violently on his back at the bottom of the flight.

Soon after this accident, to which he paid no attention at the time, he began to hear a curious, loud "singing" noise in his chest; it was very troublesome to him at night, and he could not sleep for it. It was this that induced him to apply as an out-patient to the Brompton Hospital.

He was a fresh, healthy-looking, muscular man, of regular and temperate habits, a widower, forty-eight years of age; he had never been laid up with any illness, but he had had a winter cough for fifteen years, and had been much troubled with rheumatic pains in the limbs. He was a railway clerk.

On ausculation a loud, deep-toned, musical murmur could be heard all over the chest. It was the loudest cardiac murmur I had ever heard. It was distinctly audible, in a quiet room, at a distance of three feet from the patient. It is needless to say that it could be heard distinctly all over his body.

Its point of maximum intensity was at the base over the second right costal cartilage; it was chiefly diastolic in rhythm.

Pulse 80, collapsing.

There were already signs of considerable cardiac hypertrophy, which increased rapidly.

He had not suffered from pain in the chest, nor from faintness, nor from any great amount of dyspnœa. I draw attention to this because one or other of these symptoms, generally all three, have been observed in most of the cases of traumatic lesion of the aortic valves on record. I was nevertheless induced to believe that this was a case of rupture of the aortic valves.

It was difficult, in any other way, to account for the sudden appearance of an intensely loud cardiac murmur of a decidedly musical character, without any indications of pre-existing cardiac disease, and following immediately on a severe fall.

The patient continued to follow his occupation and remained for a considerable period in very fair health, attending the hospital, from time to time, as an out-patient.

After a few weeks the murmur began to diminish in intensity and to lose, more and more, its musical tone. On one occasion, two or three months after the accident, scarcely any bruit could be detected, and when he next appeared, after about another month, it had entirely altered in character, and now resembled an ordinary double aortic murmur of rather harsh quality.

This patient continued well enough to follow his occupation till January of last year, when, after an absence of several months, he again appeared at King's College Hospital, obviously very much worse; he had become very pale and thin, his hair had turned grey, he was suffering much from cough and dyspnœa, and giddiness. He also complained of great muscular feebleness with symptoms of ataxia. His gait was unsteady, and he had to use a stick, or would stretch out his hand to steady himself against the wall, &c., in walking. He had suffered much from pains shooting upwards from the heels to the thighs. He often felt a numbness in his feet, and was uncertain when they came in contact with the ground. He had also some loss of power over the bladder, and had great difficulty at times in retaining his urine.

He was induced to leave off work and come into the hospital, and there, with complete rest in bed and tonic remedies, he mended very considerably, and after three weeks returned home by his own wish.

He came a few times, at rather long intervals, as an out-patient, but objected to come into the hospital, notwithstanding that his

ataxic condition was becoming aggravated, and failure of the circulation very evident.

On the 20th of last November he got up and dressed for the purpose of coming to the hospital to ask to be readmitted, when he fell down dead by his bedside, rather more than three years and a half after the accident.

Mr. Barrow, our pathological registrar, was good enough to proceed to the patient's residence, and induced them to consent to a *post-mortem* examination, but of the chest only.

The heart is before you. It is enormously hypertrophied. The aorta is the seat of extensive atheromatous disease. The valves present an interesting appearance. The right anterior and the posterior segments have been torn down at their contiguous attachments to the aorta, so that they are separated from the wall of the aorta to some extent, and attached at a lower level than the other contiguous segmental attachments.

It must be remembered that this happened between three and four years ago, and the detached portions of the valve have no doubt shrunk much during this period and become altered in form.

It is probable that when the accident happened originally, the ends of the valves, thus separated from their attachments, vibrated freely and rapidly in the regurgitant current of blood which they permitted. Later on, as the detached portions of the valve contracted and dwindled, the vibrating tongues disappeared to a great extent and became thicker or less capable of rapid vibration; thus we had simply an imcompetent valve attended by the usual murmurs.

In a summary of most of the recorded cases of rupture of the aortic valves which I gave in the 'Lancet,' October 5th, 1874, none appear to have lived so long after the accident as this patient.

It has been maintained that a loud musical murmur, such as was observed in this case, is not caused by the vibration of any portion of the injured valve, but is due to the fact that the support of one of the valves being suddenly removed from the other two the free edges of the latter are thrown into rapid and regular vibrations by the regurgitant column of blood. It seems to me that that could scarcely have been the case here.

From the amount of disease present in the aorta I should think it very likely that the valves were themselves not entirely free from disease at the time of the accident.

February 5th, 1878.

9. *Obliteration of the aorta; dissecting aneurysm; two semilunar aortic valves.*

By J. Wickham Legg, M.D.

John L—, aged 20, was brought dead to St. Bartholomew's Hospital on the morning of May 28th, 1877, having been picked up in the streets by the police. Nothing further was known about him.

Examination twenty-six hours after death.—Body well nourished and muscular; rigor mortis persistent; no external marks of disease.

Calvaria is very thick. Dura mater, sinuses, and brain itself, quite natural. The arteries of brain free from atheroma.

The pharynx, gullet, larynx, and trachea, natural.

On taking away the sternum it is at once noticed that the right internal mammary vein is blocked by a thrombus for about an inch, that both veins and arteries are much larger than is common, the right internal mammary artery being about the size of a goose-quill, the left somewhat smaller. The thymus gland is persistent and covers the anterior mediastinum and part of the pericardium. There is a large hæmorrhage under the pleura covering the mediastinum on the right, which passes down to the root of the lung. Upwards this extravasation extends in the sheath of the right carotid, as far as the division into internal and external, and follows the subclavian artery. The carotid and subclavians on the right side are very large. There is no extravasation of blood into the sheaths of the arteries on the left side. All these arteries are highly atheromatous.

The pericardium is distended, and its contents can be seen to be of a black colour. On opening it large clots of blood and bloody fluid can be taken away; searching for a cause for this hæmorrhage a rent is found in the outer sheath of the aorta within the pericardium, vertical in direction, and about 42 mm. in length. It leads into an irregular cavity, containing clots, and thence into the sheaths of the innominate and right subclavian and carotid. At the bottom of the rent is seen the dilated and rolled-up elastic coat of the aorta.

The pleuræ are natural and free from adhesions.

The heart is small. On opening the right side nothing is

found worthy of notice. The left side is indeed contracted, and there is considerable concentric hypertrophy of the left ventricle. The large flap of the mitral valve shows a few spots of atheroma. The sigmoid valves of the aorta are only two in number. Immediately above the sigmoids the aorta is greatly dilated, measuring 100 mm. across About 30 mm. above the sigmoids is a transverse slit in the inner coat, leading into the cavity between the outer and middle coats before mentioned. This transverse rent is about 50 mm. long. The aorta, immediately below the origin of the innominate, is 47 mm. broad.

The whole of the arch of the aorta is atheromatous, and the branches which it gives off are four in number, the two first being the innominate and the left carotid; the third a ramifying artery to the neck, and the last, arising almost from the point of constriction, is the left subclavian. All these arteries are dilated and atheromatous. The aorta is completely constricted at the point of the insertion of the ductus arteriosus, and before reaching this point the aorta becomes distinctly conical. The obliterated part of the vessel is about 5 mm. in length. Below the obliterated spot the aorta is at first conical, but again quickly resumes its natural diameter. Three or four pairs of large intercostals here open into it. Just below the constriction the width of the aorta is 50 mm.; as it passes through the diaphragm 42 mm. The descending part of the aorta is only slightly atheromatous, not at all to the degree seen in the arch or carotids. The ductus arteriosus is in the usual ligamentous state; a fine bristle can, however, be passed into it from the aorta for a line or two.

The lungs contain no appearance worthy of note.

The spleen, stomach and intestines, liver and kidneys, perfectly natural. The bladder perfectly natural.

This is a very typical instance of a rare disorder. Narrowing of the aorta was first noticed, towards the end of the last century, by a French observer, Paris, in a body injected for dissection.[1] Several other cases have also been seen in bodies prepared in this way. During this century numerous other cases have been written about, so that in 1871 Eppinger set the number known at 60.[2] But I think this estimate somewhat too low, for even if allowance be made for the cases which Eppinger quotes twice over in his table, yet over and

[1] Paris, 'Journal de Chirurgie,' par Desault, 1791, t. ii, p. 107.

[2] Eppinger, 'Prag. Vierteljahrsschrift,' 1871, Bd. cxii, p. 35.

above these there are more, with which he apparently was not acquainted. Of complete obliteration there are very much fewer cases known. The last case published, very like the present, was printed last year by Lüttich.[1] A railway servant, aged 26, died suddenly while about his work. There were found a dissecting aneurysm of the aorta, which had ruptured into the pericardium, marked atheroma of the arch and its branches, and complete obliteration of the aorta at the insertion of the ductus arteriosus. This last vessel was a ligamentous band, 150 mm. long.

The opinions which have been expressed with regard to the nature of the narrowing or obliteration of the aorta fall with the greatest readiness into two heads. One set of views makes the constriction to be due to the involution of the ductus arteriosus; the other to some congenital vice of the aortic arches in the early weeks of fœtal life.

The first theory receives great support from the fact that the narrowing of the aorta is always found in the neighbourhood of the insertion of the ductus arteriosus. This would certainly seem to point to the ductus arteriosus as being in some way concerned as a cause of the narrowing. And further, Bochdalek, examining a child 22 days old, found a thrombus in the ductus arteriosus spreading into the aorta.[2] Rauchfuss objects to this as a cause of aortic stenosis, for he says he has examined two similar cases, and that where a thrombus extends from the ductus arteriosus into the aorta there, death rapidly follows.[3] Virchow, as might be looked for, approves of Bochdalek's theory, for it adds another instance of the importance of thrombosis apart from inflammation.[4]

Rokitansky's utterance on this subject is somewhat hesitating. He says there can be no doubt that this change consists in the persistence of a fœtal state, in which also the involution of the ductus arteriosus must be taken into consideration.[5]

[1] Lüttich, 'Arch. d. Heilkunde,' 1876, p. 70. Cf. Jordan, 'North of England Med, and Surg. Journal,' London, 1830, p. 101; and Graham, 'Med.-Chir. Trans.,' 1814, vol. v, p. 287. Dr. Norman Moore has published two cases of narrowing of the aorta in the last two volumes of St. Bartholomew's Hospital Reports' (1875, vol. xi, p. 225, and 1876, vol. xii, p. 101).

[2] Bochdalek, 'Prager Vierteljahrsschrift,' 1845, 2ter Jahrg., Bd. viii, p. 160.

[3] Rauchfuss, 'Arch. f. path. Anat.,' 1860, Bd. xviii, p. 544.

[4] Virchow, 'Gesam. Abh.,' p. 416.

[5] Rokitansky, 'Ueber einige der wichtigsten Krankheiten d. Arterien,' Wien, 1852, p. 37.

The other theory rejects the view that the narrowing is due to the ductus arteriosus, because in some cases the ductus arteriosus has been found open, or the aortic insertion patent. It is also asserted that the ductus arteriosus is closed, not by the formation of a thrombus, but by a contraction of the vessel upon itself.

Dr. Peacock has pointed out the presence of congenital malformations, hare-lip, fissured palate, and also important defects in the heart, such as imperfect development of the papillary muscles, aneurysm of the septum ventriculorum, and the absence of the complete number of the aortic valves. This last deformity seems to be out of all proportion to the number of cases, and it was present in the case just described, together with a fourth branch from the arch of the aorta and a persistent thymus. From these deformities Dr. Peacock argues that there is probably some congenital vice of the aortic branches very early in fœtal life.[1] This may seem to some plausible when it is considered that several of these aortic arches do become obliterated in early life, and that there may be a possibility that this process of obliteration, if begun in the aorta, might lead to the deformity described. I must own that I am myself inclined to favour the view that the narrowing or obliteration is due to the changes which take place after birth in the ductus arteriosus, a view which could be destroyed by finding constriction of the aorta in an unborn fœtus. *October 16th*, 1877.

---

10. *Case of aneurysm of the arch of the aorta which opened externally.*

By Thos. B. Peacock, M.D.

W. A—, æt. 46, a porter to a wholesale grocer, was sent up to London by Dr. Adey, of Hastings, and was admitted into St. Thomas's Hospital on December 4th, 1871. He then had

[1] Peacock, 'British and Foreign Medico-Chirurgical Review,' 1860, vol. xxv, p. 487.

a pulsating tumour in the front of the chest, immediately on the left side of the upper part of the sternum, which he said had existed for seven months, and which he ascribed to having been strained while at work. He was directed to be confined to bed, was allowed a fair proportion of nutritious food and some wine, and took the tincture of perchloride of iron.

Under this treatment the pulsation in the tumour diminished, the tumour became smaller, and after a time so nearly disappeared that it could only be felt as a small knot in the second inter-cartilaginous space immediately to the left of the sternum. When, however, he used any exertion or became at all excited, the tumour reappeared, and resumed almost its former dimensions. He was retained in the hospital till August, 1874, and was then removed to the Victoria Park Hospital, where he remained for six weeks, and during that time had the ice bag applied to the tumour. After this he was admitted into Guy's Hospital, and on January 24th, 1876, he was readmitted into St. Thomas's.

He was then found to have very much altered for the worse since his discharge. The tumour had greatly increased in size and lay more immediately in front of the upper part of the sternum. It had a biloculate form, being divided across by a very distinct furrow. There was some pain in the chest, and especially between the shoulders, and passing from the præcordia to the back, and especially to the left shoulder, and he was very much weaker than when he left the hospital. The integuments over the tumour had become excessively thin. On the 4th of August patches of livid redness made their appearance on the skin over the most prominent part of the tumour, and soon after these places became excoriated.

The surface was dressed with spermaceti ointment on lint, and the whole was then strapped with soap plaster spread on wash-leather. On the 4th of October a small opening, about the size of a split pea, had formed at the most prominent part of the tumour, and there was a slight oozing of bloody serum from it. From this time the opening increased in size, and a second smaller one formed above it, and from both apertures there was occasional bleeding, but never to any considerable amount. The blood was fluid and sometimes escaped in jets, but the larger opening was partially closed by clot.

He died exhausted on the 17th of October.

The aneurysm was found to occupy the ascending and transverse

portions of the aorta, from about an inch above the valves to the point where the left subclavian artery was given off, at which place the dilatation ceased abruptly.

From this part of the sac, which involved the whole circumference of the vessel, the tumour projected upwards, and by its pressure had led to the absorption of a large portion of the manubrium of the sternum and of the sternal end of the left clavicle, and of the first rib, and from this sac a portion projected in front of the sternum which had separated the muscles and integuments from the bone and the ribs. The upper part of the first or original sac contained much laminated coagulum, but the sac in front of the sternum contained only fluid blood. The latter had no distinct lining membrane, and was bounded only by the adjacent parts, and in front was only covered by the skin, which was extremely thin. The external opening was about three quarters of an inch in diameter, and was situated immediately over the middle of the sternum, and slightly above the level of the nipple. The second opening, which had existed during life, had contracted so that it could scarcely be seen. The aortic valves, though thickened, were quite competent, and the aorta beyond the seat of the aneurysm did not present material appearances of disease.

There can be no doubt that aneurysms of the aorta very rarely open externally. I have seen a considerable number of cases in which aortic aneurysms have formed circumscribed pulsating tumours, and though in some of them the integument over the tumours became very thin, this is the only instance which I have myself met with in which such a tumour has opened externally. In ninety-eight cases of aneurysm of the ascending portion of the arch collected by Dr. Crisp, six only opened externally, and of forty-eight cases of aneurysm of the transverse portions, one only opened externally. I find that in the first twenty-five volumes of our 'Transactions' there are about ninety cases of aneurysm of different portions of the thoracic aorta, more or less completely described, and of these seven formed circumscribed tumours on the front of the chest, and of these seven two only opened externally. There is also only one specimen exhibiting this mode of termination in the Collection of Morbid Anatomy at St. Thomas's Hospital.

It is generally stated that when aneurysms do form external openings, the opening is produced by the sloughing of the integument. In the present instance it would appear that the opening was

produced by ulceration commencing on the surface, and extending deeper till it reached the cavity of the aneurysm. It is impossible to speak positively on this point, for the bleeding which occurred immediately the tumour was exposed, precluded the possibility of a deliberate examination, but no appearance of slough was ever seen.

In the two cases of aneurysm opening externally, reported in the 'Pathological Transactions,' in one (that described by Dr. MacIntyre in the first volume, page 76) the aneurysm arose from the arch, and formed a tumour on the right side of the upper part of the sternum, which was in existence for about a year when the integument over the tumour sloughed. The separation of the slough was followed by bleeding. In the other case (also in the first volume, page 235, described by Dr. Barnes) the tumour was situated immediately on the left side of the sternum, low down, and had existed about a year, when ulceration appeared at several different points, then coalesced and formed a large opening, from which portions of clot escaped. The escape of the clot was followed by profuse and fatal hæmorrhage.

I exhibited to the Society in 1878 a specimen in which there was an enormous aneurysm, which arose from the descending aorta and produced very marked general protrusion of the walls of the chest in the left dorsal region, and, some time before death, livid patches formed on the skin. These became excoriated, and the integuments would doubtless have been eroded, so as to lay open the sac, had the life of the patient been prolonged for a very short time.

The present case is very interesting from the long duration of the patient's life after the appearance of the external tumour. The prolongation of life was apparently simply due to the rigid observance of rest and quiet, with a fair allowance of nutritious food, so as to maintain the patient in a good state of health. The object to be aimed at in such cases is to promote the deposit of fibrine in the aneurysmal sac, and this seems more likely to be accomplished if his strength be kept up and his heart be kept quiet than by any reducing measures, such as bleeding or a very restricted diet. I was led to adopt this method of treatment by some remarks made by Dr. Stokes in his work on the 'Diseases of the Heart and Aorta,' and I have followed it in several cases with satisfactory results. In the present instance the disease was almost entirely stationary for a very considerable period, and had any specific

treatment been had recourse to, the case would almost certainly have been regarded as affording decided proof of the usefulness of the treatment adopted. *November 6th*, 1877.

---

11. *Aneurysm of the aorta bursting into the pericardium; popliteal aneurysm cured four months previously.*

By W. W. Wagstaffe.

A year ago I had the opportunity of treating a case of popliteal aneurysm by a plan which seems to have been adopted only once before—the plan being that of depriving of its blood all the limb, except the aneurysm itself, for the space of one hour, by means of Esmarch's bandage. For a time a tourniquet was kept on the femoral artery, but at the end of another hour no pulsation was found in the tumour, and after continuing the pressure of the tourniquet five hours more a limited flow was allowed for a few hours longer. In about twenty-four hours all compression was removed and the man went out well in the course of a fortnight.

The case is reported in full in the 'Lancet' of September 30th, 1876.

I have now the opportunity of showing the aneurysm and part of the heart, owing to the patient having died suddenly on January the 13th, from the bursting of another small aneurysm of the aorta into the pericardium.

Since the time of his being treated for the aneurysm, on September 2nd, he had been home and had been in fairly good health, but was not very strong. About November he had sciatica of the right hip, but no connection with the aneurysm could be traced, and he shortly got well. On January 13th, 1877, while walking from the tram-car at Clapham late at night, he fell just after passing a stranger, who turned round on hearing the patient's umbrella fall. The stranger saw him falling on his face, where he lay without speaking; but he gave about two short coughs and was almost instantly dead.

DESCRIPTION OF PLATE IV.

The figures in this plate illustrate Mr. Wagstaffe's case of Aneurysm of the Aorta bursting into the Pericardium and cured Popliteal Aneurysm. (Page 72.)

FIG. 1 shows the external surface of the aorta at its root just above the right ventricle presenting a small aneurysmal bulging the summit of which is perforated by a pin-hole like aperture.

FIG. 2 shows the aorta laid open presenting mottling and puckering of its inner surface from atheroma and a perforation above the junction of the anterior and right semilunar valves which communicated with the bulging shown in Fig. 1.

FIG. 3 shows the popliteal aneurysm from the same case cured four months previously.

Fig. 1.

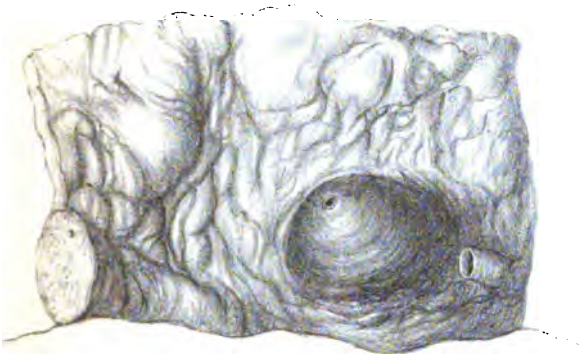

Fig. 3.

Fig. 2.

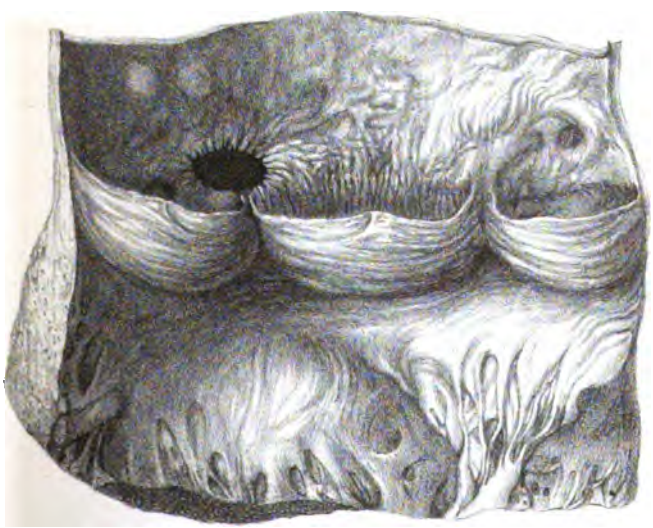

E. Burgess del et lith.

W. West & Co. imp.

During the previous few weeks he had been at St. Thomas's and seen me, had not complained then, or to his family, of anything the matter with his chest, and seemed fairly well. The aneurysm seemed quite solidified.

The *post-mortem* was made on January 16th, by Mr. Spitta, Dr. Spitta, Dr. Locke, and myself. The aneurysm was carefully dissected out by Mr. Spitta, and is now in the Museum of St. Thomas's Hospital.

On examining the chest we found the lungs and pleuræ healthy, but the pericardium was evidently distended, and upon opening it there appeared an enormous collection of straw-coloured serum, which, however, proved to be only the upper stratum of a hæmorrhage, for the lowest parts were solid clot. The amount of serum and clot together was nearly a pint, rather more than half being fluid serum.

At first no rupture could be found, and it was only after much care that a small pin-hole perforation was discovered at the root of the aorta just above the right ventricle. This pin-hole was at the top of a small bulging knob, which projected on the right side, about the size of half a filbert (Plate IV, Fig. 1).

Upon opening the heart it was found empty of blood, the walls of the left ventricle especially thickened, and both cavities dilated, but there was no disease of the valves. The aorta, however, presented a peculiar appearance (Fig. 2). It was mottled with patches of vivid red discoloration, was puckered and uneven, owing to the presence of soft atheromatous thickening and to a process of degenerative ulceration, which in one place had gone deeply enough to perforate the wall. These changes were peculiarly limited to the root of the aorta. The perforation was situated just above the junction of the anterior and right semilunar valves, and was about half an inch in diameter. It led into the little thimble-like aneurysm which was noticed outside, and from which the hæmorrhage had taken place.

Other vessels were examined, but were not found diseased. The pulmonary arteries contained no emboli. The kidneys and other organs were healthy.

The popliteal aneurysm (Plate IV, Fig. 3) was completely filled with old clot, decolorised in the greater part of its extent. Its length was two inches and its width one inch, and, as shown in the sketch, the plugging extended to within a short distance of a large branch both

above and below. The outer parts of the clot were evidently organized, and it seemed that only the portion shaded darkly in the sketch (about one inch by half an inch) was not perfectly organized. The artery had apparently given way on the outer side, and upon careful examination the coats of the vessel could be traced over the aneurysm with varying uniformity. The middle coat could be distinctly seen above and below, and it seemed that the blood had burst through it on the outer side, for some indication of a continuity of the middle coat could be traced throughout along the inner side, though the outer coat had been much thickened here as well as on the other aspect of the aneurysm.

When examined microscopically, the outer area was seen to be composed of well-marked fibroid tissue, the meshes of which were occupied by vessels and scattered blood-discs. The central portion consisted of blood-corpucles and numerous other corpuscles of about the same size, which stained readily with logwood. This area was limited, but not very accurately, by a wavy line, which was probably the remains of the elastic layer of the inner coat. Between these two areas the tissue shaded off into the well-marked fibrous tissue of the exterior.

The interest of this case is twofold, since, as regards the popliteal aneurysm, it is the first specimen obtained of one which has been treated by the plan adopted in this case, while the perforation of the aorta into the pericardium is sufficiently rare to make it worthy of record.

It will be seen that the popliteal aneurysm has solidified in mass, and that there is no evidence of lamination. The solidification, which is of rather more than four months' standing, seems to have been considerable and fairly uniform. I have appended a sketch of its appearance on section, for I find any representation of a cured popliteal aneurysm is very difficult to lay hands upon.

Cases of aortic aneurysm bursting into the pericardium have been recorded in the 'Pathological Transactions' occasionally, but Dr. Peacock has referred most fully to them in vols. xiv and xix. I take the opportunity of adding twenty-five from the records of the New York Pathological Society, with special reference to the suddenness of death and the size of the rupture, since, in the present case I have described, the rupture was extremely small and the death extremely sudden. In the cases tabulated below from the New York Society the position of the aneurysm is not at all accurately

stated, but seems to have been usually just above the semilunar valves. The aorta, near its root, is certainly less elastic and yielding than elsewhere, and it may be assumed that the distension of this part may, under circumstances of tissue weakness, both induce the degenerative changes found here frequently, and also, when the coats are softened, tend to rupture them more or less, completely. Moreover, the fibrous coat of the aorta is at its root considerably attenuated. There is no loose cellular coat to thicken, but its place is taken by a comparatively thin extension from the pericardium, fibrous and elastic. It is, therefore, not surprising that the first part of the aorta is the seat of dilatation or rupture.

The size of the rent in the wall of the aneurysm was in my case peculiarly small, nothing more than a large pin-hole, and yet the patient seems almost to have dropped down dead. In Dr. Irvine's cases (recorded in vol. xxviii) the rent was, I believe, much larger, and the death almost equally sudden. I find the size of the rent mentioned in ten of the cases recorded in the 'New York Pathological Transactions,' and in two of them it measured one inch transversely, two were half an inch long, while the rest are referred to as having been "small," a "mere slit," "exceedingly small," and "the size of a pin's head." But in nearly all the deaths appear to have been sudden.

It is not difficult to understand that death should be almost instantaneous when the laceration was half an inch to an inch long, but it is somewhat curious that, with so small an opening as exists in the specimen I have shown, death should have been so rapid.

It is, perhaps, of less interest to note that hardly any of the cases were diagnosed beforehand, but it seems of some importance in a medico-legal point of view that almost instantaneous death has followed bursting of aneurysms of the first part of the aorta into the pericardium in so many cases.

Abstract of 25 cases of Aneurysm bursting into the Pericardium, recorded in the 'New York Pathological Transactions.'

No.	Age.	Sex.	Description of Aneurysm and size of Rupture.	Mode of Death.
1	Æt. 26.	F.	Aneurysm from under side of arch opposite innominate, size of goose's egg; rupture 1 inch long into pericardium.	Death sudden.
2	„ 40.	„	Dissecting aneurysm; rupture longitudinal.	
3	„ 50.	M.	Just under pericardium; size of perforation not given.	Died coughing.
4	„ 45.	F.	Size of aneurysm and rupture not given.	Death sudden.
5	...	M.	Aneurysm just above aortic valves; size of rupture not given.	„ „
6	...	„	Aneurysm 1½ inch above valves; rupture ¼ inch internally, ½ inch externally.	„ rather sudden; ill occasionally with heart dyspnœa.
7	„ 45.	„	Aneurysm just above valves; two perforations, one into pericardium, atheroma.	Death instant.
8	„ 27.	„	Aneurysm just above valves; size of walnut; atheroma; burst into pericardium.	Died in chair suddenly.
9	...	...	Aneurysm just above valves; perforation, size of pin's head, into pericardium.	Death sudden while being pushed out of room.
10	...	...	Aneurysm large, involving branches and obliterating; burst near heart; 20 oz. in pericardium.	Death 16 hours.
11	„ 69.	M.	Aorta atheromatous; no aneurysm mentioned; ruptured 1 inch transversely; ill 4 years, with occasional fainting and dyspnœa.	Fainted.
12	„ 25.	„	Aneurysm, size of walnut, just above coronary artery; perforation so small as mere slit; atheroma and 2nd small aneurysm above.	Death sudden; found dead in bed, but went to bed early.
13	„ 25.	„	Aneurysm behind aorta, size of hickory nut; another aneurysm nearly burst; 27 oz. in pericardium.	Death sudden; fell back dead at supper.
14	„ 35.	„	Aneurysm behind aortic valve, size half hen's egg; perforation small; 1 pint of blood in pericardium.	Death sudden; pains in abdomen and back previously.
15	„ 70.	F.	Aorta atheromatous; no aneurysm mentioned; rupture just above valves for two thirds circumference of aorta.	Death after symptoms of nausea (?), 12 hours.

No.	Age.	Sex.	Description of Aneurysm and size of Rupture.	Mode of Death.
16	Æt. 40.	M.	Aorta with old dissecting scar; no aneurysm mentioned; rupture 1 inch above valves, through inner coat, and burst through outer 3 inches higher; plugging of innominate by this flap of inner.	Death in a few hours after fainting.
17	„ 45.	„	Aorta atheromatous; no aneurysm; rupture just above valves transversely; tear through pericardium into pleura large; pleura filled with blood.	Found dead (bruised).
18	„ 45.	„	Aorta atheromatous, rupture ½ inch, right posterior.	Death sudden; dropped dead at dinner.
19	„ 27.	„	Aneurysm near valves posteriorly, very small; perforation small; heart empty.	Death sudden; epileptic 1½ year.
20	„ 46.	„	Three aneurysms just above valves, ready to burst; one 2 inches further, with clots in it; one still further, burst.	Found dead in bed.
21	„ 55.	„	Aneurysm first part, ruptured into pericardium.	Ill 2 months; died gradually.
22	„ 45.	„	Aorta, chronic endoarteritis; perforation ½ inch right and posterior surface.	Death sudden, while eating dinner.
23	„ 30.	„	Aneurysm 1½ inch above root, size 5 × 3 inches, orifice 1 inch; perforation within pericardium.	Death sudden.
24	„ 21.	„	Aneurysm, perforation exceedingly small.	Death sudden, while stooping to tie shoes.
25	„ 50.	„	Aneurysm, large aperture.	Found dead.

November 6th, 1877.

12. *Old spinal disease, with amyloid viscera; distortion of the aorta from spinal curvature, with dilatation of the heart and ante-mortem coagula in the left ventricle.*

By James F. Goodhart, M.D.

The patient was a girl, æt. 7, under the care of Mr. Durham. Three years before her admission she had fallen off a form, and soon afterwards her back was noticed to be curved. Five months before her death the curvature became more prominent, and a large abscess formed near her hip. She was admitted in a very bad condition, and the abscess was opened with antiseptic precautions. Subsequently a Sayre's splint was applied. The temperature always continued high and another abscess formed. To open this, chloroform was given. Hardly a drachm had been administered when she suddenly died, as if from syncope.

At the *post-mortem* the heart was at once noticed to have a peculiarly globular shape, as if it were distended, particularly the left ventricle. On opening the latter more than half its cavity was found filled by an *ante-mortem* coagulum, the ventricle dilated, and its wall thin. The coagulum extended upwards from the apex, considerably beyond the free edge of the mitral. The upper part was somewhat gelatinous and recent, the lower old, chocolate-coloured, and softened. The aorta was caught in an angular curvature, and curiously distorted, and it was impossible to slit it up by running the scissor blade inside, because of the infolding of its coats. The spinal curvature was most pronounced opposite the twelfth dorsal, and at this level the aorta from the outside appeared to be dilated. From inside, this pouch was bounded below by a partial septum from the posterior wall of the aorta, and below this came another small pouch, and then another septum of larger size, and below this the renal arteries. The septa appeared to be produced by the pinching up of a length of the aorta by a certain loss of substance in the spinal column, and the aorta had consequently become infolded.

The spleen, liver, and kidneys were moderately lardaceous.

The point of interest in the case is the association of the dilated left ventricle with the distortion of the aorta. Dr. Hilton Fagge has put on record a case of angular curvature of the spine associ-

ated with ulceration of the aortic valves, in which he considered, failing other sources of inflammation, that the increased strain, which must have followed upon the extreme angular curvature and the consequent acute flexion of the aorta, had induced the endocarditis ('Guy's Hospital Reports,' vol. xix, p. 198). It seems probable that a similar cause may be invoked here to explain the dilated ventricle, though the coexistence of renal disease to a certain extent weakens the force which the coexistence of distortion of the aorta and dilatation of the heart would otherwise have had.

March 5th, 1878.

---

13. *Aneurysm of abdominal aorta; rupture and formation of a traumatic aneurysm (left kidney and left renal vein compressed by the latter; albuminuria).*

By J. Pearson Irvine, M.D.

The patient from whose body the specimen was taken was a man forty-two years of age, who came under the care of Dr. Silver in Charing Cross Hospital, on November 24th, 1876. He had served in the army twenty years, and since his discharge had acted as a commissionaire, and had no history of disease dating further back than about six weeks before his admission, at which time he took charge of a house during its redecoration. The smell of the paint seemed to affect him exceedingly, and he soon began to suffer from pains in the abdomen, but above all from pains in the head, with dsypeptic symptoms and constipation. Because of these things he came to the hospital. He had never had syphilis, and had received, as far as he knew, no blow on the abdomen.

He was under my care (in the absence of my friend, Dr. Silver) during the greater part of his stay in hospital. On admission he had a doubtful blue line along the gums, his abdomen was distended with flatus, and his general symptoms and history had led to the belief that he was simply the subject of lead poisoning. But he had from the first decided signs of abdominal aneurysm. There was a distinct bulging of the left epigastrium, extending to the hepatic

region, and towards the margin of the ribs on the left side, in such a way that there was a continuous plane surface from the full epigastrium into the cardiac area. There was a marked visible systolic pulsation in the whole epigastrium, easily separable from the cardiac impulse. A smooth rounded tumour could be felt, which was lost under the left lobe of the liver above, and below was limited somewhat sharply, especially on the right side, at about the level of the umbilicus. It pulsated, and its pulsation was distinctly expansile. It could not be defined exactly towards the left epigastrium and left lumbar region. Dulness on percussion corresponded with the palpation signs, and separated the tumour from anything cardiac. Over the tumour a loud systolic murmur could be heard, which was lost towards the heart's apex, where two pure sounds were audible. The murmur was loudest a little to the left and a little above the umbilicus.

The breathing was jerky, and a few moist râles could be heard in most parts of the chest. Over an area the size of a crown-piece, at the spinal extremities of the left eleventh and twelfth ribs, could be heard a distant, blowing, systolic murmur. The feet, especially the left, pitted on pressure, and but little pulsation could be felt in the left femoral artery. The bowels were constipated, the appetite small, the tongue large and furred, and the man complained of thirst and nausea, which were relieved by vomiting. The urine contained a considerable amount of albumen, and this persisted to the end, though microscopically nothing could be found. Very shortly after admission the patient had a convulsion of epileptiform kind, though he had never suffered from such an attack before. The following night he was delirious, and constantly attempted to get out of bed.

These various symptoms continued more or less during his stay in hospital, but he had no recurrence of convulsions. His headaches, which were fixed in the frontal region, were accompanied by restlessness during the day and delirium during the night. They were worse at nights and came on in capricious paroxysms, during which the abdominal pains and tenderness increased, as also pains in the left testicle, of which he at times complained exceedingly. When he walked he was dizzy, and had the sensation of moving in a circle, but he had no intolerance of light or sound and no impairment of any special sense beyond flashes of light in his paroxysmal attacks, nor was there any paralysis. In his paroxysms of pain his pupils

were dilated, and gave him a wild and staring look, but they responded to light. During the last few weeks of life there was a rapid increase in the size of the abdominal tumour towards the left.

He was treated with large doses of iodide of potassium, the renal secretions being copious, and experienced marked relief from pain. Ten grains, three times a day, at first relieved, and when so much failed doses of fifteen grains answered. He required a regular increase of the amount, and towards the end took thirty-grain doses. Belladonna plasters also seemed to be of service, and thick smearing of the extract of belladonna over the epigastrium. But notwithstanding the relief yielded by these remedies, conjoined, of course, with treatment of such symptoms as constipation, &c., his pains at times towards the end, when the tumour was rapidly increasing, became very severe, and his headaches again terminated frequently in a species of delirium. Morphia was then employed subcutaneously, and the effect was such that the man constantly craved with the return of pain, for its exhibition. He became gradually exhausted, and at last died, somewhat suddenly, on January 17th, 1877.

On *post-mortem* examination large blood clots were found in the peritoneal cavity, especially in the lumbar regions. There was but little fluid blood found. The thoracic aorta was studded with numerous gelatinous patches of atheroma; the left ventricle was contracted and simulated a concentric hypertrophy, a phenomenon frequently met with after death from hæmorrhage. The heart was, however, generally hypertrophied; the lungs were normal. In the brain nothing was found to explain the severe headaches; the arachnoid was a little opaque in places, and the arteries at the base somewhat degenerated, but no aneurysm could be found in these vessels or in their branches. There was a slight excess of serum in the lateral ventricles.

Examination of the abdominal cavity was far from easy. It was, however, clear that a large aneurysm existed, though its exact nature could not at once be determined. When the intestines were turned back it was seen to occupy the middle of the abdomen, and to extend to both sides, but chiefly towards the left, into the hypochondriac and lumbar regions, where it involved the left kidney. There was a vast growth of firm fat about the aneurysm and in the posterior floor of the abdomen; and the whole when first viewed formed a tumour of very remarkable size. It extended from the

diaphragm downwards to the top of the sacrum, and occupied the abdomen from the right side of the spine, throughout the left hypochondriac and lumbar regions, down to the iliac fossa, and its depth (antero-posteriorly) was about four inches. It reached the under surface of the liver, and was, of course, crossed by the stomach, pancreas, and duodenum, all of which must have been more or less compressed by it.

The aneurysm and the tissues involved were removed *en masse*, with the portion of the spine on which the tumour was lying, and to which it was partly adherent, and a dissection then made of them. After clearing away the vast growth of fat it was found that the aneurysm sprang from the abdominal aorta, and involved this vessel from immediately below the diaphragm to a little distance beyond the origin of the renal arteries. It consisted of two portions, one on the right side, another on the left, the former having the appearance of an ordinary aneurysm, the latter resembling a large firm clot, encased in membranous walls. The two were separated along the middle line by a deepish furrow, in which was lying the vena cava inferior. The exact condition of this and other vessels will be afterwards described.

That portion of the tumour which resembled an ordinary aneurysm extended beneath the vena cava towards the right side, and posteriorly was adherent to the vertebræ. It grew in the direction of the right kidney and towards the under surface of the liver. Its walls were thick and strong, and made stronger by firm fibrous-tissue growths. It was undoubtedly the original aneurysm, and as it extended from the diaphragm almost to the bifurcation of the aorta it involved more or less the branches of this vessel. The cœliac axis suffered least of all; it sprang from the body of the tumour, but itself and its branches were not enlarged. The superior mesenteric was dilated at its origin, and was guarded against rupture by strong fibre-tissue growths. The right renal artery was not enlarged, but in its course from the aorta had been put on the stretch by the tumour, whose anterior wall it encircled for a distance of two inches, and in whose strong fibrous coatings it was for some distance deeply embedded. The left renal artery was not affected in the same way; it traversed the left portion of the aneurysm, and its anatomical position to a great extent protected it. The veins suffered even more than the arteries. The vena cava crossed the right portion of the tumour from below over its whole extent, and

must have been greatly stretched and compressed. It contained immediately at its commencement firm laminated clots, which all but made its channel impervious. The right renal vein was, however, not materially affected; its shorter course had saved it from the stretch put upon its corresponding artery. The ureters had also escaped pressure.

The second and larger portion of the aneurysm occupied, as has been said, the left fossa of the abdomen. It consisted of a hard, clot-like mass, surrounded by membranous walls, and was entirely post-peritoneal. It had the extent already described. It was in direct communication with the portion of the aneurysm just dwelt upon, for when the finger was passed from the thoracic aorta into the body of the two masses it was found that there were openings right and left into them. When the two portions were dissected out it became certain that we were dealing with a true and a traumatic aneurysm, the latter filling the left abdominal fossa, and consisting for the most part of laminated firm clot, encased in walls far less consistent than the clots themselves. It embraced the left kidney, which was found completely buried in the laminated clots, through which the renal vessels burrowed. Possibly the firmer walls of the artery had resisted compression, but the vein had yielded, and was flattened and small in size, in comparison with the free uncompressed right renal vein. The thoracic duct, deeply buried, had escaped, and so had the semilunar ganglia. The abdominal aorta below the aneurysm was thickened, and the thickening extended on the left side as low as the femoral artery in Scarpa's triangle. This vessel was thickened, so as to resemble in size an abdominal aorta; it contained layers of clot and was almost impervious. It should be mentioned that the traumatic portion of the abdominal aneurysm had encroached towards the right side so as to overgrow the true aneurysm.

There was, therefore, a traumatic as well as a true aneurysm, and sections through the clot in the former showed its large mass occupying the whole left fossa of the abdomen as a solid tumour almost; it communicated with the aorta by an orifice, the size of a half-crown piece, the edges of this opening being jagged. In fact, the original aneurysm had ruptured on the left side, blood had in consequence escaped into the post-peritoneal tissues, these had guarded against rapid extravasation, and had so guarded that the membranous tissues had formed a false aneurysmal wall. In this wall

the peritoneum and the crura of the diaphragm had a part. Both had been carried forward by the extravasating blood, and both, by their firmness, had prevented excessive hæmorrhage, and thus led to the vast laminated coagula met with in the traumatic part of the aneurysm. The right portion contained also laminæ of clots, but these were thin, and though more organised than on the left side did not fill the aneurysmal cavity. At the last, hæmorrhage had occurred into the peritoneal cavity, but the exact point of rupture could not be determined.

The pathology of this case seems clear enough, though the accident which led to the man's death is rare. Traumatic aneurysm of the kind described occurring secondarily to ordinary abdominal aneurysm is by no means common, and its possibilities neglected. I believe that when abdominal aneurysms rupture into the post-peritoneal tissues, and not into the peritoneum, a support exists which prevents sudden death. In the case of aneurysm of the cœliac axis, which I report in the present volume, such rupture must have occurred without causing sudden death. The clinical significance of this pathological fact I shall venture to explain. Hæmorrhage behind the peritoneum must put on the stretch this membrane, and it is a well-known clinical fact that such stretching is attended by violent pains. In this case (as well as in the case referred to) violent abdominal pains were complained of; in this case at least far more violent than in ordinary abdominal aneurysms. And looking back at the history it seems likely that the true aneurysm had been for long completely latent, had given rise to no symptoms, and had not until its rupture led to the suspicion of disease. The severe pains in the abdomen thus caused, taken with the recent occupation of the patient, suggested lead-poisoning, for which the man was admitted. Examination, however, at once detected the aneurysm, and during the patient's stay in hospital the paroxysms of pain from which he suffered are best explained by the occurrence of repeated post-peritoneal extravasation and consequent stretching of the peritoneum, It is worthy of note, however, that that there was not a trace of peritonitis at the *post-mortem* examination, and that the true aneurysm had grown in such a way that it could not have compressed the sympathetic ganglia in the abdomen.

The severe pains in the head were probably due to albuminuria. In fact, the head symptoms—convulsions, cerebral vomiting, frontal

pain—were probably uræmic and very likely the albuminuria was a consequence of compression of renal veins. This undoubtedly existed, and its results, as here met with, accord with the observations of others. It is plain also that the interference with the arterial circulation through the abdominal aorta must have caused collateral fluxion to the head, and such excessive fluxion may have favoured, not only the occurrence of headache, but even of convulsions, and indeed many of the symptoms indicated a cerebral hyperæmia.

The case is valuable as proving the obscurity of abdominal aneurysms, the occurrence of traumatic secondary aneurysms in them, and the possibility of albuminuria with severe symptoms from compression of renal veins by such aneurysms. I may add that I have seen other cases of abdominal aneurysm in which lead-poisoning was diagnosed as the cause of all the symptoms, the patients having worked amongst lead, and having a decided blue line along the gums. *November 6th*, 1877.

---

14. *Aneurysm of the cœliac axis, caused by diffuse suppuration in the retro-peritoneal tissues, consequent on concretions in the kidney; pyæmic changes in the lungs and elsewhere.*

By J. Pearson Irvine, M.D.

A man, æt. 49, was admitted into the Charing Cross Hospital on December 2nd, 1876, and died there on January 10th, 1877. He came of a family phthisical on the mother's side, but had himself enjoyed good health up to quite recently. In his youth he lived "hard," and at twenty had gonorrhœa. Fourteen days before admission, while following his work as a house decorator, he felt pain in the left knee, which next day obliged him to give up work. For the rest of the week the joint was painful and swollen; at the end of the fortnight the man found himself very ill, and came into the hospital, believing (as was the truth) that he was in a very precarious condition.

He was from the first irritable and angry when his symptoms were inquired into. His pulse ranged between 90 and 100; the

respirations were described as rapid, and the temperature was on admission 101·2° Fahr. He had an appearance of severe illness; his cheeks were flushed, his tongue foul, with a sickly odour in his breath. The left knee was red in patches, but no evidence of effusion into the joint could be found, and its general look was that met with in gonorrhœal rheumatism of debilitated subjects. The left foot was tender and slightly œdematous. Pain was complained of in the knee-joint and downward to the foot, but there was no complaint of pain in the abdomen. The man was put on a liberal diet with brandy, and was ordered an effervescing mixture of carbonate of ammonia and citric acid. His temperature fluctuated between 100° and 102° Fahr. during the first fortnight in hospital, and an incision into the tissues about the knee-joint was followed by marked relief from pain, but there was no tendency to healthy reaction, and about the middle of December, though the temperature fell even to below normal, he went from bad to worse. He began to suffer from lung trouble, his respirations averaged from 28 to 30, and he had considerable orthopnœa. Beyond what has been mentioned there were no evidences of septicæmia. The tissues about the affected knee remained in a state of low inflammation; and though the patient improved under quinine, gr. iv t. d. s., he was towards the end of December really much worse than at the beginning, though his temperature had only occasionally risen beyond 100° Fahr.

At the end of this month he complained of pains in the abdomen for the first time, but could bear only little examination, and about the same time of lung symptoms, and generally showed more decided evidences of pyæmia. Early in January examination of his lungs betrayed distinct signs of a low pneumonia at both bases, and of probable pyæmic abscesses there. His temperature had been rising for a few days, and shortly before examination had reached 103° Fahr., and there had occurred also sudden and unexpected falls (through three degrees), but no rigors either lately or throughout the course of the illness.

The day before the man's death I again saw him; he had, more than before, the look of one "pyæmic," and complained again of pains in the abdomen, which was distended and everywhere tender, so that examination was imperfect. There could, however, be distinctly felt in the right hypochondrium a movable body the size of the hand. It was moderately yielding, but mobility was its striking characteristic. Its nature could not be determined. No pulsation

could be detected anywhere, and it was suggested that the right kidney was probably enlarged and that a movable tumour was in connection with it. The patient died the next day, his temperature having ranged for a week between 100° and 102° Fahr. He had passed neither pus nor albumen in the urine until seven days before death, and the pus then passed was very small in quantity (microscopical), and the amount of albumen moderate.

On opening the abdomen and thorax a large excess of fat was found, of a peculiar lemon colour, firm, and resistant. It abounded in the cardiac region and in the mediastina generally; in the walls of the abdomen it was nearly an inch thick, and in the omentum its amount exceed by far that of health. The heart was normal in size, but on both the tricuspid and mitral segments, near the attachments of the chordæ tendineæ were found gelatinous swellings, some as large as a split bean, and on microscopic examination fibro-fatty in kind. The valves were not shortened, nor roughened in their membranous parts. The aortic and pulmonary orifices were entirely healthy. There were some gelatinous swellings on the aorta immediately above the valves.

In both lungs pyæmic abscesses were found, one on the posterior surface of the lower lobe of the left lung being as big as a walnut; and this lobe was more or less solidified, as occurs in bad forms of pyæmia. There was a peculiar stickiness on section in all parts of the lungs. Scattered cheesy masses were found in both apices.

The peritoneal cavity contained a quantity of bloody fluid, and in each hypochondrium was a large clot bigger than a hand and twice a hand's thickness; these clots fitted accurately to the organs on which they were lying. Adipose tissue had invaded the kidneys and encased them in a covering quite an inch thick; it had invaded similarly the other organs of the abdomen and made it exceedingly difficult to conduct the *post-mortem* with accuracy. On the left side of the abdomen retro-peritoneal abscesses were found, which freely burrowed amongst the fat, and these were in connection with like pathological changes in and around the left kidney. This kidney contained numerous curiously-shaped calculi (such as are shown); some of these accurately fitted into the calices, and they had set up a nephritis with consecutive abscesses in and about the cellular coverings of the kidney. The normal tissues of the organ were all but completely destroyed, and the consequence was that the right

kidney was large from compensatory hypertrophy, but otherwise free from disease.[1]

In the middle line of the abdomen, immediately below the diaphragm, was found an aneurysm twice the size of a large orange. It appeared to spring from the aorta, but its deeper parts were so overgrown and grown into by cellulo-adipose tissue that it was not at first easy to say whence it sprang. Its anterior walls broke down on the least handling, and the exact point from which the blood found in the abdomen had come could not be ascertained. But after removal of the parts, which was done with difficulty (because they so readily yielded), and attempts at hardening by immersion for a long time in strong spirit, it was found that the abdominal aorta was unaffected, and, moreover, that its coats were quite healthy, except that there was a patch of atheroma near the cœliac orifice. This orifice itself was healthy, but a probe passsed through it into the cœliac axis entered at once the cavity of an aneurysm. The external coats of the next branch—the superior mesenteric—were thickened. The aneurysm was one of the cœliac axis alone; but owing to the vast growth of fibro-fatty tissue which had followed the burrowing of pus, exact determination of the state of the branches of the cœliac axis could not be made. It was certain that the aneurysm involved the origins of all, but not the origin of the artery itself. The pyæmic state favoured rapid putrefaction, but in spite of many drawbacks the morbid changes illustrate facts which bear on the pathology and clinical history of abdominal aneurysm.

The aneurysm contained a large quantity of clot of but moderate firmness, its walls seeming to consist of partially organized clot chiefly; and everything indicated a rapid growth of the tumour. It had ruptured some time before death, for a large pear-shaped clot had insinuated itself amidst the tissues along the spine. The aneurysm had displaced the vena cava, which was so compressed just below its point of departure into the thorax, that a probe could scarcely be passed through it. Below the vein was dilated The renal veins were carefully looked to; the right was not affected in any degree, but the left, from its origin to the point where it crosses the aorta, was buried in solid fat; yet it would be hazardous to say that in consequence of this the circulation through it must have been interfered with. The thoracic duct, in spite of all the changes, was

[1] Pelvis of left kidney was large; ureter dilated, contained a calculus, which did not completely block it; the walls of bladder were thickened.

not compressed, unless by the fatty tissues which it traversed. The semilunar ganglia were healthy, and the direction of growth of the aneurysm was such that they must have escaped serious pressure, a fact of importance in explaining the absence of abdominal pains for a long period. The liver was moderately lardaceous and there was a sago-spleen. The morbid changes found about the knee-joint were such as had been noted during life—cellulitis and its consequences—and the interior of the joint was healthy.

Remarks.—I venture to think that in this case the primary mischief was renal calcalus, and that pyæmia was a result of it. Concretions had been accumulating and growing in the left kidney for a long period without giving the least evidence of their existence, and the extent and nature of the abscesses seem to show that they too must have existed for a long time without giving rise to any serious symptoms. The liver was lardaceous; as was also the spleen, and these conditions favour the view that suppuration must have gone on internally for longer than the short time during which the tissues about the knee-joint suffered.

I mention these points because until a very short time before death there was no evidence of disease except in the neighbourhood of the knee-joint and naturally to it was attributed the pyæmic mischief which afterwards declared itself so decidedly.

The order of events must have been, gradually increasing and growing renal concretions, inflammatory and suppurative changes caused by the same, burrowing of pus in the posterior part of the abdomen, affection of the walls of some of the great arteries in consequence, aneurysm of the cœliac axis, and "pyæmia," leading to lung changes and to such disease as that met with about the knee-joint. The most difficult question to decide concerns the occurrence of aneurysm. Was it really sequential to the renal mischief and suppuration? Had the external walls been damaged by the suppurative and other processes which were distinctly in contact with them, and in consequence had a part of the wall given way so that a traumatic aneurysm had resulted? I have recently seen an aneurysm in the cavity of an abscess of the liver (as occurs in cavities of phthisical lungs in spite of fibroid thickening of the arteries), and cannot but think that possibly, in this case which I show, suppuration had deteriorated the arterial coats, and by weakening the natural adventitious support allowed the occurrence of aneurysm. It will be seen also from the specimen that the walls of the aneurysm are through-

out fragile and do not in the least resemble the firm tissues usually met with in abdominal aneurysms, a fact indicative of rapid and traumatic growth of the tumour.

I cannot offer these remarks, as regards the—so to speak—traumatic nature of the aneurysm, more than as mere surmises, however, and should be glad to have the opinion of others more experienced than myself. Of course it is quite possible that the aneurysm was simply coincident with the great changes in the abdomen, and independent of them, but its appearances and the appearances of the latter, as well as the clinical history of the patient, certainly prove that its beginning was subsequent to the other morbid processes met with in the abdomen. It is likely that the firm, fatty growths which existed about the aneurysm, as elsewhere, had served as a protection to its thin fibrinous-like walls. And as bearing on the theory of the causation of the aneurysm it should be remembered that the arterial system, except at one part (the cœliac axis), was healthy, barring the insignificant patch of atheroma found near the origin of the axis. In regard to the albuminuria, which occurred a little while before death, possibly compression of the renal vein, or of the vena cava, had something to do with this. The point is of interest in connection with the abdominal aneurysm which I report in the present volume.

The case, looked at from a clinical point of view, illustrates not only the obscurity of abdominal aneurysms, but of renal concretions, and the suppurative changes sometimes following the same. It is impossible to comprehend how, in the absence of more decided change in the urine, of abdominal pains, &c., any other diagnosis than that of joint-disease with subsequent pyæmia could have been made. There were absolutely no signs or symptoms of renal concretions, and the evidences of septicæmia were insidious and slow in development. Another fact of interest is the great growth of fat, not only in the abdomen, but in the thorax, and in the walls of both these cavities. So to speak, a pathological mine was found on dissection, evidences of which during life were quite wanting. The cœliac aneurysm, for example, had caused no lumbar pain and had given rise to no murmur, but it should be remembered that it was deeply buried when examination of the abdomen was first made. It is, however, interesting to note that a clot which followed the rupture of the aneurysm could be distinctly felt through the abdominal wall. The "tumour" felt in the right hypochondrium was found *post-mortem* to be one of these clots.

November 6th, 1877

15. *Cases of aneurysm of the cerebral and brachial arteries.*

By W. S. Greenfield, M.D.

The series of cases here described illustrate two distinct forms of aneurysm, the one originating in embolism, the other of the kind known as miliary aneurysms, due to a peculiar degeneration of the vessels, and leading to the production of hæmorrhage.

The first two cases of cerebral aneurysm belong to the first class, of which also the case of brachial aneurysm seems to be an instance. The first case, by far the most remarkable, is noteworthy for the entire absence of symptoms, notwithstanding the large size of the aneurysmal sac.

Case 1.—*Aneurysm of the basilic artery; vegetative endocarditis.*—Alfred C. C—, æt. 16, was admitted on Feb. 10th, 1877, under the care of Dr. Stone, with old cardiac disease.

[The symptoms and clinical history having reference only to the heart disease and general condition need not be detailed.]

Post-mortem examination thirty-three hours after death, on May 4th.—The body extremely emaciated, the limbs being reduced almost to mere skin and bone. A few scattered petechiæ on the limbs; anasarca entirely wanting. The pleuræ natural, free from adhesions, and empty. The lungs, weighing 8 and 6 oz. respectively, were both extremely light and spongy in texture; they were pale and somewhat emphysematous throughout; on section dry and crepitant, bloodless, as if death had occurred from slow bleeding, and entirely free from signs of congestion.

The pericardium presented general adhesions, not intimate, but formed by long, tough, fibrous bands. The heart weighed 10 oz., was slightly but not notably enlarged, and its several parts were of natural proportion externally. The right auricle was natural, the tricuspid orifice and valve normal, the right ventricular wall slightly thickened, but otherwise natural, the pulmonary valves healthy, and there were no *ante-mortem* thrombi either on auricle or ventricle. The left auricle appeared free from dilatation; on laying it open, the mitral valve was seen to be much diseased. The entire valve

appeared to be transformed into a mass of fungating vegetations, forming long pendulous masses; on its auricular surface and on the adjacent wall of the auricle itself were thickly scattered warty outgrowths, many of which were long and finger-like, resembling the filiform papillæ of the tongue in shape. Scarcely any fibrinous deposits were seen, nearly all being apparently simple endocardial outgrowths. The orifice did not appear to be narrowed. On laying open the left ventricle, its cavity appeared very slightly dilated, its walls natural, free from thickening. The ventricular surface of the mitral valve was much less altered than the auricular, many of the chordæ tendineæ being entirely free from thickening, others only slightly swollen.

On the aortic valve, at the centre of the posterior segment, and chiefly at the part nearest the ventricle, was a small cluster of vegetations similar to those on the mitral valve. The aortic valve was otherwise entirely free from disease, its segments quite free from thickening or opacity, and it was quite competent, as tested by water. The aorta was natural throughout.

Peritoneum natural; the liver weighed 2 lbs., was rather small, pale, and flabby, but otherwise normal. The spleen weighed 8 oz., was considerably enlarged, and adhered somewhat firmly at its upper part to the diaphragm, and it contained very numerous infarcts scattered through its substance, of various dates, some old, firm, yellow, and encapsuled; others in a state of commencing caseation; and yet others, one of which was of large size, of recent date, partially softened in the centre. The kidneys were of normal size, weighing 7 oz., their capsules generally somewhat adherent, and on separation of the capsule, several scars of old infarcts were seen scattered over the surface. With the exception of these depressions the surface were generally smooth, of brownish colour, with numerous minute red dots scattered over it; on section the general colour of the cortex brownish red with translucent patches, and scattered everywhere throughout the organ were numerous small red points and streaks, as if from hæmorrhage. No staining with iodine. The supra-renals were natural, rather firm and pale; the thymus gland persistent and of rather large size. The pharynx and œsophagus were normal, excepting a few scattered minute ecchymoses in the mucous membrane, and some in the cellular tissue around. The uvula swollen, œdematous; the upper orifice of the larynx normal. The stomach healthy; intestines natural, with the exception of some

scattered ecchymoses throughout, which were most marked in the lower part of the ileum.

Brain, &c.—The calvaria and dura mater normal, the sinuses full of dark fluid blood. On the upper surface of the hemispheres were seen numerous small, scattered patches of subarachnoid hæmorrhage, together with some patches of yellow staining, as if from older hæmorrhages.

On raising the brain, a quantity of coagulated blood was seen at the base, covering the basilar process and a part of the left petrous portion with a somewhat firm, uniform layer, about ¼ of an inch thick. In addition, there was a quantity of partially coagulated blood lying around the base, and surrounding the medulla and upper part of the cord. After removal of the organ, a firm coagulum was found covering the interpeduncular space and optic commissure; some of this was partially decolorized and evidently of old date; it adhered very firmly to the superjacent parts. Beneath this (that is, lying above in the natural position), a firm rounded mass, about ¾ of an inch in diameter, lay embedded in the brain substance, overlying the circle of Willis, the vessels composing which appeared to pass into it (see Woodcut).

The brain substance generally was firm; the lateral ventricles

WOODCUT 3.

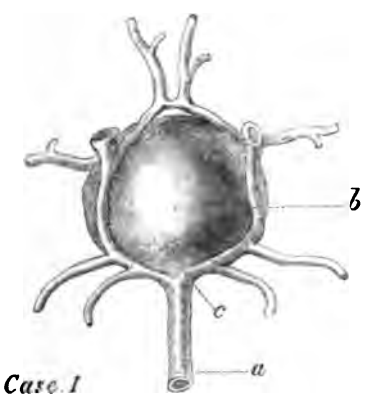

Aneurysm at division of basilar artery, seen from below, the sac resting upon the circle of Willis. The brain has been entirely removed. *a.* Basilar artery. *b.* Sac of aneurysm. *c.* Point of entry of artery into sac of aneurysm.

greatly dilated and distended with clear serous fluid. The third ventricle also much distended. On cutting through the floor of the third ventricle, in the median line, the sac of the aneurysm was laid open.

In the pia mater were several small hæmorrhagic patches, and one or two small vessels were found to be filled and distended with a soft white clot.

The aneurysmal sac was carefully dissected out, and its shape and relations, as seen from below, are shown in the drawing by Mr. C. Stewart (Woodcut 3). The sac was of globular shape, slightly flattened below, and was symmetrically placed over the circle of Willis. Its wall was thickened with laminated organized clot, so that internally its diameter was less than half an inch, externally three quarters in its narrowest, and nearly an inch in its longest diameter. It originated from the point of division of the basilar artery (*c*), from which it projected forwards and upwards. The posterior cerebral arteries were closely adherent to the sac; the other branches of the circle of Willis were in immediate contact, and united by coagulated blood, but not otherwise adherent. The exact point of rupture could not be discovered.

Case 2.—The second specimen, which is only of pathological interest, having produced no symptoms, was one of a small sacculated aneurysm, the size of a pea, connected with a small branch of the left internal carotid in the cavernous sinus (see Woodcut 4, Case 2).

Woodcut 4.

For description of figures in this woodcut see text.

It was from the body of a young woman twenty-two years of age, under the care of Dr. Murchison, who died of heart disease. There was no history of rheumatic fever; the patient had hemiplegia two

years before her death, from which she had completely recovered. The heart presented marked stenosis of the mitral valve, which was completely incompetent; from the anterior segment there projected upwards a rounded mass of calcified vegetations, the size of a large pea, this irregular rough mass nearly filling the orifice; the aortic valve incompetent, free from vegetations; very numerous old and were infarcts in the kidneys and spleen. The brain and its vessels recent healthy, with the exception of the small aneurysm before described, the size and relations of which are seen in the drawing.

The interest here lies in the fact that evidences of embolism were found in several organs, and that the slight attack of hemiplegia, from which the patient recovered completely, was probably due to a similar cause.

CASE 3.—*Aneurysm in a superficial branch of the middle cerebral artery; rupture into the brain: death.*

The specimen, was removed from the body of a man forty years of age, a waiter, who was admitted under the care of Dr. Stone, on May 7th, 1877, in a comatose state from apoplexy, and died in two or three hours. The examination was made twenty-four hours after death.

Head.—The calvaria and dura mater natural; longitudinal sinus filled with dark fluid blood; convolutions of left hemisphere flattened. Slight subarachnoid effusion of blood most noticeable over anterior part of right hemisphere, a very small quantity of blood at base, and a little over centre of cerebellum. Both lateral ventricles filled with fluid blood, most marked in left; blood along velum interpositum. A very large mass of clot occupying the position of lenticular nucleus of corpus striatum, extending forwards also as far as the tip of anterior cornu of left lateral ventricle, into which it had burst. On tracing it backwards the blood was found to plough up the centrum ovale majus in a continuous track to the surface, which it reached at a point three quarters of an inch behind the fissure of Rolando, and at this point a small aneurysm, the size of a pea, was discovered. The vessels at the base of the brain were quite healthy, and free from atheroma or obvious dilatation. On following the superficial branches of the left middle cerebral artery, the aneurysm was found to be seated upon one of them (Woodcut 4, Case 3). It was of the size of a pea, completely embedded in the brain substance, and surrounded by some old inflammatory thickening of

the pia mater. Its walls were thick, and there appeared to have been some slight hæmorrhage around it of older date. It had ruptured by a small opening on the inner surface, and the blood, poured out in the direction of least resistance, had ploughed up the brain in a way almost like the track of a bullet.

The heart weighed 13 oz., but appeared only very slightly enlarged; valves healthy; no hypertrophy of left ventricle; muscular tissue under the microscope markedly fatty. Extreme atheroma of aorta, both of the arch and of the thoracic descending portion (large calcareous plates, and many semi-transparent, gelatinous patches), some patches of atheroma also in abdominal aorta and iliac arteries. Just outside the pericardium, a sacculated aneurysm, the size of the tip of one's thumb, was seen; the walls of this sac were thick, and it contained a layer of decolorized clot. One or two other patches showed commencing pouching.

Kidneys weighed 12 oz., both somewhat large, capsule thickened and laminated, surface, however, not granular; tissue firm, somewhat greasy; no cysts in cortex. The only marked morbid appearance consisted in an extreme patency of the small arteries, which stood out as rings on the sectional surface. Their walls were not very obviously thickened, but appeared very translucent. No very obvious atheroma, even of larger arteries, but they also stand very widely open, and appear rigid. The liver showed marked puckered thickening of the capsule, but in other respects appeared natural. The other viscera presented nothing noteworthy.

Case 4.—*Miliary aneurysms in corpora striata.*—The specimen was from the body of a man, æt. 40, a plumber, who died of œdema of the lungs associated with granular contracted kidneys, and who had had slight left hemiplegia. Towards the outer and lower part of the nucleus lenticularis of the right corpus striatum, extending along its whole length, was an old hæmorrhagic focus, with very marked remains of blood pigment. In the centre of the left lenticular nucleus the small aneurysm shown was found (Woodcut 4, Case 4); it was the size of a small mustard seed, round, and on the course of a small artery. There was no trace of hæmorrhage around it. The brain in other respects was natural. It is needless to detail the condition of the remaining organs. The interest of the case lies in the coexistence of a miliary aneurysm in one corpus striatum, with an old hæmorrhage in the symmetrically corresponding position on the other side.

In Cases 3 and 4 there was no atheroma of the cerebral arteries. The microscopic examination of the renal vessels in Case 3, showed merely marked thickening of the middle and outer coats, but no atheroma. In fact, the condition of the vessels which tends to the production of these small aneurysms appears to be quite different from atheroma. Indeed, microscopic examination shows little beyond thickening of the middle coat.

Aneurysm of the brachial artery at its division; rupture. aortic valvular disease: acute pleuro-pneumonia.—C. M—, æt. 38, was admitted under the care of Dr. Murchison, on January 22nd, 1875, suffering from aortic regurgitation.

On February 9th he was seized with severe pain in the left arm, near the bend of the elbow, followed by rapid swelling of the arm and discoloration. Mr. MacKellar, then resident assistant-surgeon, was called, and came to the conclusion that the symptoms were due to rupture of an aneurysm; he therefore ligatured the brachial artery in the middle of the arm, and the swelling ceased to increase. The patient went on well for two days, when pleuro-pneumonia set in, of which he died on February 14th.

Post-mortem examination.—Body of muscular man; well developed; skin generally of rather yellow colour; no anasarca.

Pleuræ.—Right contains one pint of slightly turbid fluid; recent inflammatory lymph covering the lower lobe of the lung only in a thin layer; left normal.

Lungs.—Right 3 lb. 1¼ oz.; left, 1 lb. 3½ oz. Left emphysematous, otherwise normal. Right: lower and middle lobes fully expanded, completely solid; on section is in a state of typical grey hepatization, passing in the upper part of the lower lobe into breaking down of the lung tissue. At one or two points near the root of the lung the inflammation was less advanced, only reaching the state of red hepatization. The consolidation was quite uniform, and there was nothing to indicate any difference from ordinary pleuro-pneumonia. The upper lobe emphysematous, tissue very pale, bloodless, and dry throughout.

Heart.—Weighed 17½ oz., large; somewhat displaced to the left, and occupying a large area. All the cavities dilated, and containing a good deal of normally coagulated blood. The aortic valves when tested in the usual way appear to close completely, no water passing through when poured from above. Looking from above a considerable deformity is at once observed, two of the semilunar flaps

not moving at all, and apparently firmly adherent to each other. A stream of water passed through the ventricle escapes with difficulty through the orifice, passing only along one side of it, and only very incompletely filling the aorta. On opening the aorta, the two posterior flaps were found to be considerably thickened and swollen, with vegetations along their adjacent borders, which were firmly united to each other; and from the adherent corpora arantii a firm decolorised clot, about ½ an inch long, and $\frac{1}{12}$th wide, hung down into the cavity of the ventricle. There were a few small vegetations on the wall of the aorta, immediately above the adherent valves, mostly about the size of a mustard seed, and some also surrounding the orifice of the right coronary artery. Sinuses of Valsalva much dilated; anterior segment healthy. Mitral valve closes well; flaps somewhat opaque and thickened. On the anterior flap, at about its centre, was an aneurysm, the orifice of which looked towards the aorta, nearly circular, measuring about ⅜ of an inch in diameter; the margin was somewhat irregular, and surrounded by small vegetations. The sac projected upwards and inwards on the auricular surface of the valve for about ½ an inch, and was of about the same width. The cavity was filled with coagula; chiefly soft *post-mortem* clot, but a small piece firmer and decolorized. Wall of left ventricle thick, substance rather pale; cavity somewhat but not excessively dilated. Left auricle dilated, and wall a good deal thickened; endocardium opaque; cavities of right side somewhat dilated. Aorta slightly atheromatous at points, especially at bifurcation, and also iliac vessels.

Liver.—Apparently normal; substance somewhat firm. Weight 5 lb. 6 oz.

Spleen.—Weight 15½ oz., very large; Malpighian corpuscles prominent.

Kidneys.—18 oz., large; capsule not adherent; cortex somewhat vascular with opaque white clots on the surface; and on section an irregular mottling, resembling that seen in cloudy swelling of the epithelium.

Intestines.—Normal.

Brain.—53½ oz., somewhat œdematous and pale, otherwise normal. Vessels at base only very slightly thickened and rigid at one or two points; no atheroma.

Left arm, &c.—A longitudinal incision over middle third of left brachial artery; wound partly closed; edges with slight granula-

tion; ligature still firmly adherent. On opening the wound, a good deal of ichorous fluid exuded, and just beyond the lower end of the wound was a small collection of healthy-looking pus extending downwards outside the sheath of the vessels for about an inch. There was considerable inflammatory thickening around the wound and extending along the sheath of the artery, which was firmly adherent to the vessel. The veins of the arm appeared perfectly normal.

In removing the skin from the forearm, which was much swollen, a considerable quantity of watery fluid escaped from the subcutaneous areolar tissue. On cutting through the superficial fascia, fluid blood was found lying beneath it, especially in the centre of the anterior aspect, extending nearly to the wrist. Some blood also extended upwards along the sheath of the brachial artery two inches above the elbow. In the lozenge-shaped space in front of the elbow was a mass of semi-coagulated blood, completely filling it and extending also beneath the muscles, which were expanded over it so as to form a sort of sheath; they were also much infiltrated with blood. The median vein and its divisions lay over the mass, but were quite unconnected with it. The ulnar and radial arteries were traced upwards from the wrist, and appeared quite healthy as far as their origin. The mass of blood and the structures lying in front of them were also removed, together with the brachial artery, for further examination.

Looking at the vessels from behind they appear quite healthy and there is no sign of dilatation. The radial artery is somewhat displaced outwards by the mass of blood, which lies partly between it and the ulnar. On looking carefully at the point of bifurcation of the brachial, the coat of the vessel appears thin.

The brachial was then opened by a longitudinal incision on the posterior aspect as far as its division, and the incision continued into the ulnar. It was then seen that an orifice existed just at the point of division, due to rupture of the vessel. The opening was about ½ an inch in length, somewhat crescentic in shape, extending further along the ulnar than the radial, its upper margin crescentic and rounded. At each end of the opening was a thinning of the wall of the vessel beyond the point of actual rupture, the inner coat alone remaining, looking, in fact, as if the outer and middle coats had been split beyond the inner. The orifice was situated more towards the anterior than the posterior aspect of the vessel.

Further examination showed an undoubted aneurysmal sac which had ruptured.

Although it may be questioned whether this was not a case of simple rupture of the vessel from overstrain, the position at the point of division and the presence of a clot attached to the aortic valve render it probable that embolism was the cause of the weakening which gave rise to the aneurysmal sac. There was no disease of the vessels elsewhere, nor was there hypertrophy of the heart, and the narrowing of the aortic orifice prevented any greatly increased tension in the vessels.

The case may be advantageously compared with the two first cases of cerebral aneurysm just related. The theory of embolic origin of some cerebral aneurysms, first suggested by Dr. Church, is now generally accepted, but the doctrine is not often extended to aneurysms elsewhere. My own belief is that this cause is much more frequent than is generally supposed, especially in the case of popliteal aneurysms. Instances have fallen under my own observation in which the coexistence of an aneurism of the arch of the aorta and of a popliteal artery has led to the belief in an "aneurysmal diathesis," but in which the condition of the other vessels has not borne out this view, and the origin of the popliteal aneurysm would have been equally well explained by the detachment of a piece of softened clot from the sac of the aortic aneurysm. In one case there was merely a patch of atheroma on the aorta, to which a polypoid thrombus adhered which was partially softened and ulcerated. Again, embolism of the popliteal artery is not extremely rare in such cases. These observations may, at least serve to direct attention to a possible source of aneurysm in the peripheral arteries.

January 15*th*, 1878.

16. *Thrombosis of the superior mesenteric artery, with plugging of the left femoral, external and common iliac arteries; gangrene of the leg; severe ulceration of the intestines.*

By H. G. Howse, M.S.

Mary J—, æt. 48, married, was admitted into Guy's Hospital under my care, on January 16th, 1878.

Up to eight months ago she says she was in perfect health, with the exception of occasional "bilious attacks." At this time she had a more than ordinarily severe attack, with great pain in the right hypochondrium and severe vomiting. After some days she got better and remained so for three or four months, when she had a return of the symptoms, for which she attended as an out-patient at Guy's Hospital, under Dr. Taylor. Her abdominal symptoms improved at the end of about three weeks, but now her left foot became numb. This was about one month before admission, as far as can be gathered from the rather confused account she gives of herself. She continued to get about until about eight days ago, when the back of the foot became black, and she was obliged to lie up. Further inquiry from some friends elicits that she has lived a very dissipated life, that of late her principal trouble has been very profuse diarrhœa, that she has never vomited blood, but that she has at times passed black coffee-ground stools. At the time she attended under Dr. Taylor, examination failed to detect any organic lesion accounting for her symptoms.

On admission.—The left foot is gangrenous to about the middle, the toes shrunken and withered. No pulsation can be detected in the left femoral artery, which is felt as a rounded, hard cord, running from Poupart's ligament down the thigh. She is excessively emaciated; all the skin of a yellowish tint, but without absolute jaundice; tongue dry and cracked; gums sore and bleeding, at points ulcerated; breath of a disagreeable sweetish odour. She is deaf and also purblind; says that she has suffered in this way for the last eighteen years, but that of late it has much increased. Suffers from

great thirst; can only swallow jelly or fluids, but craves for stimulants. The hepatic dulness, though rather lower than usual below the thorax, is normal in extent. The abdomen is very tender to the touch, rather distended, and the peristaltic movement of the intestine can be very distinctly seen through the thin abdominal parietes. There is much pain in the left limb.

During the following fortnight the gangrene slowly spread so as to involve the whole foot, though the whole limb was kept well wrapped in cotton wool, so as to maintain its temperature as far as possible. The principal feature about the case was the profuse diarrhœa, which continued in spite of all remedies. There was comparatively little vomiting. The pulse was uniformly higher than natural, and a chart of her temperature taken for sixteen days after her admission shows that the body-heat varied from 99° to 102°, the average being about 100·5°. The urine, which was only collected with difficulty on account of the profuse diarrhœa, was scanty, of high specific gravity, deposited a mucous cloud, but contained no albumen nor sugar. After a medical examination, Dr. Goodhart reported that the chest was resonant, even drummy, all over, but that there was bronchial breathing and bronchophony at the right apex. Heart sounds normal. And further, that examination of the abdomen pointed to no very definite lesion of the viscera, except probably considerable ulceration about the intestine.

On the 29th she was in much the same state of bodily health, but the gangrene was now spreading up the leg in the moist form. As it seemed doubtful whether the fœtid gangrenous material was not really the cause of its spread, by poisoning the neighbouring healthy tissue, I decided to amputate the limb just above the knee, and see whether its progress could be checked in that way.

Chloroform was accordingly administered, and the limb amputated in the lower third of the thigh. This part had so much wasted that the amount of tissue cut through was comparatively small. She took very little of the anæsthetic, and scarcely seemed to suffer from the shock of the operation at all. There was literally no bleeding—the femoral artery being perfectly plugged.

For two or three days after the operation she seemed better, expressed herself as being glad of being rid so easily of the stinking limb, and appeared altogether more cheerful. But soon there was a relapse, the diarrhœa returned, and without any very definite symptoms, except that the stump showed no signs of any healthy

action, she gradually got weaker, and sank and died in the afternoon of February 4th.

Sectio cadaveris, twenty-five hours after death, by Dr. Goodhart.

Brain, &c, healthy.

Chest.—Rather extreme dilatation of bronchial tubes in both lungs, but more marked on the right side, and extensive broncho-pneumonia in the lower lobe of the right side. On both sides the tubes contained a considerable quantity of pus in some parts, but mostly towards the bases. Trachea and larynx healthy. Heart (7 oz.) and pericardium healthy.

Left lower extremity presented a thigh stump. The flaps appeared healthy, but there was no adhesion between them. The femoral arteries were very good vessels, but the left femoral was plugged from the stump upward to the commencement of the common iliac at the bifurcation of the aorta. The clot extended along the aorta on its posterior wall for about one and a half inches, closely adherent to the vessel, and with a smooth surface towards the blood current. The right common iliac was healthy. The aorta from the clot upwards was quite healthy, but round the orifice of the superior mesenteric artery was another laminated clot of some thickness, laid down over the mouth of the vessel, extending down it for some distance, blocking it completely, and projecting into the aorta to a considerable extent. The branches of the cœliac axis were quite free. The left common iliac vein and commencement of the vena cava were also plugged by an *ante-mortem* clot, but this was not adherent, save at one spot in the common iliac, and from its colour and freedom from softening was probably of only a few days' date.

Stomach much dilated and occupying the whole of the cavity of the abdomen in front, the transverse colon being pushed down below it to the pubic and inguinal regions. It was quite flaccid and almost empty. Behind it were the rather contracted intestinal coils, and on the left side was a localised fæcal abscess, with a communication between the descending colon and the small intestine. On the right side was another communication between the small intestine and the ascending colon; the part of the small intestine here affected was that part of the jejunum which lies in front of the duodenum. There were in addition various adhesions between many of the coils of the intestine, which made it difficult to separate them. On opening the descending colon, many small, circular, pigmented ulcers were found in its interior. Judging from their pigmented

appearance and the absence of any active condition of inflammation, they appeared to be of old date. The edges of the intestinal fistula (mentioned before) had also a smoothness of outline and absence of any active ulceration, which appeared to betoken some standing. Just below the cæcum were extensive longitudinal ulcerations, with irregular, yet sharply defined and dentate edges, extending quite through the mucous and into the vascular coat of the bowel. Some of the ulcers were very vascular, more especially in their surrounding mucous membrane. Throughout the small intestines a similar state of things was found. The ulcers were not evenly distributed throughout, but in large patches. The mucous surface was intensely congested, ecchymosed, and thickened. The ulcers were sloughy-looking, irregular; some circular, with slightly thickened edges, others longitudinal, with less defined borders, and others again gave evidence of ulceration, more by superficial granular-looking erosion, than by any definite marginate patch marked off from the rest of the mucous membrane. Peyer's patches and the solitary glands were healthy. Mucous membrane of the stomach quite healthy. There was no lardaceous disease.

Liver (42 oz.), gall-bladder, pancreas, spleen (4 oz.), and suprarenal capsules all healthy.

Kidneys (8 oz.), pale but healthy. Renal arteries healthy.

Organs of generation.—There were a few adhesions between the ovary, fallopian tubes, and uterus, and some of the adjoining coils of small intestine. Otherwise they appeared healthy.

Joints healthy. No sign anywhere of septicæmia.

Remarks.—The pathological explanation of this case is very difficult. The following seems to commend itself most strongly to my mind as being best in accord with the facts of the case.

In the condition of the intestines there is evidence of old mischief in the pigmented ulceration, and smooth-edged fæcal fistula, Probably from this condition, as a starting-point, the minute arteries supplying the part became obstructed, and the obstruction. by "tailing-off" of the clot, gradually extended up to the point of junction between the superior mesenteric artery and the aorta. The mode in which the branches come off from the superior mesenteric artery would favour this mode of clot-production. In support of it may be mentioned the fact that when the branches of this artery were dissected, many were found patent, while others were found quite obstructed as far as they were traced.

Though these obstructed arteries were not absolutely traced out down to the spots of old mischief (which it was impossible to do on account of the adhesions between the intestinal coils), yet it is almost certain that these arteries were the ones corresponding to those patches. When the clot reached the aorta and began to project into it, a small piece may not improbably have been swept off and carried in the blood stream down the left iliac. Most probably the first clot thus detached was not sufficient to perfectly plug the artery, and hence the history given to us of numbness in the foot, but no gangrene appearing till three weeks later, when a second clot most probably completed the obstruction. The artery then filled up with coagulum, just like a vessel does after a ligature has been applied to it. It is probable, too, that the superior mesenteric did not become perfectly obstructed until a comparatively short period before death, the circulation in the small intestines, &c, being thus maintained in a feeble and irregular condition, partly by a small stream of blood flowing through it, and partly by the freedom of communication between it and the contiguous arteries. The acute congestion and ulceration about the small intestine and commencement of the large would, according to this view, be due to the gradual interruption in the blood supply.

Another suggested explanation of the case was that the clotting began in the femorals, and that a portion of the clot got detached from this, and whirled round by a kind of churning movement in the aorta above the obstructed common iliac, until it was carried up and lodged in the mouth of the superior mesenteric artery. Apart, however, from the difficulty of seeing why it should pass the renal arteries and be lodged in the superior mesenteric, this view does not afford any explanation of the complete obstruction of some of the branches of the superior mesenteric artery, and the patency of others. Moreover, such a clot would most probably have been carried down the opposite common iliac. Altogether, the facts seem very strongly to point to the first hypothesis suggested.

February 5th, 1878.

17. *Aneurysm of the anterior communicating cerebral artery.*

By J. Wickham Legg, M.D.

George D—, 20 years of age, was brought into St Bartholomew's Hospital on April 2nd, 1877, at 8 o'clock in the evening. His friends gave the following account of him:—He had had very little to eat for the last eleven weeks, but just before he was seized with the present attack he had had a full meal of new bread, periwinkles, and tea; he became very merry, dancing and singing; but after this, while sitting at table, he fell with his head forwards on to the table, and from that time to his death remained unconscious. He had not been drinking and was not subject to fits.

When first seen he was lying on a stretcher, with laboured breathing and noisy expiration. Face livid but pale. Pupils slightly dilated, insensible to light, cornea sensible to touch. Both arms and hands showed clonic convulsions, the fingers alternately opening and closing. Convulsions of the same kind were noticed in a less degree in the lower extremities. Pulse 112, irregular, temperature 101·6° Fahr., Respiration 34.

Admitted into a ward under the care of Dr. Southey, he passed urine and stools in bed. The spasms soon ceased, and he lay motionless and unconscious on the bed. He died next day at six in the morning.

For these clinical notes I am indebted to Mr. Darbishire.

Examination twenty-nine hours after death.—Body well-nourished and muscular. The calvaria is quite natural and no fracture of the skull can be made out. The sinuses are quite natural. The meninges are filled with blood. The dura mater is quite smooth on inner surface and free from exudation and false membranes. The hæmorrhage is most abundant at the base of the brain over the medulla and pons, around the circle of Willis and the Sylvian fissure. To discover the source of the hæmorrhage, water was thrown into the carotid; its first effect was to distend a small polypous-looking body attached to the anterior communicating artery, but the water did not flow out of the body. A further examination confirmed the suspicion that the body was an aneurysm of the anterior communicating. It is rough like a mulberry, and about the size of a

hempseed. No other disease of the vessels of the brain was found; and no source of the bleeding could with certainty be made out, as it could not be determined if the rupture near the crura from which water escaped were *ante-* or *post-mortem*.

The thymus gland was persistent. The œsophagus had become digested *post-mortem*, and the contents of the stomach were found in the pleura. The heart quite natural; no endocarditis or old clots. The rest of the organs quite natural; the kidneys on surface slightly granular, but the structure of the cortex was quite natural. The aorta was slightly atheromatous.

Aneurysm of the anterior communicating artery is somewhat rare. Lebert, ten years ago, could find only six cases published.[1] Since that time four others have been noted. One by Dr. Gee,[2] another by Dr. Greenfield,[3] and a third by Dr. J. A. Ormerod and myself;[4] but in all these the aneurysm was ruptured and had caused a fatal meningeal hæmorrhage. Dr. McDowall has, however, published a case in which the aneurysm did not burst, nor did the patient die of hæmorrhage; the patient was a lunatic.[5] In the present case the source of hæmorrhage was most probably a ruptured aneurysm which was undiscovered. *October 16th*, 1877.

---

18. *A case of thrombosis of the vena portæ, leading to cirrhosis of the liver, after thrombosis of the vena cava: with secondary acute nephritis and acute abscess in the right lumbar region.*

By Samuel West, M.B.

The following is in brief a resumé of the clinical facts of the case:—A young woman, previously quite healthy, was suddenly without any known cause attacked with pain and swelling of both her legs,

[1] Lebert, 'Berlin. Klin. Wochenscrift,' 1866, p. 345.

[2] Gee, 'St. Bartholomew's Hospital Reports,' 1871, vol. vii, p. 147.

[3] Greenfield, 'Trans. of this Society,' 1876, vol. xxvii, p. 2.

[4] Wickham Legg and Ormerod, 'St. Bartholomew's Hosp. Reports,' 1876, vol. xii, p. 239.

[5] McDowall, 'Lancet,' 1875, vol. ii, p. 202.

evidently thrombotic in nature. After lasting a few days a gradual improvement took place until, fourteen days after her first attack, she was seized again with similar symptoms in her legs but of a more severe character. At the same time her stomach began to swell, and three days later she had suppression of urine and several shivering fits. On the twentieth day of her illness she was admitted to the hospital in a state of high fever (Temp. 103·4°—104·8°) and great distress. The diagnosis was made of thrombosis of the lower part of the vena cava inferior with acute nephritis, probably secondary to the thrombosis, and ascites. Under active treatment, with quinine and digitalis, the fever abated, and the signs of thrombosis of the lower extremities gradually in great part disappeared. The nephritis, however, persisted, and the ascites gradually increased, and with it large veins developed upon the abdomen. It was now evident that thrombosis had also occurred in the portal vein. The patient's condition, however, remained fairly good till the twelfth day after admission, when the signs of fever returned suddenly, the ascites developed more rapidly, and the pain which up to this time had been slight in the right lumbar region, became extremely acute. For fourteen days more there was but little change, but that little was for the worse, when suddenly the symptoms became so urgent that paracentesis abdominis was performed. Great relief followed the operation for the time; but the patient gradually sank, and two days later died exhausted.

The view of the case taken during life was confirmed by *post-mortem examination*, and I take this opportunity of acknowledging the courtesy of Dr. Wickham Legg in placing the results of this *post-mortem* at my disposal.

Post-mortem examination.—Body fairly nourished. Abdomen much swollen. Considerable swelling of right thigh and leg, less of left. Lineæ albicantes on the abdomen, and on calf of right leg, and on upper part of both thighs. Slight excoriations on inner side of thighs and on genitals. Slight mucous discharge from vagina. Hymen intact, and having an opening not larger than a fourpenny piece.

Brain and its membranes normal. Pharynx, larynx, and trachea, normal. Diaphragm pressed upwards considerably into the cavity of the thorax, displacing the heart upwards, and compressing the lungs. These were, with exception of some hypostatic congestion at both bases, healthy. The right pleural cavity was obliterated by

adhesions between its two surfaces. The left contained about 3 oz. of clear reddish serum.

The abdomen contained a large quantity of clear, straw-coloured serous fluid, but there were no traces of any general peritonitis, The veins in the whole peritoneum, in the mesentery, and in the omentum, were considerably dilated, and in some of those of the omentum there were non-adherent clots. The anastomoses between the branches of the portal vein and the parietal veins, were represented by dense plexuses of distended veins on each side of the spine, from which large veins ran forward and upward beneath the parietal peritoneum to join the dilated superficial vessels which were visible beneath the skin of the abdomen. These were most marked above the level of the umbilicus. A large vein of the size of a goose-quill ran to the umbilicus in the suspensory ligament of the liver.

On spreading out the mesentery all the radicles of superior mesenteric vein were found plugged with dense non-adherent but partly decolorised thrombi. A similar thrombus occluded the main trunk of this vessel, and was continued into the trunk of the portal vein and into its branches in the liver to their third or fourth divisions. The thrombus in the liver, in the portal vein, and for an inch or so in the superior mesenteric vein was evidently older. It was completely decolourised, slightly granular on the surface and showed signs of commencing softening, and in one place at the commencement of the portal vein, just above the entrance of the splenic vein, was a large irregular patch of softening, of the size of a big cherry, containing a creamy fluid, which, under the microscope, showed abundant rather granular pus-like cells. Into the splenic vein the thrombus extended only for about half an inch; nowhere was it adherent nor were the walls of the vein thickened or altered. The liver was very small, left lobe only 4 inches and the right 6 inches in the antero-posterior diameter. Surface uneven; dotted with granules about the size of peas. On section these granules, yellow and evidently fatty, were separated from each other by a broad meshwork of pale, semi-transparent dense connective tissue.

Gall bladder distended with bile; ducts patent. Spleen large, 6 inches long, soft, Malpighian bodies prominent. Stomach and pancreas natural.

The cœcum was found to be adherent, and on dissecting it away a large quantity of creamy non-fetid pus escaped. This came from a

large abscess cavity about 6 inches long occupying the whole of the right iliac and lumbar region behind the peritoneum and behind the kidney. It was crossed by some vessels and nerves, and its walls were irregular and eroded. There was no thickening or sign of chronic inflammation in them. No necrosed or bare bone could be discovered, and the vertebræ were quite healthy; nor was any disease found in the spinal canal to account for this abscess. Kidneys weighed 9½ ounces, and were in the fatty stage of acute nephritis, but the cortical portions were not very much increased in size. The intestines, large and small, fairly natural.

The whole vena cava inferior was occupied by a soft red *post-mortem* clot, which extended into the right auricle. It was of quite recent formation and contained no nucleus of old clot.

In the left common iliac vein, just before its junction with the right to form the vena cava, a laminated, decolorised, dense thrombus was discovered, of the size of a sixpenny piece, not adherent to the wall, but attached by a pedicle of the same character, which, on dissection, was found to extend down a small vein at the right side of the sacrum, and to terminate just where a varicose pouch as large as a pea was situated. This pouch was empty of clot, but the whole vein was completely filled by a dense adherent clot, which had apparently undergone some canalization. About ½ an inch from this pouch a small patch of cheesy substance lay in the peritoneum, but no direct connection between it and the pouch was traceable. Uterus virgin; ovaries normal. Heart and aorta normal. Suprarenal bodies normal.

A microscopical section of the liver showed the changes usual in a well-marked case of ordinary portal cirrhosis, and presented no peculiarity other than that the fibrous tissue contained a large number of small round cells. The case, as a whole, raises several questions of considerable interest and difficulty. First, what was the cause of the thrombosis? and in what relation does the thrombosis of the vena cava inferior stand to that of the portal vein? The history proves that the thrombosis of the portal vein was secondary in point of time to that of the vena cava. The thrombosis of the latter vessel was determined by the old clot in the left common iliac vein; but the cause of the original thrombosis in the small sacral vein is still obscure, unless it be connected with the caseous patch in its neighbourhood; while the absence of any change in the walls of the veins, and of any other known cause for throm-

bosis, taken with the development of an independent clot in the portal vein, makes it necessary to assume some more general cause, of the nature, probably, of some blood change.

Next; in what relation does the nephritis, and the abscess in the right lumbar region stand to the thrombosis of the vena cava? The history points distinctly to the development of urinary trouble not earlier than fourteen days after the commencement of the illness; and although the patient stated that she had at first some slight swelling of the face and hands, yet this very quickly subsided, it never recurred, and it seems difficult to believe that an ordinary nephritis of so acute a character could run its course without marked œdema of the face and hands, especially as the position the patient occupied in bed was just that to favour most the development of these symptoms. The abscess also in the right lumbar region was in all probability, both from the pathological evidence and from the history of the case, of acute and not of chronic origin, so that I am inclined to regard both the nephritis and the abscess as secondary to the thrombosis of the vena cava, and produced by it.

I have reserved to the last the most interesting point in connection with this case, viz., the relation of the cirrhosis of the liver to the obstruction of the portal vein. I believe that the cirrhosis was secondary to, and produced by, the thrombosis in the portal vein; but to establish this it is necessary first to prove the absence of antecedent cirrhosis in this case, and secondly to show that portal obstruction is capable of producing cirrhotic change in the liver. Thrombosis of the portal vein occurs in most cases in connection with previous disease of the liver, and is usually the last link in a long chain of severe and rapidly fatal symptoms. But all evidence of previous hepatic disease is entirely wanting in this case. The girl was young and healthy until two months before her death, and she had been exposed to none of the influences likely to induce cirrhosis of the liver, and, moreover, the first signs of portal obstruction developed late in her illness, so that without the thrombosis we should have had no ground for suspecting disease of the liver.

With reference to the second point it is generally admittted that the thrombosis of a branch of the portal vein is followed by atrophy and cirrhosis of that part of the liver which it supplied,[1]

[1] 'Frerichs on the Liver,' Syd. Soc., ii, 396; cf. Atlas, plate xii, 4. Budd, 'Dis. of Liver.'

and we may, therefore, assume that complete obstruction would lead to complete cirrhosis if life were preserved long enough. But obstruction of the trunk of the portal vein is in most cases speedily fatal,[1] so that the amount of pathological evidence to support this theory would be small. In looking up the literature of the subject I have been able to find only five cases of this kind on record.

I.	A case of	Dr. Dickinson[2]	*Duration*	4 months.	*Liver* atrophic, 28 oz. (No mention made of granules).
II.	„	Dr. Balfour and Dr. Grainger Stewart[3]	„	2 months.	*Liver* cirrhotic, 31 oz. { Right lobe 9½ inches long. Left lobe 2 inches long.
III.	„	Prof. Gintrac	„	2 months.	*Liver* granular. (Measurement 9½, × 4½ × 1½.)
IV.	„	Prof. Botkin[4]	„	„	*Liver* granular.
V.	„	Dr. Monneret[5]	„	5 weeks.	*Liver* size of two fists, not granular.

This small amount of experimental evidence which we have tends in the same direction. Dr. Solowieff found that ligature of the portal vein in animals was followed by a development of fibrous tissue along the branches of that vessel; and he describes one or two cases in which the animals lived one or two months after the operation, and in these the liver was hard and fibrous, although large and apparently not cirrhotic. The kind of cirrhosis which we have in the liver in the present case, viz., the large granular form, agrees exactly with that described by Prof. Charcot as always occurring in cirrhosis of portal origin.

So that in favour of the view taken of this case that the cirrhosis followed portal obstruction, we have, in addition to the clinical and pathological evidence from the case itself, first, the fact that partial cirrhosis does follow partial obstruction, secondly, a certain amount of experimental evidence, and lastly, a few clinical cases in which this was thought the only admissible and the best explanation.

February 19th, 1878.

[1] Dr. Murchison on Liver, "Obstruction of the trunk of the portal vein in most cases is speedily fatal, but if it be not it leads to Atrophy of the Liver." Drs. Hilton Fagge and Wilks' (Cases), 'Pathol. Soc. Trans.,' xxvii, 124.

[2] 'Path. Soc. Trans.,' xiv, 63.

[3] 'Edin. Med. Journ.,' xiv, p. 389.

[4] 'Virch. Arch.,' 1864, p. 449.

[5] 'Union Medicale,' 1849, *quoted* Henoch, 'Klinik d. Unterleib. Krankheiten,' 1852.

IV. DISEASES, ETC., OF THE ORGANS OF DIGESTION.

(A) DIGESTIVE CANAL.

1. *Spontaneous rupture of the œsophagus.*

By WILLIAM ADAMS.

THE patient was a gentleman, æt. 58. He had been dyspeptic for several years, and occasionally vomited after food. On the day of his death he appeared unusually well, and went out on a pleasure excursion. He returned to his dinner in the afternoon, and ate heartily of rump steak. About two hours after his dinner he complained of faintness and left the room. Soon afterwards he was heard retching in the water closet, and then to utter a shriek.

He returned to the dining-room pale as death, and threw himself upon the sofa, complaining of great pain in his left side and left shoulder.

Within a few minutes he was seen by Mr. Mahony, a neighbouring surgeon, who found him in a cold sweat, breathing quick and short, his pulse 122, and his face expressive of agony. He kept his left hand firmly pressed upon his left side, where he complained of severe pain extending to the point of the left shoulder.

He died seven hours after the sickness.

Post-mortem.—A slit was found in the œsophagus ¼ inch in length, immediately above the diaphragm, and the left pleural cavity contained about a pint of undigested food, amongst which was a piece of gristle of beef, an inch and a half long by half an inch broad, which I imagine to have been the agent which caused the rupture.

The œsophagus is observed to be thin and its structure unusually weak, and the same may also be said of the cardiac end of the stomach, while the pyloric end is observed to be thickened from some morbid change in its structure.

I have brought the specimen here, because it would appear to be a very rare accident, and an uncommon cause of death. One case only is recorded in the Society's 'Transactions,' that one is described by Dr. J. C. B. Williams in the first volume. The facts connected with that case are very similar to those I have just related; the patient vomited after dinner, and died in thirteen hours. The rupture, as in this case, was immediately above the diaphragm, and the contents of the stomach were found in the left pleural sac.

May 21*st*, 1878.

Report of the Committee on Mr. Adams's specimen of spontaneous rupture of œsophagus.—We have examined the specimen submitted to us and beg to make the following report.

In the posterior wall of the œsophagus, immediately above the diaphragm, was a longitudinal slit, an inch and a half in length. Above, it only extended through the mucous submucous coats; below through all the coats. The upper part had all the appearance of having been made with a sharp instrument, the edges being perfectly even and smooth. Below, this appearance was not so marked. Close beside the lower part of the rent was a small white fibrous cicatrix, of a stellate form, which was continuous by a linear prolongation with a smaller cicatrix situated below it.

The stomach showed manifest signs of previous ulceration; there was great fibrous thickening of the coats at the pylorus, and here there was a cicatrix on the mucous surface. There was a similar thickening at the lesser curvature, with another cicatrix on the mucous surface. The cardiac end was softened, probably from *post-mortem* digestion.

We think it probable that the accident took place in the manner supposed by Mr. Adams, the coats of the œsophagus having been weakened by previous ulceration.

The rent had probably been enlarged upwards by *post-mortem* manipulation.

W. Cayley,
W S. Greenfield.

2. *Imperforate anus.*

By EDWARDS CRISP, M.D.

THE child, a male, the subject of this malformation, was born October 3rd, 1877, and died October 6th (fifty-six hours).

The symptoms resembled those attending this kind of obstruction.

The child was taken to Dr. Haynes, of Chelsea, with whom I examined the body, but it was too late, Dr. Haynes thought, when he saw it, to warrant the performance of an operation.

As seen by the preparation the rectum terminates close to the anus, the bowel terminating in a large, thin cul-de-sac, which might have been readily divided with a good chance of recovery. Other organs normal.

Remarks.—In the twenty-fifth volume of our 'Transactions,' p. 115, I have recorded a very similar case, where the contents of the bowel might readily have been let out, and the child's life, I believe, saved. *November 6th*, 1877.

---

3. *Congenital occlusion of small intestine.*

By N. DAVIES-COLLEY.

ISABELLA P— was brought to Guy's Hospital on September 10th, 1877, four days after birth. The nurse who brought her said that on the 6th, the day on which she was born, there was a natural but scanty evacuation of the bowels. On the 7th she began to vomit, and had passed nothing per rectum since.

On admission.—The abdomen was swollen, and coils of intestine from time to time caused projections upon its surface. No tumour could be felt. Vomiting was frequent, and the matter vomited was like meconium. She could only take small quantities of milk from

a spoon, and was in a feeble condition. No obstruction could be detected in the rectum, which was of small calibre. Clear mucus escaped on the removal of the finger. A gum elastic catheter could not be passed more than two inches up the rectum. No swelling could be felt in any part of the abdomen. It was thought that the obstruction was high up, but the history made it doubtful whether this was the result of intussusception or congenital malformation.

I made a short incision in the abdominal wall, half way between he right anterior superior spine of the ilium and the umbilicus, and having sewn a distended portion of the small intestine to the sides of the incision, I made a small opening, through which a quantity of meconium at once escaped. She was relieved for a time and the vomiting ceased. The next day, however, symptoms of peritonitis appeared, and on the 12th she died, about forty-four hours after the operation.

At the *post-mortem* examination there was evidence of acute recent peritonitis. The small intestine was much dilated (diameter about 1¼ inches) down to about nine inches from the cœcum. Here it became suddenly very small. The rest of the ileum, and all the large intestine, were much contracted and flattened, and looked like a piece of tape (Plate V, *c*). There was no band or diverticulum connected with the point of constriction. On opening the bowel here it was found to be completely divided by a septum, *b*, lined on each side by mucous membrane. Two cul-de-sacs were thus formed, the blind extremities of which overlapped each other for about one sixth of an inch. The intestine below, comprising the remaining nine inches of the ileum as well as the colon, was about a quarter of an inch in diameter, and admitted with difficulty the tip of the little finger. It contained no solid matter, but a clear whitish mucus of semifluid consistence, which was not at all tinged with meconium. Above the septum the wall of the intestine was much thickened, whilst that below was blanched and thin. The aperture made by the operation, *d*, was two inches above the constriction.

Congenital occlusion of the small intestine appears to be very rare. I can find no record of a similar malformation in the 'Transactions.' In the 'Deutsche Zeitschrift für Chirurgie' for 1877 there is a collection by Theremin of cases of this description. He gives references to seven instances of similar malformation in the lower part of the ileum.

I do not know that any explanation has been given of the reason why this part of the intestine should be especially affected. Diverticula are most often found at the lower end of the ileum, and their origin is explained by the supposed persistence of a portion of the ductus vitello-intestinalis, which is here connected with the intestine. The position of the septum in this case would favour the supposition that it depended upon some abnormality in the obliteration of the duct during the fœtal development.

The diagnosis was rendered difficult by the positive assertion of the nurse that the baby had passed meconium shortly after birth. I am disposed to think that she must have made a mistake, as not a trace of it could be found in the colon after death. It has, however, occurred to me as just possible that the bowel was patent in the earlier part of fœtal life, and that some meconium had passed into the lower part before the formation of the septum.

November 6th, 1877.

---

4. *Ulceration of the bowel as a consequence of renal disease.*

By W. Howship Dickinson, M.D.

This case is an additional illustration of a morbid relationship to which I drew attention by the relation of two cases in the Croonian Lectures for 1876. These, together with a third which Dr. Greenhow was kind enough to send me, are referred to in the second edition of my work on 'Albuminuria,' published in the following year. The instance at present before the Society makes the fourth. The cases closely resemble each other. The patients were all the subjects of the granular kidney, and at an unusually early age; the eldest died at the age of thirty, the youngest at fourteen. In none was there any trace of tubercle, history of typhoid, or apparent cause for the ulceration, beyond the existence of the renal disease. The ulceration was in each instance in the same situation, the lower end of the ileum, and had penetrated the bowel so deeply as to set up localised peritonitis.

The subject of the present case, a clerk, died at the age of twenty. He had had scarlatina, followed by dropsy, at the age of six, after which he remained the reverse of robust, and subject to headaches and epistaxis, but without more declared evidence of organic disease until he reached the age of fourteen. He then began to experience loss of memory, an increasing degree of internal strabismus, and later, deafness of the left ear. These symptoms were succeeded by loss of flesh and strength, polyuria, dyspepsia, evinced by pain after food, and dimness of sight, which last symptom, noted three or four weeks before his admission, brought him at last to the hospital. Mr. Brudenell Carter at once recognised advanced albuminuric retinitis, and remitted the patient to my care. He had always been temperate in drink.

On January 17th of the present year, when he came under my observation, he was of small growth, pale, emaciated, and without œdema. His sight was dim, so that he could not read, though he could distinguish large outlines. He was slightly deaf on the left side, and suffered from wakefulness. The urine was pale, abundant, with a specific gravity of 1011, and highly albuminous; it contained granular casts of large size. The cardiac dulness was somewhat increased. The first sound was accompanied with a murmur at the base apparently hœmic, and the second sound was exaggerated into a remarkable metallic clink. Another remarkable sign of tension was found in the extraordinary hardness of the pulse, which was without precedent in my experience. It felt like an unchanging bar, and indeed no force which could be applied in the ordinary way of feeling the pulse sufficed quite to stop it. The bowels had been, and were, constipated. There was complaint of rather severe, intermitting pain below the umbilicus, which was always made worse by eating or drinking; the place of pain was somewhat, but not excessively, tender. With this were nausea, want of appetite, and occasional vomiting. The pain, though not constant, became more severe, and though it appeared to be often of a griping character, the localised abdominal tenderness became more marked, and notwithstanding the general constipation, mucus was sometimes passed with the motions, and I ventured to class the case, though upon clinical evidence only, as belonging to the rare category of renal ulceration of the small bowel. The pain became more severe, and the patient wore haggard and sharp features, his tongue became coated with a thick yellow fur, appetite totally failed, the pulse ceased to be hard,

and he sank, without any of the more common uræmic symptoms, on February the 5th.

Post-mortem examination.—The body was examined in my presence, by Dr. Ewart, the Curator, from whose report chiefly the following particulars are obtained.

The body was much emaciated; it was free from dropsy.

The peritoneum contained a small amount of purulent fluid. In the hypogastric region and pelvis some soft adhesions glued together a few intestinal coils and the edge of the omentum; on raising the latter a small perforation was unmasked, from which issued fæcal fluid. On examining the bowel from above downwards the duodenum, the jejunum, and the upper part of the ileum, were healthy. The lower half of the ileum was of a dark colour, partly from congestion, partly from pigmentation. The pigment, which was perfectly black, was found to be deposited in the submucous tissue in patches and transverse stripes, and imparted to the bowel an appearance not unlike the alternate slate and black tinting seen in the lung. Small ragged ulcerations occurred in rather close succession on the mucous surface of the lower two thirds of the ileum; they were irregularly circular, non-elevated, and generally, though not exclusively, occupied the portion of the bowel opposite the mesentery, not spreading over more than one fifth of the circumference.

The whole mucous surface presented a sodden aspect, which at first simulated the appearance of a false membrane, through which the dark-coloured bowel could be seen. No film could, however, be detached from the mucous surface.

Looking at the ulcers in more detail it was found that they generally occupied Peyer's patches. In size they seldom exceeded the section of a pea; most of them were smaller than this. They were clean cut as if punched out. There was no attempt at repair about them, and in many places the unthickened peritoneum was the only barrier between the peritoneal cavity and the inside of the bowel. Three of the ulcers had perforated all the coats.

Mr. A. Shann, my former excellent clinical clerk, made some good sections of the ulcerated bowel, the most striking condition displaced by which was a quantity of yellow grains of pigment, apparently little removed from crystals of hæmatin, which lay in large groups in the submucous cellular tissue of the affected parts of the bowel.

The colon presented in a less degree the same pigmentation, and a good deal of mottled congestion and ecchymosis. There was no ulceration in any part of the large bowel.

Some of the mesenteric glands were swollen and calcified.

The kidneys were contracted and granular. The pair weighed 8 oz. They were somewhat light coloured or mottled on surface and in cortex. Some sections, prepared by Mr. Shann, were exquisite examples of the interstitial fibrosis, large traces of nucleated tissue compressing and displacing the proper glandular structures.

The pericardium was very delicate and transparent.

The heart weighed 15 oz; this large size, compared with the small stature and attenuation of the subject, was apparently wholly due to hypertrophy of the left ventricle, which was quite free from superficial fat, contracted, and nearly empty. The right ventricle was natural, as also were all the valves. The aorta was normal.

The arterioles, as displayed in the pia mater, were examined with the microscope and compared with healthy vessels similarly obtained and prepared. The coats were thickened, but not so extravagantly as is sometimes seen, and as the extraordinary increase of tension might have led one to expect. The arterial wall was generally about double, or rather more than double, the normal thickness. Both muscular and fibroid coats were increased. There was little trace of fatty or other degeneration.

The lungs were natural, save that some marginal emphysema existed, together with some patches of œdema and congestion. There was no tubercle here, or indeed anywhere. At the apex of the right was a small cicatricial mark, not coupled with any induration of the lung tissue.

The liver was somewhat firm, and its lobulation accentuated, apparently from some excess of fibroid material; it was otherwise natural, as also were the spleen, supra-renal capsules, and the remaining abdominal structures.

The cavities of the cranium and brain contained some excess of watery fluid. A small spiculum of bone was found on the arachnoid on either side of the longitudinal sinus; the brain tissue was generally pale, and two small patches of shotty induration were found in the left hemisphere, but these abnormalities would have escaped notice had not the brain been examined with more than ordinary care.

Remarks.—In each of the four cases to which I have made reference the granular kidney of fibrosis was associated in a marked manner with the cardio-vascular changes which often lead to extravasation of blood; there was much hypertrophy of the heart in each instance, and in each there was the failure of sight which indicates that the retina is involved. One case occurred before the ophthalmoscope was in use, but with the three others the retinal changes were characteristic, and in two gave rise to the symptoms which first attracted attention. Thus, in every case the conditions which lead to, and those which indicate, hæmorrhage were strongly declared. And the condition of the bowel in the instance before the Society was such as to suggest that the bowel ulceration is but another member of the hæmorrhagic series. Not only was there extensive pigmentation, possibly the result of hæmorrhage, but the laminar accumulations of hæmatin granules in the submucous tissue in the neighbourhood of the ulcers, as shown in Mr. Shann's sections, could not be regarded otherwise than as records of extravasation. And I may refer to one of the cases formerly related in which the bowel about the ulcers was the seat of recent ecchymosis ('Albuminuria,' second edition, p. 200).

It is not impossible that what may be termed *albuminuric ulceration of the bowel* may attract notice in the future with more frequency than has happened in the past.

It is not my object to dwell upon the other points of interest which this morbid series presents. As an instance of the fibrotic or granular kidney, as a late result of scarlatina, the case falls into a distinct and well-marked group. The history of the case indicates that the hypertrophy of the heart and arteries, with the attendant fibrotic thickening of the latter, is to be considered in this instance as a consequence of the renal disease rather than as collaterally associated with it. *May 7th*, 1878.

5. *Case of acute intestinal obstruction; perforation of a diverticulum.*

By Alban Doran.

For this specimen I am indebted to Mr. W. E. Hacon, of the Bedford General Infirmary.

The patient was a male child, æt. 4. On the 11th of July, 1877, he was seized with vomiting and pains in the abdomen after his dinner. During that meal he had eaten peas well boiled, but his mother had reason to believe that he had swallowed raw peas in the morning. Mr. Cottingham Johnson was called in and ordered a drachm of castor oil to be given to the patient. Next day the vomiting had stopped, but the abdominal pain had increased and the bowels had not acted. Small doses of opium were administered. On the fourth day vomiting recurred and was stercoraceous; an injection brought away a scanty motion. The child died suddenly in the afternoon.

A *post-mortem* examination was made by Mr. Hacon. The abdomen was much distended; the peritoneal cavity was full of gas with extravasated fæces. The small intestine was obstructed at one point, where a diverticulum was discovered, which was perforated and contained a pea. Recent plastic lymph was effused around the perforation. The pea discovered in the diverticulum was soft and partly macerated by digestion, but several very hard peas were found in the large intestine.

The specimen here exhibited consists of a few inches of small intestine, including the diverticulum. Mr. Hacon carefully records the fact that this portion of the intestine is a part of the jejunum; but the valvulæ conniventes are ill-marked so that the disease must be considered as situated almost in the ileum. The pouch consists of all the coats of the intestine; it is about an inch in length, pyriform, with the broader end downwards. The line of attachment of the mesentery runs close to one side of the diverticulum, and it is very intimately connected with its dilated lower extremity. At this point the mesentery is thickened and possibly blended with the remains of the cord-like projection seen at the end of many diver-

ticula, but not distinct in this case. At a point rather nearer to the upper than to the lower end is a large perforation, more than an eighth of an inch in diameter, and almost circular; its edges are very sharply defined. The valvulæ of the intestine are continued over the mucous membrane of the interior of the diverticulum; the pea was lodged in the wide lower extremity of that pouch. Half an inch below the diverticulum the intestine suddenly becomes narrow, dilating again considerably immediately below that point. There is absolutely not a trace of thickening of the intestinal walls of any morbid deposit at the seat of the stricture. But the mesentery between that point and the lower end of the diverticulum being thickened looks as if it had become contracted, and thus narrowed the calibre of the intestine These are some patches of inflammatory exudation on the surface of the diverticulum.

This pouch is evidently a true congenital diverticulum, and not a "distension-diverticulum" of the type once exhibited before this Society by Drs. Hilton Fagge and Goodhart. The distension below the seat of contraction as well as above is possibly due to impaired peristaltic action close to the stricture, which would permit accumulations of ingesta. Cases of perforation of diverticula have been previously recorded. One example is given by Dr. J. Galton in vol. xxiii of the Society's 'Transactions;' it occurred during typhoid fever. *November 6th*, 1877.

---

6. *Two specimens of epithelial cancer of the rectum.*

By W. H. Cripps.

The first specimen consists of a cancerous mass of about four inches in circumference and half an inch thick. It occupied the posterior half of the rectum, its lower margin being an inch from the anus. Its central part was ulcerated, giving a crater-like appearance to the mass; the margin of growth terminated somewhat abruptly in the sound tissue.

Microscopic examination showed the mass of the new growth to

be between the mucous membrane and the muscular coat. The mucous membrane was destroyed over the centre of the growth, but the membrane showing Lieberkühn's follicles, hypertrophied to double their usual extent, was still perfect at the margin of the disease. The new growth consisted of a mass of small cell-growth, the cells being identical with the cells of the retiform tissue existing between Lieberkühn's follicles. In the deeper portions of the growth a mass of large, irregular, epithelial-looking cells existed, arranged here and there in such a manner as to suggest a reproduction of the mucous follicles in the deep tissue.

The mass was removed during life, and the patient has continued well ever since—eighteen months.

2. *Cancer of the rectum, with secondary deposit in the liver.*—In this specimen a stricture four inches above the anus existed; the stricture was so tight as scarcely to admit the tip of the finger. The stricture felt like a cord tied tightly round the bowel external to the mucous membrane. In the hollow of the sacrum a large cancerous mass existed, having caused absorption of the coccyx and lower part of the sacrum.

The cause of the stricture appeared to depend partly upon a ring of cancerous matter in the cul-de-sac of the recto-vesical pouch, but principally due to some fibrous bands extending around the rectum and being drawn downwards into the substance of the cancerous mass behind. On dividing these bands the stricture was much loosened. The symptoms of disease had clearly commenced in the rectum, the large mass behind the rectum not appearing until a year after the disease in the rectum was first noticed, and was doubtless due to infection of the lymphatic gland often found in that situation. The liver weighed 8 pounds and contained white masses of cancer, varying in size from mere specks up to masses three or four inches in diameter. Microscopic examination of these masses showed in one or two spots at their margins an arrangement of epithelium on a decidedly follicular plan. Some of these were somewhat similar to greatly enlarged Lieberkühn follicles, as seen on cross sections, and the specimen appeared somewhat like that depicted by Dr. Mahomed in the 28th vol. of the 'Transactions,' p. 144 (1877). *November 6th*, 1877.

7. *True diaphragmatic hernia.*

By George Garlick, M.D.

Mary Anne W—, æt. 2½ years, admitted June 2nd, 1877, into the Hospital for Sick Children, Great Ormond Street, under Dr. Cheadle.

The following history was given by the mother. When carrying this child she was very weak, and thought to be consumptive. When three months gone she had a fall on her back, but nothing of consequence. The child was born at full time and was considered small; she was always weakly, and at six months caught cold and coughed severely for some months. When 1½ years old she had a severe attack of vomiting, lasting for at least three days and four nights, and recurring almost every quarter of an hour; the bowels at the time were obstinately confined and the stomach gradually sank in. After the cessation of the vomiting the child recovered rapidly, and appeared, the mother states, improved in health. There was no return of the vomiting, but she often complained of feeling sick and of pains in the belly and epigastrium; would not take much food at a time.

At two years the child ran, did not appear short of breath, and had no attacks of dyspnœa. The bowels were habitually confined, but not remarkably so; motions costive. The child remained in much the same state till five days before admission into the hospital; the day previous to this she had been taken to school for the first time, and screamed for a long time, but nothing unusual was observed till the following day in the afternoon, when vomiting set in about six times in the first twelve hours, but subsequently recurring almost hourly, day and night, for four days; there was extreme thirst, the child drinking greedily of water, and taking quite half a pint at a time, but vomiting it shortly after, frequently screaming before the vomiting set in. There was obstinate constipation and retraction of the abdomen.

When admitted, the child was in an extreme state of collapse, with a frequent small pulse, pinched expression of face, and deeply sunken eyes; abdomen much retracted. Tongue quite clean,

constant vomiting, nothing being kept down. She died within six hours of admission.

Examination forty-two hours after death.—Height 3 feet 2 inches. There is a marked pigeon breast, the right side being more prominent in front than the left.

In the right plural cavity, on opening the chest, there is seen to be a tumour, the size of a small orange, continuous with the diaphragm and accurately surrounded by the base of the right lung, which organ is hollowed out to receive it. This tumour is the sac of a hernia, and is composed of the attenuated tendinous and muscular tissues of the diaphragm, together with a lining of peritoneum and a covering of pleura on its thoracic aspect. It contains the pyloric end of the stomach, which slips out of its sac with the greatest ease, there being no adhesions between the two.

The mouth of the sac is situated to the right of and close to the aperture in the diaphragm for the passage of the œsophagus. In front and to the right is the liver, which organ has been tilted forward by it, the falciform ligament being elongated and the anterior edge of the organ depressed. The mouth admits readily three fingers and thumb, but its elasticity allows of much further extension. The stomach is large, and all there is to indicate the displacement of its pyloric end is a notch in the middle of the great concavity about $\frac{1}{8}$ inch deep, and slight thickening and irregularity of the peritoneum about the middle of the smaller curvature. There is no congestion of any part of the organ; the first part of the duodenum appears freely movable.

The right lung is considerably smaller than the left, thus making up for the extra mass situated on the right side of the chest, and so complete is the adaptation that there is no displacement of the heart to the left. The chief part of this diminution of the right lung is in the size of the lower lobe, and this does not proceed from any collapse of that part, which is quite natural to the base. The vertical measurement of the left lung is $4\frac{5}{8}$ inches; that of right $2\frac{7}{8}$; showing a difference of $1\frac{3}{8}$ inches.

Remarks.—The question suggests itself as to the duration of this hernia, and I think there is evidence to show that if not congenital it had probably been in existence some time. The attack one year previously, identical in character with that of which the child subsequently died, make it pretty certain the hernia was then present. The complete adaptation to the tumour of the right lung, together

with the smallness of that organ, and the prominence of the right front of the chest, all point to a chronic condition. The complete absence of adhesions and of cicatricial tissue show that the process proceeded quietly. Whether the condition was actually congenital there does not appear evidence to show, but in the case of a fœtus mentioned by Morgagni,[1] the stomach, spleen, part of the liver, duodenum, and omentum, had escaped into the left cavity of the thorax, the left lung being only composed of one lobe.

The length of time that life may be supported with a phrenic hernia is shown by a case reported by Dr. Bright,[2] in which a young woman, aged 19, died, with obstinate vomiting coming on after exertion, in whom the first of many similar attacks had occurred eighteen years previously.

Morgagni also relates the case of a man who died in old age from injury to the skull, and in whom part of the colon was carried through the middle and anterior part of the diaphragm, there being no evidence of injury.

The essential causes in the production of these herniæ, as in abdominal herniæ generally, are, firstly, compression of the contained viscera by the abdominal walls, and, secondly, some local weakness in those walls. But in the case of diaphragmatic herniæ there appears to be another factor introduced, viz. atmospheric pressure, which must have tended to stretch the yielding part of the diaphragm, just as it had pressed in the external thoracic walls, producing the pigeon breast, when by expansion of the chest the air pressure inside was lessened. Cases of diaphragmatic herniæ, whether of traumatic or idiopathic origin, end fatally either with increasing dyspnœa, the herniæ largely and rapidly increasing, or with vomiting and collapse.

January 4th, 1878.

[1] From the 'Oph. Nat. Cur.,' book iv, sect. 54. Alexander's Translation, vol. iii, p. 206.

[2] 'Guy's Hosp. Reports,' vol. i, p. 60.

(B) DISEASES OF THE LIVER.

8. *Aneurysm of hepatic artery in the cavity of an abscess of the liver; perforation of the stomach and rupture of aneurysm into it.*

By J. Pearson Irvine, M.D.

This unique specimen was removed from the body of a commissionaire, æt. 45, who, after nineteen years' service, was discharged from the army about twelve months before his admission into the Charing Cross Hospital, on October 10th, 1877. In this hospital he was under the care of my friend, Dr. Green, to whom I am indebted for the chance of showing the specimen. His family history was exceptionally good, he had lived a sober life, and had not had syphilis. In India, where he was stationed twelve years, he suffered from diarrhœa (? dysentery), had "fever and ague," and most of the minor ills endemic in his different stations.

He had acted as commissonaire in the City from the time of his discharge, and from the first thought his health was failing, but it was not till six weeks before admission that he felt decidedly ill. He then began to experience "swelling" after food, a perversion of taste leading to disinclination to food, and a peculiar throbbing in the epigastrium, a little to the left of the middle line and just below the margin of the ribs. He had no severe pain; the throbbing was irregular, coming and going capriciously, and not affected by food. He had no dysphagia. A month later (a fortnight before admission), when on his way home from the City, he felt a sudden coldness, and immediately fainted away. On coming to he found himself lying in the street with a pool of blood near him, and his notion was that he had vomited the blood; he could not be certain, because he had no warning of the attack, and simply fell down unconscious. He was of course much prostrated, but recovered rapidly. However, six days afterwards he fainted again, this time less suddenly and less severely; he did not bring up any blood. A

few days before admission he had a recurrence of the severe attack with hæmatemesis. There was no history of rigors, of dyspnœa, or of œdema, and none of vomiting, prior to the above-mentioned attacks. He had experienced no acute pain in the epigastrium, nothing beyond that attending a sense of distension after food. The history was, in short, one of hæmatemesis of most obscure origin.

The patient was examined by Mr. Claremont, house physician, soon after admission. There was at this time a distinct, localised fulness, with a sense of resistance in the mid-epigastrium, but next day this was gone. Thirty-six hours afterwards the patient passed blood (changed and tarry) by the bowels, and melæna continued for some days. He did not vomit blood, but had quasi-convulsive seizures and attacks of fainting, requiring the exhibition of brandy. The man from the first was blanched, and his mucous membranes were bloodless. He complained of thirst and of unpleasant tastes, his tongue was covered with a thin, white fur. He asked for nothing but liquid food.

From the date of his admission up to the time of his death, on October 25th, 1877, he had several attacks of fainting, followed after an interval of many hours, by the passage of blood by the bowels, which were usually constipated—so much so that enemata of olive oil required to be administered. Shortly before death, which occurred suddenly, he had a slight attack of hæmatemesis, and complained of pain in the left epigastrium. Physical examination had been for some time impossible, for the slightest handling caused excessive pain.

On *post-mortem* examination (October 27th) the thoracic viscera were found to be healthy with the exception of a firm adhesion (evidently of long standing) between the pulmonary and diaphragmatic pleuræ on the right side. The abdominal cavity seemed natural and free from peritonitis and bloody effusions. The stomach was distended and adherent to the under surface of the left lobe of the liver, this lobe on casual inspection giving one the notion that the organ was cirrhosed. The adhesions between the posterior wall of the stomach and liver extended over an area the size of a crown-piece, and were not thick, though moderately firm. After removal of the organs *en masse*, and careful dissection, it was found that in the liver there existed an abscess, the size of a small orange, on the lower surface of the liver, and completely superficial. It contained

a quantity of thick pus, free from odour, and of a greyish colour, and to its external wall the stomach was adherent. The latter was perforated; there was a punched opening through all its coats in the centre of the adherent part, the edges of this opening being rounded and smooth, and free from any sign of recent ulceration. The opening was about one-eighth of an inch in diameter externally—less in diameter at its termination in the mucous surface, the exact opposite of what is found in ordinary ulcer of stomach. The stomach contained a blood-clot, moderately firm and darkened by the action of acids, about three inches long, by one wide and deep. Its mucous membrane broke down readily, but there was no recent or old extravasation into it.

The abscess in the liver was bounded, except at the lower surface, by firm, fibro-fatty walls, one quarter of an inch thick, and its inner surface was comparatively smooth, and not indicative of any recent or rapid destruction. On the roof of the abscess and extending into its cavity was found what seemed to be a blood clot, attached to its walls, but which, on more careful examination, proved to be an aneurysm with a consistent wall, which had grown in the direction of the adhesions between the stomach and liver. This aneurysm was the size and shape of a large almond, and contained moderately firm, dark clot, and sprang from a branch of the left hepatic artery, capable of admitting a small probe. The liver was not enlarged generally, and showed signs of an early cirrhosis; the extreme left lobe was hard and firm, granular on the surface and on section.

The right lobe, too, hard but not granular, was more or less "nutmeggy;" the spleen was a little tough, and weighed five and a half ounces. The kidneys were harder than natural. There was no trace of embolism anywhere.

The specimen is worthy of notice not only as a pathological curiosity, but because of certain analogies which it possesses, and even for clinical reasons. The occurrence of an aneurysm in the cavity of hepatic abscess is exactly similar to the same changes in the vessels traversing vomicæ in the lungs, which, though now so frequently met with, were, until quite a recent period, passed by. There can be no doubt that this aneurysm was due to the loss to the vessel from which it sprang of the normal tissue support, just as in pulmonary cases, and that the accident of aneurysm caused the death of a patient, who might otherwise have lived for years with his abscess quite harmless and latent.

The study of this case is interesting when looked at in the light of what we know of the fatal effects of small aneurysms in the lungs, brain, and elsewhere. In the brain it is far from uncommon to meet with small aneurysms of the size of a split pea or bean, on small vessels—such, for example, as the arteries of the corpora striata—and to have sudden death from their rupture. In the lungs, as in the case I now report, undoubtedly the aneurysms are due to loss of external support, and even in the brain there is doubt whether this does not sometimes occur. At a recent meeting of this Society, Dr. Hilton Fagge questioned whether in certain cases of cerebral aneurysm, associated with hæmorrhage, the aneurysms were not secondary to softening of tissue about the vessels, and much certainly can be said in favour of his views. The appearances of the tumour in this case indicates that it must have been supported in great measure by the firm walls of the abscess, for it accurately fitted into depressions, &c., and I cannot but think that its ultimate rupture was due to the fact that it grew in course of time towards the surface of the liver (in the abscess) and by pressure perforated the slightly adherent wall of the stomach, which gave little support, so that it yielded with a fatal result. Had there been on the superficial wall of the abscess a thick growth as there was in its deep wall, very likely the aneurysm would have been filled by firm clot, and have been permanently cured.

At the last meeting of the Society I showed an aneurysm of the cœliac axis (*supra*, p. 85), which was most probably due to disease of the external coats of the vessel produced by abscesses around them, and to loss of external support of tissues. In that case, as in this, there was no disease of the internal coats, except in the immediate neighbourhood of the aneurysm.

Clinically the case is of value. A "provisional" diagnosis was made of ulcer of the stomach, but the possibility of aneurysm of the cœliac axis (or its branches) which had ruptured into an adherent stomach, was discussed, and it is interesting to note that the group of symptoms given by authorities on hepatic aneurysms (Drs. Frerichs and Murchison among them) were met with here. Severe pain was, however, not a marked symptom, though tenderness did exist.

It is further interesting that a tumour in the epigastrium was detected shortly after the patient's admission, and a note made

thereof, and that next day this had completely disappeared. Very probably this tumour, or localised fulness, was due to surcharge of the abscess with blood, which shortly escaped into the stomach. For some hours afterwards, with the disappearance of the tumour, blood passed by the bowels, so changed that it had clearly come from a high part of the intestinal tract. The case illustrates the vast difficulty of diagnosing some abdominal diseases, but it is the accumulation of facts touching abdominal obscurities and an inquiry into them which must ultimately help us.

It is perhaps not out of place to refer to the occurrence of aneurysm of the hepatic artery *outside* the liver. There is no instance recorded in the Society's 'Transactions,' though an atheroma of the vessel is described. In the exhaustive writings of Dr. Murchison and Frerichs only five instances are collected, so that the lesion must be very infrequent, and one of the five, Dr. Murchison points out, was really aneurysm of the abdominal aorta. Within the last few months Dr. Ross, of McGill University, has recorded an aneurysm of the right branch of the hepatic artery (*outside* the liver) associated with a suppurative hepatitis, ascribed by him to embolism. Possibly cases similar to the one I show may be less rare than is supposed; and, as was pointed out by the President (Dr. Murchison), the question has an important clinical bearing, for frequently in tapping hepatic abscess severe hæmorrhage has occurred, which may have been associated with small aneurysms in the abscesses. However, this is the first instance of an aneurysm in an hepatic abscess which has been placed on record.

November 20th, 1877.

---

9. *Small aneurysm of the coronary artery in an ulcer of the lower curvature of the stomach.*

By R. Douglas Powell, M.D.

This specimen was removed from a man, æt. 44, who was in the Brompton Hospital under the care of Dr. Reginald Thompson in Dr. Tatham's absence. The clinical history of the case is briefly as follows:—

This patient had been ill for some months with phthisis, and on October 17th, 1877, about a month after his admission into the hospital, Dr. Thompson kindly asked me to see him on account of his having expectorated more than a pint of thin diffluent pus. There was now found amphoric breathing of metallic quality on the right side below the spine of the scapula. In four or five days the pleura refilled and the amphoric breathing was lost. Three days later the patient was attacked with severe hiccough and acute pain and tenderness over the abdomen, and tympanites. Pulse small and thready, temperature raised, and aspect that of general peritonitis. With the aid of fomentations and opiates, however, the symptoms abated and the patient appeared to be doing well, when on October 27th he was seized with what was at the time thought to be hæmoptysis and brought up a large quantity of blood, and died in a few minutes. The patient had complained of pain in the stomach, but there was no history of vomiting either before or during his two months' sojourn in the hospital. There was no history of syphilis.

Post-mortem.—The peritoneum was found dulled by early peritonitis, the liver considerably enlarged, and the duodenum adherent to it by some putty-like lymph, corresponding with which, on the inner surface of the duodenum, was found a small but deep ulceration. The stomach was distended with dark fluid blood, and at the lesser curvature, nearer the cardiac than the pyloric orifice, a pale, shallow, clean cut ulcer was found, of the size of a florin, having a rather uneven surface. There was no adhesion between the stomach and liver at this point. Near the centre of the ulcer a small aneurysm, the size of a pea, was found, presenting at its summit an opening,

through which the hæmorrhage had proceeded. The aneurysm communicated with a subjacent branch of the coronary artery of the stomach.

The heart weighed 12¾ oz. The arteries were generally healthy.

The left lung presented at its summit some old resoftening tubercle and a large sloughing cavity. There was some tuberculosis of the lower lobe. The right lung also presented a large cavity at the apex, which in the axillary region communicated with the pleura by a hole the size of a fourpenny piece. Correspondingly a circumscribed pleural abscess extended from the level of the fifth rib to the diaphgram in the posterior and axillary regions of the chest. The lung was adherent elsewhere and compressed by the empyema. For about one inch below the cavity grey tubercles were scattered, as in the lower portions of the opposite lung.

Remarks.—The interesting feature in this case is the aneurysmal dilatation of an artery exposed by the ulceration of the stomach. There was no general atheroma of the vessels. There was no appearance of sloughing about the ulcer, nor did it appear to be very active, having given rise to no marked symptoms. One must bear in mind, however, that the seat of the ulcer on the upper curvature of the stomach would lessen the severity of symptoms occasioned by it, which might be further masked by the gravity of other associated lesions. I should be disposed to look upon this aneurysm as, in its origin, comparable with those which may be found in pulmonary excavations in patients of all ages,[1] from infancy[2] upwards. Age does not seem to have anything to do with the causation of these aneurysms, nor have I found syphilis nor general arterial disease associated with them in any special way. They seem entirely dependent upon local conditions, involving exposure of the vessel and removal of support from its wall at one point, and, in the lungs at least, the most perfect aneurysms are, as a rule, found in cavities which are not the seat of active ulcerative or sloughing processes. I brought the specimen forward, more especially in connection with that just exhibited by Dr. Irvine, showing an aneurysm presenting in an abscess of the liver.

There is one other point of interest in this case which I do not like altogether to pass by, viz. the fact that that portion of lung which was compressed by fluid escaped becoming the seat of tuberculosis. The tuberculosis in this case was quite recent and was

[1] 'Path. Trans.,' vol. xxii, p. 41. [2] Vol. xxv, p. 39; xxviii, p. 35.

distributed over both lungs, except that portion of the right lung which was compressed. This is quite in accordance with what may not unfrequently be observed clinically, viz. that an effusion into the pleura will sometimes serve to cut short an active phthisical process. and in such cases one should be careful not too hastily to interfere with what may prove a conservative lesion.

November 20th, 1877.

---

10. *Softening of syphiloma of liver.*

By Samuel Wilks, M.D.

Emma W—, æt. 32, died in Guy's Hospital in November, 1877. She was a married woman, but had had no children nor miscarriages. She had never had any illness until about two years before her death, when she began to suffer from a pain at the epigastrium, extending through to the back, accompanied by sickness. She subsequently had slight jaundice and became much thinner; the pain also extended round the right side over the region of the liver. These gastro-hepatic symptoms continued for eighteen months when the abdomen began to swell; subsequently the yellowness of the skin increased as well as the general emaciation, until the time of her admission into the hospital. She was then seen to be extremely ill, being very much wasted and jaundiced, with œdema of the ankles and with purpuric patches on the legs. She complained of much pain and tenderness in the right hypochondriac region. The abdomen was tumid and tender, but fluctuated with fluid, so that the liver could not be felt. She remained in this state for a short time, when she was seized with acute pain in the abdomen, and all the symptoms of peritonitis appeared. She passed through this attack, which left her still lower and with the abdomen tumid, tender, and full of fluid. Various medicines were given and part of this fluid was absorbed, when the liver could be felt below the ribs, with a protuberance on the right lobe. This and her other symptoms suggested cancerous disease, but the case was always regarded as obscure. She sank in the most gradual manner and died, apparently from exhaustion.

The *post-mortem* examination showed a considerable amount of fluid and lymph in the abdomen, old thickening of the capsule of the liver, and adhesion of this organ to all the surrounding parts. It was very evident that the chronic peritonitis which killed her had its origin in the right lobe of the liver, where lay the focus of the disease. On cutting through this a cavity was opened, the size of a cricket-ball, filled with a bright yellow liquid containing brown flocculent masses. The cavity was formed or surrounded by a dense border of yellow, caseous, tough substance, which was projecting in masses into the cavity as well as into the hepatic tissue around. In an adjacent part of the liver there was a large mass of a similar substance composed of a conglomeration of a number of yellow nodules. These, as well as the substance around the cavity, consisted of well-marked syphilitic gummatous material. The microscope showed the adventitious matter to be composed of a matrix, consisting of delicate fibres containing small cells, as usually met with in gummata. All the other organs were healthy.

The case is brought before the Society to illustrate the fact that syphilitic gummata undergo a softening process more commonly than is supposed, an important consideration when looked at from a clinical point of view. The general description of the syphilitic process is that it is a formative one, clearly distinguishable from an ordinary inflammation by the absence of all secretions of a purulent or other fluid kind, and that it comes to a termination by a drying up of the material and the formation of a cicatrix, as is frequently met with in the liver. Although these are the general characters of the syphilitic formations they nevertheless liquefy, as in the present instance, and several other examples of the same kind have come under my notice. For example, a man suffering from many of the phenomena of syphilis had also an enlargement of the liver, with distinctly marked protuberances upon it. After being relieved he at a subsequent period again came to the hospital with a tumour in the hypochondriac region, which presented all the characters of a fluid cyst. This was tapped and there were evacuated several ounces of a curdy fluid, which did not contain a single particle of pus, but corresponded in appearance to the material of a liquefied gumma. In the same manner I have seen a syphilitic mass in the neck and anterior mediastinum soften into a liquid. In another instance brought to the Society some years ago a gummatous tumour of the liver had softened and caused an opening into

an hepatic duct. I have also met with gumma of the brain which had liquefied into a material resembling cream. It is also well known that nodes on the bones will liquefy in a similar manner, and subsequently be absorbed under the employment of suitable remedies. It is possible that some cases of rapid disorganization of the lung in syphilitic patients may have been due to disintegration of gummatous material.

It is important to know under what circumstances the liquefaction is likely to take place, whether it occurs as a result simply of caseation and decay or whether it be connected with the more active growth of the gumma. I have every reason to think—a fact which was not so clear to me at the time of the early study of the syphilitic process—that the gummata are actively growing substances, and therefore in the present instance (where no remedies had been used) the gumma was growing at the circumference whilst it was softening in the centre; a process corresponding to what is so frequently seenin cancerous and other tumours—of growth and decay going on simultaneously. The exhibition of the present specimen, however, was not to suggest the mode, but simply the fact of liquefaction, and to enable me to append to it the remark that this process is probably more common than is generally supposed.

December 4th, 1877.

---

11. *Case of congenital malformation of the ductus communis choledochus.*

By John H. Morgan.

The child, of whose illness the following is a summary, was born of healthy parents of ample means. They have one child living, a perfectly healthy boy about four years old. A second child was born about two years after the first. This was also a boy, which was born apparently healthy, but died shortly after birth of cerebral convulsions. It had at the time of its death several small hæmorrhages under the skin resembling bruises. The body was not examined, but it was supposed to have died from some defect in the heart's structure.

The third child was a boy, and was born about a year after the second, and appeared plump and well formed, and for the first ten days perfectly healthy. The meconium was said by the nurse to have passed, and to have been of the usual colour and consistence. The umbilical cord came away as usual and without any hæmorrhage.

Ten days after birth, however, the mother became rather bilious, and found that the child was not thriving. It became rather yellow and was provided with a wet nurse. The general health improved, but the jaundiced condition of every part of the body, of the conjunctivæ, and the urine, increased steadily, though varying slightly from day to day.

I was asked to see the child when it was six weeks old. It was then intensely jaundiced though plump and firm, and did not appear in any way feeble or emaciated. The skin, though yellow in colour, was perfectly healthy. The appetite was good and the tongue was only slightly coated. The motions were white and clayey. No enlargement of the liver could be detected. The urine contained quantities of bile, as could be seen by the staining of the napkins. The child slept constantly, but there were no head symptoms. It yawned incessantly. There was no fever. It was treated with small doses of grey powder, and the wet-nurse's health and diet were carefully regulated. Still no improvement took place, the body and the urine continued to be intensely yellow, and the character of the motions did not improve.

A week after this, the general symptoms continuing much the same, a large subcutaneous hæmorrhage appeared suddenly on the outer side of the right knee, having somewhat the appearance of a venous nævoid growth. Two days after this another similar hæmorrhage showed itself below the skin of the right forearm, from which the skin was next day stained as from a bruise. Two small hæmorrhagic spots also appeared on the surface of the tongue; and the day following a large hæmorrhage took place under the skin covering the sacrum. During this time both child and wet-nurse were physicked without benefit, and the wet-nurse was changed.

On December 3rd I met Dr. West in consultation. We agreed that there was probably some congenital malformation about the liver or gall-ducts, but that on the chance of that not being the case it would be well to try some more active treatment than had hitherto been pursued. Accordingly it was given half a grain of calomel every night, and small doses of sulphate of magnesia in the day.

For the next three days the bowels were open three times daily, and some of the motions contained inspissated greenish-brown matter, which had the appearance of concentrated bile, but when tested and examined under the microscope I could find no evidence of bile or of cholesterine. I therefore stopped the medicines.

On December 8th, the child brought up a little milk, which was mixed with a slight tinge of what was undoubtedly blood, although the corpuscles were so much destroyed that none could be detected by the microscope. On December 11th Sir William Jenner and Dr. West met me in consultation. The child had then been constantly sick for twenty-four hours, and was very fretful. One or two more hæmorrhages had appeared, similar to those above described. The head was hot and the fontanelle was very tense. We agreed that having tried active measures there was nothing more to be done. At 11 o'clock that evening I was called to see the child and found it in a state of violent convulsions of a tetanic nature, screaming loudly, with back arched and hands tightly clenched, and intense general muscular contraction. The usual remedies were adopted, but without benefit, and the convulsions persisted for three hours, when the child died.

The *post-mortem examination* was conducted by myself twenty-four hours after death. I found the child well nourished. The skin showed several ecchymoses, which when cut into had all the appearance of an ordinary bruise. All the organs of the body, except the brain, were carefully examined, and there was found nothing abnormal in condition, structure, or appearance, beyond intense staining with biliary matter. The liver, however, was slightly enlarged, and the capillaries of its capsule were injected and full. The tissue of the organ was healthy but slightly congested. The gall-bladder was very small, not larger than a pea, and contained only mucus and no true bile. Its duct was patent but empty, as were also the ducts from the right and left lobes of the liver. Complete obliteration existed of the canal of the ductus communis choledochus. No opening could be found into the bowel, and the duct formed a fibrous cord which joined the intestine in the usual way at the usual spot. The tube was obliterated for a little more than half an inch. The intestines were empty and collapsed.

The vessels of the liver and those from the liver to the umbilicus were natural.

A very similar case to the above was related to the Society by Dr.

Wickham Legg, and will be found in vol. xxvii of the Reports. As, however, in the present case the symptoms were somewhat different, although the affection seems to have been identical, as well as on account of the extreme rarity of the condition, I was anxious to record it in the same series of reports.

The conditions here described is, I need hardly say, one of peculiar obscurity, and the principal points of interest which the case presents are:

1. That there is already a healthy male child of the same parents.

2. That there was no hæmorrhage from the umbilicus as usually occurs in this affection.

3. That though there can be little doubt that the affection was congenital, no symptoms presented themselves for ten days, and death did not occur till the child was 9½ weeks old.

It is a curious fact, that congenital malformations of the liver and its ducts occur much more frequently in boys than in girls. In the 'London Medical Gazette,' 1844, Mr. Ray relates several interesting cases of umbilical hæmorrhage which occurred in the male children of parents who had healthy female children; and his paper is written to show the greater frequency of this accident in boys than in girls, but he does not seem to have noticed anything connected with the state of the bile-ducts in his case, and as in all of them jaundice existed, he was probably mistaken in ascribing them, as he is inclined to do, to the hæmorrhagic diathesis, and they were almost certainly cases of malformation. In the same journal for 1850, Dr. Manley writes on the subject of umbilical hæmorrhage, and after relating a fatal case in his own practice, quotes two cases by M. Emile Dubois in the 'Archives Génerales de Médicine' for October, 1849, both in males, and both fatal, and afterwards quotes a paper by Dr. Bowditch in the 'American Journal of Medical Science,' January, 1850, who tells of one case in a female and another in a male, where there were two healthy male children living. He analyses twelve other cases—all fatal—in which jaundice was a common accompaniment, bleeding from other parts was observed, purpuric ecchymoses being present in two, and bloody dejections in six, but there is no mention of the *post-mortem* appearances.

It is exceedingly rare, indeed, that this condition of the liver is not followed by hæmorrhage from the umbilicus. In my case the

blood, obstructed in its passage through the liver, seems to have vented itself in venous ecchymoses beneath the skin. Three cases, however, in which there was no umbilical hæmorrhage, are to be found in 'Virchow's Archiv.' One by Binz, of Bonn, which occurred in a girl, who died on the second day, where the gall-bladder was found full of mucus, and the cystic and hepatic ducts and ductus communis choledochus were converted into irregular masses of connective tissue without any trace of a canal. A second occurred in a brother of the same child, which died in twenty-four hours, where the ducts were in a similar condition. A third case by Roth, was a child which died on the twenty-seventh day with symptoms indentical with those in my case, and in which the cystic duct was found impervious.

Dr. West, whom I have to thank for the above references, points out, in his work on the 'Diseases of Infancy and Childhood,' the hereditary nature of this affection, and mentions the case of a lady who lost in succession three out of five children, soon after their birth, with most intense jaundice, which in one instance was ascertained to be associated with malformation of the biliary ducts, and another lady who had lost four children with infantile jaundice from impervious biliary ducts, whose sister's only infant had also died in similar circumstances. Further information on this subject will be found in the statistics of Dr. Stephen Smith, in the 'New York Journal of Medicine,' July, 1855, who also shows the greater frequency of umbilical hæmorrhage in males than in females. Out of the seventy-nine cases collected by him twenty-six occurred where other children of the same parents had been similarly affected; while the tables of Dr. Grandidier, of Cassel, give a total of forty-one infants of eighteen mothers, in whom umbilical hæmorrhage occurred.

It has been suggested that these cases are the result of syphilitic infection, looking to the frequency of perihepatitis in syphilitic infants. In this case, however, I can guarantee that nothing of the sort was present, nor did the symptoms before death, or the *post-mortem* evidences, indicate any such taint. Dr. Legg, in the case above referred to, suggests that after the active changes which occur in the vessels of the liver at or soon after birth, an inflammatory process is set up, which extends to the capsule of the liver and the areolar tissue which surrounds the ducts of the liver, which is followed by contraction. In the present case I cannot say that I saw indications

of this. There was no thickening around the ducts, but simply closure of the passage. Looking to the fact that meconium was said to have passed, and that no symptoms occurred for ten days, I am more inclined to suppose that the passage may have been open before, or even at birth, but that some slight inflammation occurred in the canal itself consequent, perhaps, on the activity of the liver after birth, or upon some vitiated condition of the bile itself, which was followed by stricture of the duct.

The circumstance of life, under these conditions, being prolonged for nearly ten weeks, has great interest from a physiological point of view. Yet precedents will be found in the case already referred to, and also in one related by Dr. West, of a girl who lived for six months and a half, in whom after death the gall bladder was found to be absent, and replaced by two small sacs, while the hepatic ducts were impervious and greatly dilated.

Feb. 5th, 1878.

---

12. *Ulcerative escape of biliary calculi from the gall bladder into the duodenum.*

By Arthur E. Barker.

Mrs. B.—, æt. 50, widow, died Friday, Feb. 15th, 1878. She was first seen by Dr. Quain in July of last year, and complained of not feeling well, uneasy, and depressed. There was nothing further in her case discoverable, and as the patient was living very generously and indulging freely in the pleasures of the table, a certain amount of her sensations was attributed to the fact. She went to Emms about this time and took the waters, and somewhat later to Switzerland, where she tried the "grape cure" for a time. Later on she moved to Paris, and while there in the autumn she suffered with diarrhœa, for which she was ordered some simple remedy by Dr. de Musset, and with relief of this symptom. She then returned to London, travelling without any inconvenience.

Patient was again seen by Dr. Quain about 24th October last; was complaining then of extreme malaise, slight tenderness in the right hypochondrium, profuse sweating, requiring two or three

changes of linen during the night. The temperature never rose above 100°, and there were none of the usual signs of peritonitis. Apart from this there was very little which she complained of. From the beginning to the end of her malady she had not the slightest trace of jaundice and the closest questioning failed to elicit any history of the passage of biliary calculi at any time. Dr. Quain believes that he was able to detect some slight hardness in the right hypochrondrium, but as the patient's abdominal walls were extremely loaded with fat the difficulty of coming to any positive conclusion on this point was very great. Nowhere else in the abdomen could the most careful examination detect the slightest deviation from the normal.

From November to Christmas the patient remained about the same, when she began to pass very copious motions of a soft pap-like consistence and light yellow colour. The amount of these stools is described by Dr. Quain as enormous, one to four or five daily. The other symptom now began to disappear, and she was comparatively well except for sensation of malaise: her tongue became perfectly clean. She now became able again to respond to the claims of society upon one in the possession of great wealth, and went out freely to dinners, balls, concerts, and the theatre, so that about December 28th, when he regarded her as convalescent, she may be said to have been in pretty good health. This continued until just a fortnight before her death, when she went for the sake of a little change to Hastings. This was on February 2nd. On the 3rd she was quite well and sat out. On the 4th she had ordered a beef-steak and potatoes for lunch, but on sitting down complained of pain in left iliac region and felt no desire for food, and that evening vomited. She had five soft and abundant stools on the same day. Soon after, the vomiting became stercoraceous. No motion after this until death. On Thursday Dr. Quain was sent for, and went down on Saturday, when he found no distinct cause for the persistence of the symptoms. Fearing fæcal obstruction he had copious enemata administered, but though they came away they brought nothing with them, the constipation being complete. On Sunday evening, 10th, Mr. Erichsen went down to see her and remained until Tuesday morning, but discovered nothing pointing to anything of the nature of hernia or internal strangulation. Patient was seen again by Mr. Erichsen and Sir W. Jenner on Wednesday evening, but nothing new was made out. Sir W. Jenner suggested the diagnosis of

malignant disease of the colon, but no more definite case was made out. Patient died on Friday night late, stercoraceous vomiting having existed to the last.

Post-mortem Saturday night, February 16th, at 9 P.M. Body healthy-looking. Between 1 and 1½ inch of fat under skin of abdominal wall and a large layer also under the peritoneum: also much about the falciform ligament of the liver and in the omentum. Peritoneum healthy everywhere on opening the abdomen. No traces of acute peritonitis anywhere. Intestines much distended with flatus but otherwise quite healthy. Bladder distended with urine. No trace of hernia either inguinal, femoral obturator, or other. On handling the intestines which were to all appearances perfectly healthy, a large solid body was found in the upper part of the ileum in the front of the left iliac region. This moved freely upwards on the bowel being pressed between the fingers but not so readily downwards, though there was no distinct narrowing of the gut. It felt like a piece of wood to the touch, somewhat cylindrical below, dome-shaped above. On removal this proved to be a large biliary calculus (exhibited) exactly four inches in greatest transverse circumference, and 4½ in longitudinal circumference. It weighs over 5 drams. At the upper end its dome-shaped roof is truncated by attrition, but its base instead of being quite flat, is also shaped by attrition into a slightly mammillated projection at its centre. Internally it is formed of beautifully regular layers of crystalline cholestearin alternating with layers of darker colouring matter.

Throughout the small and large intestines, both above and below this foreign body, was a quantity of thin yellow fæces, and above the larger calculus at different parts were a number of smaller ones of more irregular shape (exhibited). From the duodenum downwards for a considerable distance the small intestine was marked on its mucous surface by patches of congestion almost of extravasation, such as one sees in the cases of those who have died after persistent stercoraceous vomiting; otherwise the bowel was normal throughout. The ileo-cæcal valve showed nothing unusual. Colon and rectum healthy.

On examining the liver the first point noticed was adhesion by firm fibrous tissue of the anterior margin of the right lobe to the transverse colon. On tearing through these adhesions a ragged sloughy cavity was opened, occupying the position of the gall bladder, traces only of which were apparent in its walls. The upper and anterior wall of this cavity was formed by the under surface of

the liver for an area of about 2½ inches every way. The upper and back surface of the colon aslo formed part of this wall and was very nearly, if not actually, perforated by the sloughing action. The posterior and lower wall of the cavity were formed of the remains of the gall bladder above, and the first and second part of the duodenum below. An opening from the cavity into the second part of the duodenum was found on the right side of the latter, at about the level but not corresponding to the orifice of the ductus communis choledochus. It was about the size of a sixpence. Tracing the ductus communis choledochus from above it was found intact and not implicated in the wall of the abscess. It was, as may be seen, much dilated for a long distance, but not obstructed. The cystic duct is also much dilated as may be seen, but is quite blocked where it merges into the gall bladder as far as the most careful examination can discover. This is not to be wondered at considering the inflammatory action which has taken place around the gall-bladder. In this cavity, or abscess, occupying the situation of the latter and in the adjoining duodenum were these fourteen or fifteen large biliary calculi (exhibited).

The point which perhaps of all others was most striking was the very small amount of inflammation around the under surface of the gall-bladder necessary to glue it well to the duodenum before perforation into the latter took place. All traces of inflammatory action were strictly limited to the immediate neighbourhood of the viscus, not the slightest evidence existing elsewhere in the abdomen.

The liver appears smaller than usual, but healthy. The spleen was small and soft. The kidneys were healthy, the bladder was thin and gorged with urine. *February 11th*, 1878.

---

13. *Peritoneal cysts, with blood cyst of left ovary.*

By J. Knowsley Thornton, M.B., C.M.

I use the name peritoneal cysts for these specimens with some doubt, because of the extreme rarity of such growths. Being, however, fully convinced myself that these are really cysts growing

in the sub-endothelial layer of the peritoneum, I bring them forward as such.

I have hunted in vain through the literature of the pathology of the peritoneum for records of any similar cases, and I find no less an authority than Dr. Payne speaking as follows on this subject when exhibiting some curious air cysts from the peritoneum at this Society in 1871, p. 311, vol. xxii, of 'Transactions': "Cysts of the peritoneum are hardly known; nothing of the kind is mentioned in the standard text-books."

Dr. Bexby, in a paper in the first volume of the 'Transactions of the American Gynæcological Society,' says, "the literature of this subject is extremely meagre," and he then proceeds to give references to all the information he can find on the subject, which correspond exactly with the results of my own researches. All these refer to these peritoneal cysts as of inflammatory origin. Thus Rokitansky speaks of them as seeming to be inflammatory products which become lined with serous membrane and form cysts ('Pathological Anatomy,' p. 28, vol. ii, 1855).

Peaslee speaks of "encysted dropsy of the peritoneum," but states that it is preceded and produced by peritonitis.

Atlee speaks of "peritoneal inflammatory cysts."

Mr. Spencer Wells and Dr. Barnes have each recorded a single, somewhat similar case to those of Dr. Atlee.

Looking over these various records I find none which seem to me to correspond with my case, because in none were the cysts such completely separable and perfect bags as these are.

The patient, A. T—, æt. 32, had been married seven years, but left her husband owing to his cruelty to her when drunk. She had had a doubtful miscarriage, after a fall down stairs, when first married, and had then first noticed the increase of size. Had never had any children. She was sent to me by Dr. Grey, of Oxford, who said in his note, written October 29th, 1877, "She has an ovarian tumour from which seven or eight pints of fluid were removed early this year." I learnt from the patient, after she came under my care, that the fluid was amber coloured, and was removed by Mr. Simmonds, while she was under Dr. Grey's care in the Oxford Infirmary.

Her history was that she had suffered from "low fever," after this miscarriage, and four or five years ago from "inflammation of the bowels," but she knew she had the swelling before this last

illness, so that it was probably a result of the presence of the tumour. Menstruation had always been irregular, and after the tapping it became still more so. She had suffered much dysuria before the tapping; none since.

I found on examination a fluctuant, somewhat flat, swelling, chiefly occupying the left side of the abdomen, but extending slightly across the linea alba. It was tolerably tense and I could not detect the slightest movement of the abdominal parietes over it, and I therefore came to the conclusion it was adherent all over its anterior surface. Examination per vaginum showed the uterus pushed over to the right side of the pelvis, its cavity measuring three inches, and its body not having its natural mobility. Low down behind and to the left of the cervix I felt a hard, irregular mass, which seemed very closely connected with both the uterus and the lower part of tumour. By rectal examination I thought I could separate this from the uterus, but I did not feel sure. I entered the following diagnosis in my note book:—

"Ovarian tumour on left side with very close connexions with the uterus and broad ligament. The case puzzles me, and I should not be astonished to find some other uncommon form of tumour."

On January 2nd, 1878, assisted by Dr. Godson and my colleagues. Dr. Champneys and Mr. Meredith, I made the incision usual in ovariotomy. I came upon what I believed to be a cyst with universal adhesion over its anterior surface, and, as is common in such cases, could not say whether I had cut through the peritoneum or not. Having at last exposed a cyst, covered with shreds of cellular tissue, I tried to pass my hand round it, but found this impossible, I now tapped it and let out a lot of clear, watery fluid, and was then able to shell it out from its capsule entire without any arterial hæmorrhage; the cavity left passed to the bottom of the pelvis, but on introducing my hand I could feel no intestine, and the uterus only through a thick membrane.

I now found that there was another large cyst in the abdomen, its inner edge reaching to my incision; this I tapped, letting out some dark yellow serum, and then it shelled out of a capsule just as the other had done, leaving a firm cellular membrane between the two cavities, and showing the intestines through the remaining capsule, just as I felt the uterus through the other. I now felt for the hard nodular body at the bottom of the pelvis, and after scratching

through a considerable thickness of cellular tissue came upon the left ovary turned into a blood cyst, firmly bound down all round by ahesions, I had now entered the peritoneum proper for the first time, but only worked in a space surrounded by adhesions, so that the cavity of the peritoneum was not entered at all. I removed the ovary after transfixing and tying its base, and then found that very free venous hæmorrhage was going on into the sacs, out of which the two cysts had come. Knowing how impossible it would be to get at and secure all the bleeding points, I decided to close the abdomen at once and trust to external pressure and the coagulation of the effused blood to stop the hæmorrhage.

The operation was performed with the strictest antiseptic precautions, and I felt confident that the blood would do no more harm than that in an ordinary extra peritoneal hæmatocele, provided only she did not bleed to death. I much feared that she would do so and stayed with her till 3 a.m., when there was a change for the better in her condition. She was of course very weak, but improved daily, and showed no symptoms of what she had gone through except the weakness. The wound healed by first intention, and I removed all the sutures at the first dressing on the fifth day of the operation. On the seventh day there was difficulty in passing flatus, and on the eighth I had the bowels cleared; temperature now began to rise and there were signs of tension in the pulse. On the evening of the fifteenth day the temperature had reached 103·6°, pulse 120. She suffered much pain in left iliac region, and flatus passed with great difficulty. Assisted by Mr. Meredith, I made a small incision under the spray, to the right of the healed incision, and let out nearly a quart of pure, perfectly sweet, dark venous blood, which coagulated in the basin into which it was received. I introduced a long india rubber drainage tube, and in seven hours the temperature was normal.

I had quite expected to find suppuration, though I was quite confident I should not find putrid suppuration. I found neither, and the increase of temperature and pulse must be ascribed entirely, I think, to nerve tension in the sac containing the blood, a tension slowly but steadily increasing, for, as I found afterwards, by the discharge through the tube, the hæmorrhage had not entirely ceased. I would not have detained the society with these clinical details, but I think them also of vast pathological importance. First, here is nearly a quart of venous blood confined in torn and injured cellular

tissue, with a ligatured ovarian pedicle at the bottom of the sac, the rectum, &c., in close proximity to it, and this, with constantly increasing and at last, high temperature, and yet it does not putrefy, though all its surroundings have been exposed to rough handling, sponges, instruments, atmosphere, &c., but protected by thorough antiseptic precautions.

Secondly, there is the fever due to tension of the sac, and not to any change in its contents immediately disappearing when this tension is relieved.

I had hoped to be able to say the patient is quite well,[1] but can only say she is convalescent. I unfortunately allowed the dressings to remain on too long on the twenty-eighth day after the operation, and putrefaction occurred; and I had to reintroduce my tube, which had been gradually shortened to an inch, to the bottom of the pouch of Douglas, and I have had more discharge, fever, and trouble in every way since than I had in the whole early treatment of the case.

To return to the cysts themselves, I believe them to have arisen in the sub-endothelial cellular tissue, and pushed the peritoneum and its contents aside. As I have already said, I probably passed through two adherent layers in removing the ovary, and possibly I may have done the same in making my abdominal incision, but it is quite certain the general peritoneal cavity was never opened at all.

Looking to the literature of the subject, such as it is, it seems not improbable that the disease in this instance started with the attack of low fever, which was probably due to retention of some fœtal structures after the miscarriage, and in support of this I would record the observation that the first beginning of an ovarian tumour has often appeared to me to follow so closely on an attack of enteric fever, that I could not but regard the former as the result of the latter. Inflammatory action being thus first started in the ovary, or spreading to it from the neighbouring peritoneum.

I have brought with me to-night a preparation of a group of small cysts in the sub-endothelial tissue of the broad ligament, which I came upon accidentally when staining some portions of broad ligament with nitrate of silver for another purpose. This group was far removed from the organ of Rosenmüller and the ovary.

[1] Sept., 1878. The patient is now quite well.

I have lately seen a remarkable case in the practice of Mr. Wells, where the whole cellular tissue of broad ligament, pelvis, peritoneum, &c., seemed to have undergone cystic degeneration, the cysts all containing solid papillomatous growths. And I have twice operated upon patients with cystic abdominal tumours quite distinct from the ovary. The first, a multilocular tumour situated in the omentum; the second, a large cysto-sarcoma weighing 25 lbs. was situated in the mesentery. The first of these patients died of septicæmia seven days after the operation. The other made an excellent recovery and remains after a period of ten months in perfect health.

These are instances of cystic formations in the peritoneal sub-endothelial tissue, and are, it seems to me, similar to those I show you to-night. Whether such new formations are always due to inflammatory changes a larger record of cases can alone decide.

February 19*th*, 1878.

V. DISEASES, ETC., OF THE GENITO-URINARY ORGANS.

1. *Case of so-called phosphatic diabetes.*

By Charles Henry Ralfe, M.D.

J. G—, æt. 20, was admitted into the Seamen's Hospital on the 13th of November, 1877, suffering from extreme debility and prostration, and complaining of pain in all his limbs, and especially across the loins. His face was somewhat flushed and the eyes bright, but the temperature was normal; the pulse weak and feeble. Chest sounds natural, with the exception of some coarse râles in the larger bronchial tubes. Urine clear, acid, no albumen, no sugar.

He says the present illness commenced three weeks previous to admission, but he had otherwise always enjoyed good health. During this attack he had lost eighteen pounds in weight. He has a spinal curvature, the seventh and eighth dorsal vertebræ being the bones affected, and he had also a strumous appearance generally.

November 29th.—Seven days after admission the mucous râles in the chest had cleared up, and he was not so prostrate. The pulse was stronger, and the temperature had remained normal during the time the boy had been in the hospital. Still the patient, in the absence of any definite symptoms, was extremely feeble and weak. Although no sugar had been found in the urine it was thought advisable to collect the urine for twenty-four hours, and then test for that substance in the whole quantity.

20th.—The urine collected during the last twenty-four hours measured 4600 c.c., and had a specific gravity of 1·010, but gave no reaction with Fehling's solution.

21st.—The quantity of urine collected in twenty-four hours measured 1400 c.c., a normal quantity, but the specific gravity had

risen to 1·029, so that the relationship between the solids excreted on each day was tolerably constant, and exceeded by a third the normal excretion. The urine was collected, measured, and the specific gravity taken subsequently, each day during the patient's stay in hospital, but it will be sufficient here to state that the average daily quantity passed by the patient each day for a month was 3263 c.c., with a specific gravity of 1·017. Taking the healthy excretion of an adult to be at the outside 1500 c.c., with a specific gravity of 1·020, the patient was, therefore, passing more than twice the normal quantity of urine, and excreting one third more than the ordinary quantity of urinary solids.

The urea and phosphoric acid were determined quantitatively on several occasions by the house physician, Dr. Murphy, with the following result:—

	Quantity of urine. c.c.	Sp. grav.	Urea. grms.	Phosp. acid. grms.
Dec. 3rd	4476	1·011	67	5·3
„ 4th	4800	1·016	116	9·1
„ 5th	4100	1·018	103	9·0
„ 7th	3050	1·017	61	4·28

On the 13th of December I made a quantitative estimation of the urea and the earthy and alkaline phosphates, with standard solutions distinct from those used by Dr. Murphy, and my results closely corresponded with his, viz.—Quantity, 2700 c.c., total urinary solids 108 grms., urea 89 grms. Phosphoric acid in combination with lime and magnesia 1·8 grm. Phosphoric acid in combination with the alkaline oxides 3·7 grms. Total phosphoric acid 5·5 grms.

Diet: 4 oz. wine, milk Oij, strong beef tea Oj, bread 12 oz. Improved in weight whilst in hospital, but urinary secretion did not diminish.

The patient remained in the hospital till the 20th December, when he was removed by his friends. His condition was materially improved, and he had regained 15 lbs. of his lost weight, but the urinary secretion was no ways diminished. During his stay in hospital the patient suffered greatly from boils. The patient had no dimness of sight, nor any appearance of cataract. At no time could even minute traces of sugar be discovered in the urine.

This case seems to correspond with a class of cases originally described by Prout, and subsequently by Roberts, of diuresis accompanied with increased elimination of urea, and with all the symptoms of diabetes, excepting that no sugar can be found in the urine.

Neither of these observers, however, as far as I can gather, made any observations with regard to the excretion of the other constituents of the urine. To Dr. Dickinson belongs the credit of being the first to point out that in certain cases of polyuria there was a considerable increase of the earthy phosphates in the urine, and to suggest what their pathological significance might be. Finally, Dr. Tessier, of Lyons, published last year a pamphlet entitled 'Diabéte phosphatique,' in which he attaches considerable importance to this increased elimination of phosphoric acid, and endeavours to prove that it is a distinct affection from the azoturia of Prout and Roberts, as he states that, though urea was found in excess in some of his cases, still it was not constantly so in all; and in some the quantity was actually less than normal. Dr. Tessier divides his case into four (in reality three) groups:

1st. Those in which nervous symptoms are predominant.

2nd. Those which precede or accompany pulmonary affections.

3rd. Those which are followed by, or alternate with, saccharine diabetes.

The question which is of importance pathologically is what is the difference between Dr. Tessier's diabéte phosphatique and Dr. Prout's azoturia? Dr. Tessier tells us that it lies in the constancy with which the phosphoric acid remains in excess in the urine, whilst excess of urea is not always noted. Dr. Tessier himself admits that his observations on urea were by no means numerous, and it is just possible that the cases where no excess was observed many have been due to exceptional causes. It is hard to understand how, if the excess of phosphoric acid is caused by disintegrating processes going on in the nervous centres, as suggested by Dr. Dickinson and, I believe, maintained by Dr. Tessier, why the urea should not likewise be increased. Nervous matter is rich in phosphoric acid, it is true, but it likewise is rich in albuminous substances, and the result of its disintegration would naturally lead to an increase of both phosphoric acid and urea in the urine.

Till the point is definitely settled, the term polyuria had better be used in describing that class of cases which stands intermediately between glycosuria on the one hand and hydruria on the other.

Appended are brief notes of another case of the same nature, which was under treatment at the Seamen's Hospital.

J. H—, æt. 16; July, 1876; Seamen's Hospital; admitted in a stupid, semi-comatose condition, extremely feeble, emaciated, no great

hunger or thirst; passed large quantities of water of medium specific gravity, with trace of albumen. No sugar.

Analysis, July, 1875—

Quantity			2900 c.c.
Sp. gr.			1·010
Earth Alkalies	(phosphoric acid)	2·3	5·2 grms.
		2·9	
Urea			51· grammes.

January 15*th*, 1878.

---

2. *Conclusion of a case of cystine calculi.*

By Christopher Heath.

Two years ago ('Path. Trans.,' vol. xxvii) I brought before the Pathological Society a number of cystine calculi, removed by lithotomy from a man aged 28, and I now show some irregular fragments of the same character, removed *post mortem* from his bladder and ureters.

The operation was in June, 1875, and the man had no further trouble until the summer of 1877, when he began to suffer from pain in the back and the bladder. I introduced a lithotrite on two occasions and crushed small fragments of cystine, but he refused to enter the hospital until the end of July, when he came in in a dying state. At the *post-mortem* examination on August 2nd, the *heart*, *lungs*, and *spleen* were healthy. The *liver* was amyloid and somewhat enlarged. The *bladder* was in a state of acute cystitis, and contained a rough fragment of stone. The *ureters* were dilated with a cystine stone in each, of the size of a cherry; the calyces were greatly dilated and remains of old nephritis were found in the *right* kidney, and acute pyclitis in the left kidney, the organ being distended with pus.

The calculi were irregular masses of a fawn-color and much less dense than those removed by operation.

In the former report it was noted that crystals of cystine were not detected in the urine after the third day from the operation. More careful examination of the urine, however, on several subsequent occasions, showed the presence of cystine invariably.

October 16*th*, 1877.

3. *Indigo calculus from the kidney.*

By WILLIAM M. ORD, M.D. LOND.

THE specimen exhibited was removed *post mortem* from the pelvis of the right kidney of a woman of middle age by Dr. Bloxam, who sent it to me, with other parts, for examination. The clinical facts of the case are as follows:—The left kidney was destroyed by a soft, round-celled sarcoma, which had ended by obstructing the ureter and reducing the kidney to a lobulated cyst, containing a long, branched, earthy calculus. The right kidney was hypertrophied and somewhat hyperæmic, but its structure was healthy.

The calculus is a flat hard cake, of the shape and size of a fruit lozenge, and weighs forty grains. It is partly of a dark-brown colour, but on three fourths of its surface a blue-black colour, granular and without polish, is spread. Drawn across a sheet of white paper it leaves a rough blue-black mark. Its section is grey, and polished.

In examining the calculus, I first heated a portion on platinum foil. It was in great part consumed, giving off a vapour of an offensive and pungent quality, reminding one partly of burnt feathers partly of soot, but having also a character of its own. I did not know at the time what this character was, but in later experiment, found that indigo during sublimation yielded exactly the same odour. There was left on the foil a white, infusible ash, composed of phosphate of lime.

The next step in the process was to examine some of the calculus under the microscope. A small portion was scraped and powdered, and placed in water for examination. It showed a matrix of a dark reddish-brown colour, containing fibrous crystalline matter and masses of pigment. The pigment looked mostly black, but at the edge of masses, or in small detached granules, a deep blue colour was observed. At first I supposed, the idea of blood-pigment being present to my mind, that this was some pigment accidentally introduced. But on repeating the preparation and observation several times, with great care to avoid intrusion of extraneous matter, I still found the colour.

3. A portion of the calculus was powdered, mixed with an equal portion of dry chloride of sodium, and enough glacial acid to cover it.

Heat was applied till ebullition occurred, and the mixture was then allowed to cool. The liquid during boiling assumed a beautiful pure blue colour, and on cooling deposited crystalline material of a coppery lustre. A few hæmin crystals were found among the brown portion of the calculus on examination under the microscope.

4. A portion of the calculus was digested in a mixture of one part of hydrochloric acid with two of water. This was partly for the purpose of analysis of the earthy constituents. But it was my practice to do this also for the purpose of making examination of the organic matrix of the calculus. The matrix, as I have elsewhere endeavoured to prove, has, in my opinion, a very important part in determining the form and cohesion of the earthy or crystalline constituent of calculi, and much can be learned by its systematic investigation. The residue, insoluble in HCl, was in bulk almost equal to the material before treatment, but was friable, and easily reduced to powder between two plates of glass. Under the microscope it was partly brown, partly of intense blue colour, partly purple, but the blue was in great excess of the other constituents. It was seen to be partly crystalline in form, but the exact type of the crystals was not apparent.

5. The blue colour seen in the foregoing observations being more like that of indigo than anything else, and indigo being already known as a urinary product, a direct test for indigo was applied—the test of sublimation. A small quantity, about one grain, was powdered and placed in a perfectly dry test-tube. On the cautious application of the flame of a spirit lamp to the tube, a purple vapour, closely resembling that of iodine, was disengaged and filled the lower part of the tube, while the odour of burning indigo was strongly evident. On removal of the heat the vapour instantly condensed, both in the pigments and on the side of the tube. Examination with the microscope showed the deposit to consist of flat prisms, some blue some black, with much finely granular blue matter.

Subsequently a permanent microscopical preparation was obtained in the following way:—A tiny heap of powdered calculus was placed on platinum foil, and a glass ring—one of the rings sold for making microscopic cells—was fixed so as to enclose it. On this was placed a clean glass microscope slide. The vapour emitted on heating the foil was collected on the glass slide, a drop of glycerine added, and on the superposition of a covering glass a pre-

paration was obtained, which on comparison with a preparation made in the same way with commercial indigo presented exactly similar appearances. In both cases there were abundant blue prisms mixed with blue granules. The prisms were oblong with pointed ends, in many cases, however, with the ends truncate or excavated. The tint of colour was exactly the same in both specimens. (The two plates were exhibited together at the Pathological Society.)

6. A small portion was very finely powdered, and triturated in a mortar with sulphuric acid. At first only a dingy brown colour was produced, but after standing for some days the mixture was found to be of an opaque blue colour. It was taken to Dr. Thudichum, who diluted it with water, filtered it, and obtained a clear blue solution, which, in the spectroscope, gave a marked band in the yellow without stopping the blue or the red rays. This corresponds with indigo, and with no other blue or purple fluid that I know of. Sulphate of copper solution, which has a tint very like that of the sulphate of indigo, gives a band in the extreme red, but none in the yellow. Indigo from urine, in chloroform solution, gives the band in the yellow.

7. The reduction test for indigo was not made by me, the foregoing evidence being conclusive. The conclusion is that the calculus consisted of some blood-clot, containing crystalline phosphate of lime and a large quantity of indigo, principally as a thick encrustation.

It remains for me to make some observations upon the relations of the calculus.

The occurrence of a blue matter like indigo in urine has been occasionally noted. The occurrence of a substance, itself colourless, but, under the influence of acids and oxygen, capable of yielding indigo-blue, as a frequent constituent of urine is now well recognised. But as far as I know the presence of indigo in a urinary calculus has never been before observed, much less has a calculus largely composed of that substance been described.

The observation standing so much alone cannot be regarded as of the greatest importance in reference to the subject of calculi, but it will, at least in my own case, serve to turn attention more strongly to the extent to which indigogenous matter exists in urine, and to the conditions thereof.

As regards the origin of the indigo in the present case, it is clear

that there are at least three possible sources—food, medicine, and pathological conditions.

1. Although many plants besides wood contain a colourless juice, developing under certain processes of fermentation indigo pigments, there is no reason to believe that, generally speaking, indigo appears in the urine as a consequence of their ingestion.

2. On the other hand, Jaffé has shown that indigo can be obtained from the urine of animals fed on a diet from which vegetable matter is excluded.

3. The diet in the present case consisted of soups, broths, and farinaceous foods, none of them likely to include indigo or indigogen.

3B. Medicines: the patient took creosote for some time before death for the relief of vomiting. It must be borne in mind that the ingestion of creosote and carbolic acid is sometimes followed by a dark discoloration of the urine, and that this has been shown by Dr. Odling to be due to indigo.

4. The source of indigo in urine cannot be said to be well established. Schunck, finding in indigoferous plants a soluble matter, called by him indican, and decomposed by acids into indigo-blue and indigo-sugar, argues that the same substance furnishes indigo in urine. This theory, which is much disputed by other eminent chemists, in particular by Dr. Thudichum in this country, does not account for the origin of the indican.

Jaffé has of late done much to show a definite and more or less constantly present source of indigogen within the system. He suggests that the indigo of urine is derived from indol. This substance, having the formula C_8H_7N, can be obtained from indigo-blue (C_8H_5NO) by a process of deoxidation with hydrogen. It is crystalline, volatile, and soluble in water as well as in alcohol and ether. The same substance is formed when albumen is decomposed by strong alkali, and when peptones are broken up by pancreatic juice, and it is present in the fæces, which are believed to owe much of their peculiar odour to it.

Jaffé finds indican in the urine of dogs after the subcutaneous injection of indol; also after the ligature of the small intestine, but not after ligature of the large. He finds excess of indican in the urine of persons suffering from fever associated with intestinal affection; no excess in other fevers. He suggests, therefore, that in conditions leading to retention of the products of pancreatic digestion, or to imperfect action of the intestinal juices upon those

products, indol gets absorbed from the intestine in larger quantity than normal, and is excreted by the kidneys as indican.

This argument is certainly supported, as far as it goes, by other observations. In the first place cholera urine has been found by Gubler (1854), and by Hassell, Thudichum, and others since, to yield indigo-blue on exposure, and oxidation. But the more recent observations of Senator on the occurrence of indican in urine place obstructions and other affections of the intestines among the most frequent associates of its increase.

5. Indican has been again referred to blood pigment by G. Harley and others.

On looking over the results of various foregoing observations, and some of my own in addition, I am inclined to believe that, wherever any unusual or rapid breaking down of albuminous matter is proceeding, indican is likely to be found in the urine as a result and evidence. So that, while imperfect gastric or intestinal chemistry may be a cause of one kind, fevers, suppuration, and blood-poisonings may be causes of another kind. Pus, it may be remembered, has a green or bluish-green tint of its own, and has been made by chemists to yield a blue pigment like indigo. The indigo-blue now exhibited on filter-papers was obtained from the urine of a boy having bone disease with free suppuration. And in the present case there are some points which are touched by this relation. The left kidney was a seat of suppuration and disintegration, and an obstacle to the outflow of the pus and débris existed. It has been suggested to me by Dr. Thudichum that such retention might lead to absorption of indican among other results of disintegration; that the indican would be here formed from indol in presence of alkali, and being carried off by alkaline blood, would at the time of its excretion by the healthy kidney be deposited as indigo-blue on coming in contact with acid urine. This is, however, nothing more than a suggestion, on which I should not like to argue seriously at present, but which I should just keep in sight for verification or correction during the continued observation to which this discovery will lead me.

March 5th, 1878.

4. *Calculus containing carbonate and phosphate of lime.*

By W. M. Ord, M.D. Lond.

The lower calculus, in the preparation shown, was removed from the left kidney of the body, in the right kidney of which the indigo calculus, exhibited by me at this Society a few meetings ago, was found. This left kidney had been destroyed, so far as its secreting tissue was concerned, by a sarcoma, the destruction having been a result of the occlusion of the ureter. The kidney was reduced to a lobulated sac containing a purulent fluid and the calculus now shown. The calculus is long and partly branched, agreeing in form with the calculi of larger size often found in the pelvis of the kidney. Such calculi are generally formed, as their sections readily demonstrate, by the cohesion of smaller concretions beginning in the infundibula, which after attaining a certain size come into contact with the calculus in the pelvic cavity, and so make a mass. reminding one of some of the branching corals.

The calculus is firm on its surface where it has a laminated structure, friable in the interior and without lamination. The interior consists of spheroidal particles of phosphate of lime with a little carbonate, mixed with urate of lime and soda in beautiful needles and prisms. Such forms as these latter are not at all common in calculi, and are only found in very friable portions. This deposit is indeed so friable that there can be little doubt as to its having been formed after a partial occlusion of the ureter had produced dilatation in the pelvis, so as to allow sediments to accumulate in some diverticular sac out of the trak of the current of urine. The small quantity of carbonate of lime found confirms this idea. The particular crystalline forms of which the deposit is composed are such as would only be produced in limpid urine. If there had been mucus or other colloid present there would have been spheroidal masses, and cementation. The crust of this calculus contains alternate strata of urates, and of phosphates with carbonates, the latter predominating at the outer surface. These superficial layers are very compact, and the carbonate is here so intimately mixed with organic matter that it does not effervesce with slightly diluted acetic acid, but requires the action of hydrocloric acid for

its solution. The carbonate is here in much larger proportion than the phosphate. Many circumstances point to the conclusion that where carbonates are formed and enter into the composition of calculi from the urinary organs, such calculi have been formed out of the course of the urine, in diverticular passages, where other fluids than urine would predominate or be present without urine. The increased quantity of carbonate, in the outer layers would probably, therefore, indicate that the ureter had been completely blocked when they were formed. The calculus does not yield any trace of indigo or indigogenous material. *May 7th*, 1878.

---

5. *Spontaneous disruption of calculi within the bladder.*

By W. M. Ord, M.D. Lond.

I now exhibit two sets of specimens illustrating spontaneous fracture of vesical calculi, of what one may call auto-lithotrity. The first set was sent me by Dr. Lockhart, of Blackheath. It consisted of twelve fragments. They had been passed by a gentleman of the age of fifty-six. The passage was attended with severe pain, but there was no vesical pain preceding or following. The patient had not any symptoms at the time leading to the suspicion of the existence of calculi, and had not been subjected to operation or, as far as is known, to any shock. The urine at the time was "copious, limpid, free from deposit, from albumen, and from sugar." Some time after the passage of the calculi, symptoms of stone in the bladder appeared, but the patient was carried off by bronchitis before a contemplated exploration was carried out.

Dr. Lockhart has kindly allowed me to exhibit the calculi. They are segmental fragments which, if put together, would form several pisiform calculi, having a small central hollow. Each fragment is of a pyramidal shape, with the base rounded and projecting, the apex truncate, and slightly hollowed. The substance of all is nearly pure uric acid, with a very small quantity of ammonia in combination. This is arranged in layers, parallel to the rounded surface and to each other, and forming parts of circles which would have had their centre a little beyond the truncate apex. The struc-

ture under the microscope is fibrous-crystalline. Six of the fragments have sharp edges, and are coated thinly with a white powder, consisting of neutral urate of ammonia in molecular form. The other six are rounded at their angles as by mutual attrition, and have smooth, fawn-coloured surfaces, excepting in their hollows, which are coated with the white urate. No fragment corresponding to a nucleus which might have occupied the central cavity was found. From the whole of these conditions I infer that the calculi underwent spontaneous disintegration in the bladder; that the central portion, which is wanting in all the specimens, was of a different constitution from the other parts which are left; that it probably contained much mucus or other colloid capable of becoming swollen in alkaline fluid; and that the calculi, having been formed in acid urine, underwent disruption when the urine, under some conditions, became alkaline. That the urine was neutral or alkaline at the time of disruption is shown by the deposit of neutral urate of ammonia found on the surface of the fragments.

The second set of specimens illustrating spontaneous disruption was given to me by Mr. Buckstone Browne. Mr. Browne sent me a box containing upwards of thirty fragments, which, in a letter accompanying them, he describes "as evidently the results of spontaneous fracture of several moderate-sized calculi, and curiously water-worn and polished." They had been passed at different times by a gentleman of the age of sixty-three, who had been supposed to be suffering from stone for some time, and who afterwards was found, on being sounded, to have several calculi in the bladder, but died of uræmia before he could be submitted to operation.

The fragments generally resemble the last exhibited, excepting that some are larger, and many are more worn. Some few, still sharp-edged, are, as it were, whitewashed with neutral urate. The substance of all is almost pure uric acid in concentric layers.

The nucleus is, again, wanting in all, and the resemblance between these specimens and the last is so complete that one may fairly assume both to have been produced in the same way.

Both sets agree again with specimens exhibited by me to the Society last year, regarding which the same hypothesis of the disruption of pisiform calculi by expansion of the nucleus, as of a shell by a bursting charge, was advanced. *May 7th*, 1878.

6. *Large single cyst of the testicle.*

By Alban Doran.

This specimen shows the presence, in the right testicle, of a large cyst, very different in character from the small multiple cystic formations more frequently met with in that gland.

The testicle was removed during the past summer by Mr. Jonathan Hutchinson, from a gentleman aged thirty-six, of a somewhat strumous appearance. The patient denied that he had ever contracted syphilis, but had an indistinct recollection of having received a blow on the right testicle about a year before the operation. During that space of time the gland had remained permanently enlarged, and fluid had collected in the tunica vaginalis, which was emptied several times by tapping.

The operation was commenced by an exploratory incision, some clear hydrocele fluid escaped, and the tunica albuginea appeared smooth and even. On cutting into the testis the true glandular portion was found expanded in a thin layer over a large single cavity, which was filled with a chocolate-coloured fluid, large brown flakes, and masses of a soft substance. The testicle was then remo ed.

The cyst-wall can be readily detached from the glandular structure in front and laterally, but posteriorly it adheres firmly to the mediastinum, from which it appears to spring. When fresh, the brown flakes had all the appearances of blood-clot; this was corroborated by microscopical observation. The softened masses, when placed in water or spirit, show numerous filaments floating from their surfaces. When the specimen was first examined, these masses were all more or less adherent to the walls of the cyst.

On section the filamentous periphery of each mass was found to consist entirely of tubules resembling normal tubuli seminiferi in their general characters. They differed from those natural structures in several respects. In calibre they were by no means uniform, some being as narrow as $\frac{1}{500}$th of an inch in diameter, others were very large, nearly $\frac{1}{125}$th of an inch in their transverse measurement. The contents of the smaller tubules was purely granular, but the larger were not only lined, but stuffed with large

cells, possessing very well-defined borders and granular contents, without distinct nuclei. The deeper part of each mass consisted of a collection of large round cells. Most of these were bigger than the cellular bodies in the larger tubules, few were granular, and nearly all were distinctly nucleated.

Hence this cavity and its contents must not be spoken of as a blood-cyst, as that term would not thoroughly explain its character. Pathologically it must be defined as an adeno-sarcoma of the testicle that has undergone cystic degeneration. Probably the slight blow which the patient believes he received (though it was so trifling an accident as to have been almost effaced from his memory) caused hæmorrhage into a pre-existing new growth, thereby giving it a cystic character. The solid portions of the growth had none of the characters of chronic, inflammatory, syphilitic, or tubercular deposits. The clinical history hardly indicates malignancy, for the gland remained nearly the same size for one year, nor was there any thickening of the cord or enlargement of neighbouring lymphatics. The uniform character of the large round cells in the interior of the masses determined the sarcomatous nature of the tumour. The presence of very distinct adenoid structure recalls the adeno-sarcomata so frequently observed in the mamma, but decidedly very rare in the testicle. In this lies the interest of the specimen, for the nature of similar growths, and the signification of so-called blood cysts, are questions that have already been fully discussed before our Society by Mr. Godlee and other pathologists. *November 6th*, 1877.

---

7. *Cases of prostatic tumours removed in the operation of lithotomy, followed by recovery.*

Communicated by THOMAS BRYANT.

CASE 1.—A healthy sea captain, æt. 67, came under my care at Guy's Hospital in January, 1875, for stone in the bladder, of which he had had symptoms for eighteen months; irritability of bladder, painful and difficult micturition, with hæmaturia, being the chief symptoms.

On examination a stone was felt as well as heard, and the prostate gland was found to be enlarged.

On January 14th lithotomy was performed after Key's method, the blunt gorget being used as a guide into the bladder, on account of its depth from the enlarged prostate. The stone, which was large, was caught without difficulty; but in extracting it more resistance was felt than would be accounted for by its size. The introduction of the finger of the left hand for exploratory purposes made out that either a portion of the prostate gland or a prostatic tumour was held by the forceps between the calculus and the hinge. This was removed with the stone, very little force being employed. The stone when removed measured an inch and a half in diameter, and was a true mulberry calculus, with a crust of lithic acid.

What was taken away in the hinge of the forceps was clearly prostatic tissue, or an adenoid tumour connected with the prostate gland, for it consisted almost entirely of gland tissue with muscular fibre. After the operation it seemed as if the *third* lobe of the prostate gland had been crushed, for some pendulous shreds of tissue had to be cut off. No bleeding followed.

On the second day the temperature was 98·6°, and no bad symptoms existed.

On the sixth day some urine passed through the penis.

On the twenty-seventh day he could retain some urine. On March 6th, however, he returned home, well able to retain his urine and free from all pains. In May the patient reported that he was quite well, and that he had no bladder trouble of any kind.

In August, 1878, nearly three and a half years after the operation, he says he is still well in all respects, that he can hold his urine for hours, in fact, that he was never better in his life.

Case 2.—A clergyman, æt. 70, came under my care in February, 1876, with bladder symptoms of four years' standing. They first showed themselves in the form of irritability of bladder and painful micturition, the irritability and pain gradually increasing; for two years the urine had contained blood, the quantity of blood increasing after a sharp or long walk. For six months he had suffered from prolapse of the rectum. During the last six months he was passing water every half hour, and the pain which attended the act was very severe. The urine was also very thick and offensive. His general powers were feeble. On passing a sound a calculus was

struck, and it was thought to be large. The bladder could not contain more than an ounce of urine. The prostate was felt to be enlarged.

On February 18th lithotomy was performed, Aston Key's straight staff being employed, as is my custom. The prostate being enlarged the finger could not reach the bladder, and consequently the blunt gorget was used. The forceps were introduced into the bladder without difficulty, and the stone, which was large, seized; on extracting it much resistance was experienced and on introducing the finger of the left hand to ascertain the cause, and looking into the wound, a portion of the prostate gland was seen and felt to be held by the lithotomy forceps between the hinge and the stone.

With the recollection of the case last recorded, and Sir W. Fergusson's observations upon the complication before me, I rotated the forceps, holding the stone firmly, and at the same time with the left index finger pressed the prostate gland back, and in less time than I can write it the stone was withdrawn with the prostatic tumour I now show you in the hinges of the instrument. No bleeding worth mentioning followed the operation, and on examining the neck of the bladder it was clear that the prostatic tumour had been enucleated from the gland from the position of the third lobe, for the depression could be felt from which it had been withdrawn. After the operation everything went on satisfactorily.

On the twenty-second day urine ceased to flow through the perineal wound, and passed wholly through the urethra. On the thirtieth day the patient could retain his urine for two hours. By six weeks the perineal wound had entirely healed, and in another week he left London for home, passing healthy urine without pain, able to retain it during the day for three hours, and during the night for six; in fact, all his bladder symptoms had disappeared, and he was better in health than he had been for many years. At the present time he is quite well, and able to retain his urine for four hours.

The stone was composed chiefly of uric acid, with some phosphate and oxalate of lime; it measured 2½ by 2 inches.

Remarks.—The tumours I removed from the two cases just related I now hand round with the calculi. The first is only a portion of the whole, so many sections of it having been made for examination. The second fairly represents the original.

DESCRIPTION OF PLATE V.

Fig. 1 shows the microscopical appearances in Mr. Bryant's case of adenoid tumour removed during lithotomy (Case 2, page 164). From drawing by Dr. J. F. Goodhart.

a. Muscular trabeculæ. *b.* Cells forming the acini. *c.* Similar cells free. *d.* Bladder epithelium.

Fig. 2 represents the lower end of ileum from Mr. Davies Colley's case of congenital occlusion of small intestine. (Page 115.)

The upper part of the drawing shows the intestine above the septum, much dilated, laid open nearly as far as the occlusion. The upper and larger cul-de-sac is shown. The lower part of the drawing represents the atrophied portion of the ileum below the septum. As this is completely laid open, the lower and smaller cul-de-sac has disappeared.

a. Ileum above septum. *b.* Septum. *c.* Lower part of ileum completely laid open. *d.* Artificial opening made by operation. *e.* Mesentery.

Figs. 3—6 illustrate Mr. Butlin's specimens of Multiple Sarcoma (page 211) from drawings by himself. (× 240.)

FIG. 3. Tumour of back. Oc. 3, obj. 7. Tube drawn out.
FIGS. 4 and 5. Tumour of chest. Oc. 3, obj. 7. Tube drawn out.
FIG. 6. Tumour of forehead. Oc. 3, obj. 7. Tube drawn out.

Fig. 1

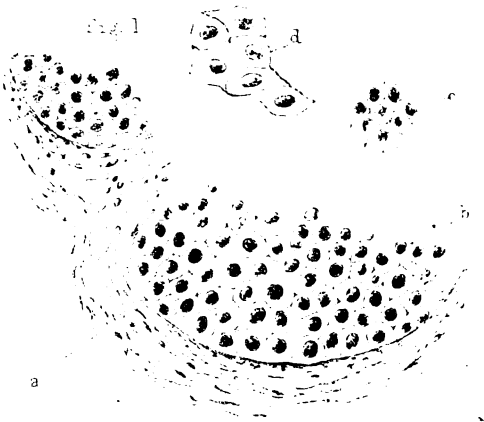

Fig. 2.

Fig. 5

Fig. 4

Fig. 6

Fig. 3.

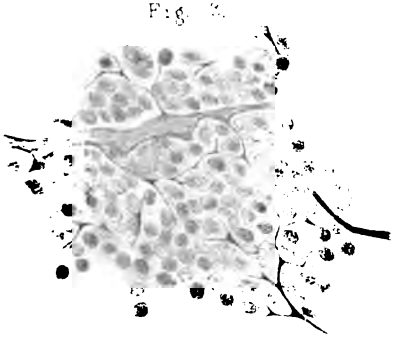

Dr. James Goodhart reports of the second specimen,—"The growth is made of well-marked prostatic tissue. Its nature and likeness to healthy prostate are shown in the sketch, which looks innocent enough. But it has a very milky juice on section, and under the microscope—though some parts have the proper proportion of muscular fibre and glandular acini—very little of the latter structure and very much of the former, yet the greater part reverses this proportion, and then becomes very cellular (Pl. V, fig. 1). Therefore it is clear the growth is in an active growing condition, and I would venture to call it a malignant adenoma."

Feb. 19*th*, 1878.

In a clinical point of view these two preparations are of great interest, for it can hardly be disputed that they represent prostatic tumours which have been removed by the operation of lithotomy, and that in both cases the patients have not only been relieved of a stone, but of an affection which is hardly less distressing; indeed, in the second case the patient was believed to have been suffering from prostatic disease alone. It is also interesting to know that nothing but good followed the operation, and that the injury to the prostate glands in both cases had no injurious influence upon the convalescence of the patients. Indeed, from the recent reports of one two years, and the other three years after the operation, there seems good reason to believe that the removal of the prostatic tumours has been most beneficial, for at the present period no bladder symptoms can be said to exist.

I would venture, therefore, to conclude from the success which has followed the removal of these prostatic tumours in the operation of lithotomy that the surgeon should in future parallel cases adopt the same practice; indeed, I would advise that in all operations of lithotomy in the aged that the condition of the prostate should be examined into, with the view of the removal of such portions as may be injuriously enlarged and project into the bladder. And though I am not prepared to recommend that the operation of cystotomy should be performed in all cases of chronic cystitis the result of an enlarged third lobe of the prostate gland, I would venture to suggest the expediency of its applicability to exceptional cases, believing that a clean cut into the bladder of a man with sound kidneys is not a very dangerous proceeding, and that the removal of a prostatic tumour projecting into the bladder by some crushing forceps or scissors would not add greatly to the danger.

I should like to add that the late Sir William Fergusson was the first to exhibit specimens of this kind before this Society in 1848, that is, thirty years ago, and as he has recorded "not long after heard whispers about rough and improper proceedings in lithotomy," although, he adds, "these came chiefly, or rather solely, from those who had rarely if ever performed the operation."—*Lancet*, January 1st, 1870.

I hope in these days the preparations I have to-night exhibited will have a better reception. *February 5th*, 1878.

(c) FEMALE.

8. *Solid tumour of left ovary and slightly enlarged right ovary.*

Exhibited by J. KNOWSLEY THORNTON, for HENRY TAYLOR, Guildford.

THESE specimens were removed by Mr. Taylor after death from the body of a woman, aged 60, who died of obstructed intestine, due to the pressure of the large tumour upon the small intestine and rectum. Mr. Taylor first saw her a year and a half ago, and then believed the tumour to be a uterine fibroid; he saw her again shortly before the fatal termination. She was suffering from obstruction of intestine and colicky pains; the tumour had now become partly abdominal, and he believed it to be malignant disease, either of the ovary or of the pelvic cellular tissue. The treatment consisted in relieving symptoms by subcutaneous injections of morphia and opium in pill; entire obstruction came on, however, and she died in forty-eight hours.

Mr. Taylor performed the *post-mortem*, and found the tumour was a solid enlargement of the left ovary, which filled up the cavity of the pelvis, and extended into the abdomen; it was flattened posteriorly against the sacrum, and to this flattened surface a large coil of small intestine was adherent and obstructed; above this the intestine was distended with fluid fœces. The colon was distended with gas, and this was found to be due to pressure of the tumour on the rectum at the brim of the pelvis.

Mr. Taylor describes the tumour when fresh as "a brain-like

mass, lobulated and hard as scirrhus cancer." The right ovary was little above its normal size, but of the same colour and consistence as the large tumour. "Under the microscope the latter was found to contain fusiform nucleated cells."

I have carefully examined sections from various parts of the tumour, and find it is chiefly composed of spindle or fusiform cells, with rather large oval or oblong nuclei; its microscopic characters varying somewhat in different parts, from extremely dense fibrous tissue to a beautiful myxomatous tissue. The spindle-cell element predominates sufficiently, however, to justify calling it a spindle-cell sarcoma.

The right ovary is chiefly composed of similar nucleated fibro-cellular tissue, and in this respect hardly differs from most ovaries I have examined after the menopause. Perhaps this specimen contains more growing nucleated tissue than one would expect to find in the ovary of a woman of sixty.

The chief interest of the specimen lies in the beautiful destration it affords of a peculiar form of tissue with which I have for some time been familiar, both in ovaries of women who have passed the menopause, and also in the stroma of diseased ovaries at earlier periods of life. The members of the Society will notice that on the cut surface of the ovary, which has not been destroyed by my sections, there is a rough granular appearance, due to something which seems to have been squeezed out as the fibrous tissue contracted from the action of the alcohol. This is the tissue to which I wish especially to direct the attention of the Society. I have said that I have long been familiar with its appearance, but I have never been able before distinctly to trace its origin. It has presented itself as a degeneration of some portions of the ovarian stroma, or a deposit in the meshes of this stroma. It is described and figured by Rindfleisch as a circumscribed colloid softening of the stromal connective tissue. He thinks that in this degenerate tissue cysts are formed, and that this is probably one of the common modes of formation of the cystic tumours of the ovary. I was inclined to accept this view, but had always thought that this material was a degeneration of the cicatricial tissue of the corpora lutea, having formed this opinion from its occurring in round and oval masses, and in the situation in which the corpora lutea also occur. The specimen I now show proves, I think conclusively, that this material is the result of a degeneration

of the blood-vessels, their coats, as a whole, seem to be converted into this colloid or myxomatous tissue, at the same time swelling up so that their lumen is obliterated. The process is fairly seen in the specimen I have placed under the microscope (the condition of the ovary rendered it difficult to get good thin sections, but still the condition of the vessel is fairly shown). The drawing which accompanies the paper shows the condition well. Looking over many specimens which I possess, with the light thrown upon them by this one, and comparing the arrangement of the vessels in a young ovary as seen in sections with the patches of this tissue in others, I think there can be no doubt as to its origin. Thus its formation would be rather a physiological than pathological process. But it is extremely likely that this change in the ovarian vessels may pass on to actual diseased conditions as suggested by Rindfleisch; just as in other organs in which organic changes of this kind are the natural outcome of functional changes, and actual pathological states are therefore common.

This portion of the subject has been so specially interesting that I am afraid I have hardly done justice to the tumour, which is really a very rare specimen, and pathologically and clinically of much interest. I have myself only seen three solid tumours of the ovary in more than five hundred ovariotomies at which I have been present.

Mr. Wells, writing in 1872, had only seen one, but two or three others have since occurred in his practice. Dr. Atlee, of the United States, writing quite lately, had only met with four cases in a very large number of pelvic tumours examined.

From the small experience thus to hand, solid ovarian tumours seem to vary much as to rapidity of growth, and they must be exceedingly difficult to diagnose correctly, from their close resemblance to fibroid outgrowths of the uterus.

It is remarkable that we do not see them oftener, when we consider the changes the ovarian stroma undergoes from childhood to old age. *February* 19*th*, 1878.

9. *Cysts in connection with the ovaries occurring in twin infants.*

By Arthur Leared, M.D., F.R.C.P.

The specimens were obtained by Dr. McMahon, of South Norwood, from the twin children of a healthy mother, which were born about a fortnight after the time expected. They were of average size at birth, but although they then appeared healthy and took the breast naturally, it was evident at the end of a week that they did not thrive, and at the end of the third week it was observed that each had a cough.

One of them was jaundiced from birth, and was constantly constipated, the evacuations being remarkably white. At the fifth week from birth the stomach of this infant became so irritable that no food could be retained, and it died convulsed on the third day.

The body was small and thin, the gall-bladder was distended with bile; an explanation of which was found in the circumstance that there was no connection between the gall-bladder and the bowel. The pancreas was also unconnected in the same way. The bowels were distended with gas, and of a very pale colour. It will be seen from the specimen that there is a cyst the size of a filbert in connection with one ovary, and that there is a smaller cyst in connection with the other.

The other infant died of pneumonia a fortnight after the death of the first. In this case a cyst about the size of a small pea was found attached to each ovary. In every instance the cysts contained only fluid.

The interest of these specimens lies in their extreme rarity. I cannot discover that any instance of an ovarian cyst in an infant has been recorded in our 'Transactions.' It is probable that the cysts were congenital. The evidence of imperfect development in two important organs, namely, the gall-bladder and the pancreas, taken in connection with the existence of the cysts, is interesting. The specimens were presented to the Museum of the Royal College of Surgeons. *May* 21*st*, 1878.

VI. DISEASES, ETC., OF THE OSSEOUS SYSTEM.

1. *Hyperostosis of the lower jaw, right parietal bone, left clavicle, and tibiæ; cancer of the lung.*

By W. Cayley, M.D.

George C. A—, æt. 65, a teacher of music, was admitted into the Middlesex Hospital under my care on September 7th, 1878, and died on October 6th. He was unable to say whether any members of his family had suffered from cancer or any affection of the bones. His previous health, up to four and a half years ago, had been very good. He then began to suffer from severe dyspeptic symptoms, which have continued more or less ever since, and about the same time he had pain in the lower jaw, where a fistula formed. In May, 1873, he consulted Mr. Nunn, who noticed enlargement of the jawbone. Shortly after he was attacked by severe rheumatic pains in the legs, lasting many months, and his legs became curved. During the last eighteen months he has had cough and spitting, and a year ago he began to spit blood. The hæmoptysis continued for about six months off and on, sometimes he would spit up as much as half a pint of bright red blood in a day; latterly he has been losing flesh very fast, and has had very severe pain after taking food.

State on admission.—Patient is a tall, old man, much emaciated, the lower jaw, which is edentulous, with the exception of the incisor teeth, is much enlarged by a general thickening affecting all its parts. There is an ill-defined prominence of the right parietal bone, the left clavicle is much thickened, and both tibiæ are curved forwards and thickened. None of these bones are now the seat of pain or tenderness. Numerous punctiform cutaneous nævi were noticed on the trunk. Patient has a bad cough, spits up considerable quantities of purulent mucus, and complains much of very severe

epigastric pain after food, lasting for several hours, and often terminated by vomiting.

The right side of the chest is much flattened, and the resonance over it considerably diminished, and its expansion impaired; the breath sounds are feeble, and over the upper part of the lung tubular. The heart is displaced to the right, the impulse being most distinct about the right nipple, and here a loud musical systolic murmur is audible. No impulse could be felt beneath the left nipple or to the left of the sternum, and percussion in this region was resonant. There was much epigastric tenderness, but no tumour could be felt.

After he had been in the hospital a few days he again began to spit blood. The blood was intimately mixed with the purulent expectoration and of a dark colour. He gradually became weaker, and on October the 5th was seized in the night with severe dyspnœa, which was accompanied by mucous rattles over his chest. In the afternoon of October 6th he suddenly brought up a large quantity of blood, which poured from his mouth and nose, and he died.

On *post-mortem* examination the right lung was found to be much shrunken and retracted behind the osseous ribs, whilst the anterior margin of the left lung passed beyond the middle line. The right pleural cavity was obliterated by old adhesions, and the pleural membrane converted into a tough fibrous layer, which at the lower part was dense and white, and measured nearly half an inch in thickness. The upper lobe of the right lung presented some irregular excavations, and scattered through the lung, especially near its root, were several white cancerous nodules, about the size of hazel nuts. Microscopically the nodules presented the characters of medullary cancer, and the thickened and white pleura was found to be infiltrated with cells resembling those found in the nodules. The bronchial glands were indurated and pigmented.

The left lung was free from adhesions, and contained no cancerous deposits. It was pigmented and emphysematous.

The heart was relaxed, its walls of a brown colour and easily torn. The mitral and aortic valves were the seat of extensive calcareous deposit.

The liver contained about eight or ten white nodules, generally about the size of a cherry stone; they presented on microscopical examination the same characters as the deposits in the lung. No

cancer was found in any other part of the body. The mucous membrane of the stomach was much thinned.

The calvaria was found to be much thickened, the thickening being most marked in the right parietal region. The bone here measured five eighths of an inch in thickness, it was of rather soft consistence and presented a fine porous texture; it was also very light, and there was hardly any distinction between the diploë and the outer and inner tables.

The lower jaw was uniformly enlarged, and its alveolar border projected beyond that of the upper one, with which it could not be brought into apposition. All the molar and præ-molar teeth were wanting, and the sockets of the molar teeth, except that for the first right and the last left one, were filled up by bone. The socket of the first right molar was much enlarged, and would admit the tip of the little finger; it was continuous with the socket, for the adjacent bicuspid, which had itself ulcerated through the anterior surface of the jaw. The alveolar border of the bone was greatly expanded, especially in the molar regions, where it measured in depth two inches and a half. The rest of the bone was also greatly increased in thickness, the groove and foramen for the inferior dental vessels and nerve were remarkably deep and wide. The condyle on each side had a short thick neck, and the sigmoid notch was wider and less deep than usual. The angle was very obtuse as in edentulous jaws. The clavicles were unsymmetrical, the right one was of normal appearance, it weighed one ounce and a half, and measured two and one eighth of an inch in circumference at its central part. The left clavicle was much enlarged and misshapen, the circumference at its middle measured two inches and three quarters; it only weighed, however, a quarter of an ounce more than the right one, showing that the increase in size was not due to any increased formation of bone earth.

Both tibiæ were much thickened and curved forwards; a vertical section was made of the right one; the medullary cavity was found to be enlarged, and occupied by a cancellous bone, with wide meshes, in which the medulla was lodged, which consisted of a gelatinous or mucoid material of a yellowish colour. The compact tissue formed a layer, varying in thickness from a quarter to half of an inch, and after maceration was found to be unusually porous in texture. The tibia measured thirteen inches and a half in length, the transverse diameter of the head was two inches and a half, of

the shaft from two inches to one and a half, of the lower end one and seven eighths. The fibulæ appeared normal, the surface of all the affected bones was somewhat rough and porous.

The metatarsal and phalangeal joints of the great toes presented erosions of cartilage and white incrustations resembling those of gout. There were no cancerous deposits in the bones.

November 20th, 1877.

---

2. *Two cases of hyperostosis and tumour of the bones.*

By JAMES F. GOODHART, M.D.

CASE 1.—*Symmetrical sarcoma of both ossa ilia, of spine and cranium, associated with hyperostosis of the skull, and osteo-arthritic changes in the vertebræ.*—Harriet D—, æt. 60, was admitted to Guy's Hospital on September 9th, 1874, under the care of Dr. Wilks. She was a dairy woman. Her family history is said to have been healthy. She has been twice married and has had a family. Three months ago, before her admission she began to suffer pain under the shoulder blade, down the back, and in the hips. For six months she had been getting thinner, occasionally she had had difficulty in micturition.

She was admitted with paraplegia; reflex action was only to be excited on applying a hot spoon, and she ad a large bedsore over the sacrum. The urine was normal, temp. 98·8°. Catheterism was necessary, cystitis came on and she died somewhat unexpectedly ten days after her admission.

At the autopsy the following conditions were found: the body was emaciated but not to extremes, no dropsy, no scars. The skull was enormously thick (2 centimètres). The external table comparatively smooth, the internal tough and tuberculated, with deep fissures in it for the vessels of the dura mater. The latter membrane was rather adherent. The section of the bone showed a homogeneous slightly yellow but more grey surface; the diploë all obliterated and no distinction existing between the one table and the other. The bone was soft but very heavy. In two places on the left side and one on the right there were circular yellow patches seen on the inner table of the skull. They were only very slightly raised above

the surrounding level; they extended through the whole thickness of the skull; were more prominent on the outer table than the inner; and were each about the size of a shilling. They looked rather like nodules of cancer, but so little were they showing their tumorous proclivities, *i.e.* of growing beyond the natural confines of the part, that at first it seemed probable they were merely tracts of the diseased bone undergoing more advanced fatty changes than other parts in their vicinity. They were all separate.

Spine.—On the right side in the upper dorsal region (second, third, and fourth) some bosses of hard new growth projected slightly from the substance of the bodies and welded the bones together by a tough tuberculated mass, which looked not unlike the nodular masses found in some extreme case of osteo-arthritis when that disease attacks the spine. The articular processes of the lumbar vertebræ and some of the dorsal also had irregular overhanging edges as in osteo-arthritis. The bodies of the vertebræ were many of them in a similar state to the bones of the skull; in place of porosity they exhibited yellowness, opacity, density, and softness. The laminæ were in a similar state, and some of them had flattened plates of new material protruding into the spinal canal. The new matter in the vertebræ had a tendency to enlarge the vertebræ at the expense of the spinal canal, which was in fact considerably decreased in size. The part where this was most observable was opposite the second lumbar vertebræ. It did not seem, however, that this was anywhere sufficient to cause paralysis, and that symptom is explained by the fact that opposite the fourth lumbar vertebra and rather to the right side of the median line a nodular mass of new growth, similar to that elsewhere, had attacked the laminæ of the vertebræ, and growing backwards had formed a prominent tumour in the muscles of the back, and forwards had passed into the spinal canal amongst the large nerve trunks below the cord.

The ilium on each side was the seat of a large growth; bony in great part, but having an external shell of soft tissue. That on the left side was the larger, indeed, it filled up the whole of the iliac fossa, and separate nodules grew over the pelvic brim, and narrowed the pelvic cavity. On the opposite side the growth was similar but smaller, and grew from the substance of the bone above the posterior superior spine. One nodule was discovered at the base of the bladder compressing the right ureter.

The *brain* weighed 45 oz. Its membranes were a little thick, and

its convolutions shrunken. The brain substance was firm but not sclerotic. The ependyma a little sandy and thick. The nerves at the base all healthy.

The *spinal cord* was quite healthy both to the eye and under the microscope.

The pleuræ were healthy, except that beneath the right pleura two small plates of bone were found. These were small growths similar to the disease in the pelvis. The lungs were healthy except for some emphysema and a good-sized pulmonary embolism in the right lower lobe.

The *heart* weighed 10 oz. The pulmonary valves were thick, and the aortic valves had a few vegetations upon them. The *liver* weighed 71 oz. It was healthy. The *spleen* weighed 3½ oz.

The *kidneys* weighed 15½ oz. The left was very large and studded with minute suppurating points. The right contained some small abscesses. The bladder was in a state of intense cystitis. The joints were normal and the rest of the skeleton normal. The preparations are preserved in Guy's Hospital Museum, 1132[55], 1132[56], 1069[30], and are the same as those referred to by Sir James Paget in a footnote in his paper in the 'Transactions of the Royal Medical and Chirurgical Society,' 1877.

A microscopical examination of several of the nodules of new bone showed that the tumour was undergoing very extensive ossification and calcification. In this way a very open-textured trabecular bone tissue was produced, the spaces of which were filled by rather large round nuclei. There was a very little soft growth at some parts of the surface of these nodules, but it was very little, and it also seemed on the point of undergoing calcification in most places; where it was not so, it also was crowded with round nuclei. No spindle cells were found anywhere, and I am therefore disposed to call the growth a medullary sarcoma. The thickened bone had characters very usual in such cases, viz., many and large canals; the bone substance hyaline on section and hardly bony; the corpuscles badly formed and more like irregular nuclei than osseous lacunæ.

CASE 2.—*Periosteal sarcoma of the ilium, spine, ribs, femur, and clavicle, with abnormal density of the skull, mediastinal cancer, and cancer of both supra-renal capsules.*

Francis P—, æt. 55, was admitted to Guy's Hospital, under Dr.

Moxon, on March 25th, 1876. He was a hop dealer, twice married, his first wife having had many miscarriages, and only two out of nine living children. His father and mother were dead, the latter of paralysis; of eight brothers and sisters, one went out of her mind, and he knew nothing of the others. He had always been subject to fits of dizziness and had gonorrhœa in early life, but he had enjoyed good health till September, 1875, when he had so much pain in the left side that he could hardly breathe.

On admission he had a good deal of pain about the right hip and pain in the left side. There was little to be made out, and repeated examination failed to show anything tangible; but after a time thickening could be detected about the great trochanter, and creeping pleurisy was detected at the left base, and the man slowly but surely emaciated. Subsequently some tumours were noticed in the skin in various parts. He died exhausted some six months after his admission. His temperature was never high.

The body was emaciated, hair blackish grey. The skull was rather thick and the diploë gone. The bone looked yellow and felt heavy. There was no cancer in it. The adjacent edges of the bodies of the vertebræ rather nodose and, opposite the second dorsal vertebra on the anterior surface of the body, a layer of new growth occupied the fibrous tissues on the spine. A section of the bones was made but the substance of it looked healthy. The *ribs* were extensively affected by the new growth on both sides. Separate nodules appeared in various parts in the course of the bones, and in two places large superficial areas involving two or three ribs were seen as thick nodular plates bulging into the cavity of the pleura; in all cases, however, the growth was round the bone, not within it, *i. e.* periosteal and not medullary. Both *clavicles* at their sternal end had a large growth round them, the bones themselves being still dense and normal. The rest of the bones of the upper extremity and the glands were unaffected.

In the lower extremities the right ilium had a large nodular mass of soft growth covering the lower part of the iliac fossa and the body of the pubes. Thence it spread in various directions. The head of the femur was invaded by the new growth, and in the medulla below the lesser trochanter was also a small nodule of new growth. The knees were somewhat distorted and bowed outwards and with a little osteo-arthritic tuberculation around the margins of

the articular cartilages and about the great trochanter. But the bones were all quite healthy with this exception.

At the upper part of the right lung a considerable mass of growth had enlarged the bronchial glands and caught the superior cava and azygos, and considerably narrowed these trunks. The lymphatic glands elsewhere were normal. The skin in various parts of the body had bean-sized nodules of new growth in it. Each supra renal was enlarged to three or four times its normal size by white growth. The spleen contained a small abscess and the kidney a yellow infarct. The rest of the viscera were healthy. Microscopically the new growth is a cancer; a fibrous stroma forms irregular alveoli, which contains cells of all sizes, but all of them having a well-marked epithelial type. So markedly is this the case that the structures might almost be called an epithelioma; but after staining and hardening I have found a good deal of spindle-cell sarcoma tissue also. The nodules in the skin, pelvic growth, mediastinal and supra-renal tumours were all examined, and they all presented identical appearances.

The interest of these cases centres upon two points. First, that they are cases of hyperostosis associated with malignant disease. Secondly, that the hyperostosis, though present decidedly enough to link these cases with others that have been described, is yet of quite subordinate importance to the tumorous outbreak of the bones.

With reference to the first point, it may be remarked that taking Sir James Paget's cases in the 'Transactions of the Royal Medical and Chirurgical Society,' vol. lx, Dr. Cayley's case of late before this Society, and these two cases, or at least one them, we have five out of seven, or six out of eight, in which cancer of some sort was present in addition to the osteitis deformans, a proportion so remarkable as to take it beyond the range of a coincidence. What the connection may be between the so-called osteitis and the malignant growth it will appear to some to be mere idle speculation to suggest, but I venture to say that, inasmuch as several of these cases have been years and years pursuing a course of simple enlargement of the bones and eventually end in cancer, there is strong ground for taking them to support the theory of the evolutional origin of malignant from innocent cell growth. This is as yet hardly admitted by many, but it is an admission that will be made some day.

As to the second point, it will be objected by some that these cases are not cases of hyperostosis at all, but rather of primary cancer of the bones. I should admit fully that these two cases are much more cancerous than hyperostotic, but I should also urge that since in most cases of osteitis deformans, cancer appears towards the end of the disease, some connection or other is established between the two processes, and there is no reason why the latter should not in some cases start earlier than usual, and before the more regular chronic changes of osteotis have had time to develop.

This is not all so visionary as it may at first sight seem, and in such a disease as this, where a whole tissue is attached, some light is to be obtained by seeking for analogous conditions in other tissues, and indeed we have two very precise analogies. In the first place, there is the subcutaneous connective tissue, which is liable to general hypertrophy all over the body, and there are numerous cases on record where such hypertrophic parts have ultimately become cancerous, and there is a still better example of disease of a whole tissue in enlargement of the lymphatic glands all over the body. In that tissue the glands may slowly enlarge for years, and glide imperceptibly from chronic inflammation or hypertrophy into active growth, or in other cases, instead of going through such a lengthened process, actively growing glands crop up all over the body, infiltrate the tissues with which they are in contact and kill as rapidly as these bone cancers do. In the one as in the other there is the chronic hypertrophy; in the one as in the other there is the growth of malignant tumours. Without going far still other examples might easily be found of this affection of tissues as a whole throughout the body, and it is but fair to add that if such a condition does exist in the cases now under consideration, it points most forcibly to a constitutional origin of the disease, and for the same reason against the local origin of cancer, a view in some cases that has of late received much support.

January 4th, 1878.

3. *Hyperostosis of the tibia.*

By T. W. Nunn.

Dr. Cayley exhibited for Mr. Nunn cast of a leg from a case in which there was hyperostosis of the tibia apparently of a rheumatic origin.

Mrs. P—, a lady, æt. 75, came under Mr. Nunn's care in May, 1871, for a solid swelling of the left leg with a curving forward of the tibia. The leg measured fourteen inches in circumference against twelve and a half inches on the opposite side. The affection was supposed by the patient to have commenced from a fall out of bed, by which the leg affected was bent under her, previous to the occurrence of the swelling of the leg the patient experienced severe rheumatic pain in the knee.

In October, 1871, after an attack of eczema, the swelling of the leg somewhat subsided.

In May, 1872, the general swelling of the leg had disappeared, but the tibia remained greatly enlarged, and it was believed that the curving had increased.

In May, 1873, there was a thickening of the right humerus and solidification of the right biceps flexor cubiti, crippling of course the arm.

In December, 1873, there was a sudden and intense pain in the heel.

The following year at the same month constant and distressing cough with much expectoration.

May, 1877.—Troublesome cough, pain in the chest and nausea.

November, 1877.—Enjoying fair health for a person eighty-one years of age.

Family history.—Father died, æt. 87; he had in his youth rheumatic fever. Mother died, æt. 86. She had eleven children, three of whom died in infancy. The eldest son, always healthy, lived to the age of 85; the second son died, æt. 75, gouty; the third died abroad from cause unknown; the fourth child was Mrs. P.; the fifth, a son, who was rheumatic, died æt. 79, of paralysis; sixth, a daughter, living, æt. 77, rheumatic; seventh, son, living, æt. 76, rheumatic; eighth, a daughter, died, æt. 49, of heart disease, having had rheumatic fever at the age of twenty years. There is no history of cancer in the family. *November 20th*, 1877.

4. *Hyperostosis of the tibia, associated with curvature of the shaft (osteitis deformans) and the development of a spindle-celled sarcoma in the upper epiphysis.*

By H. G. Howse, M.S.

The patient from whom this specimen is derived was a lady whom I saw in consultation with Dr. R. Harris, of Hackney, to whom I am indebted for the report.

Mrs. M—, æt. 65, enjoyed tolerably good health until two years ago, when she began to suffer constant aching pain in the right leg, which she considered rheumatic, having suffered from rheumatic fever in early life and having had occasional rheumatic pain since. She thinks two years ago that the bone was quite straight; it has since, however, gradually become slightly bent. In September, 1875, she consulted Dr. Harris for intense pain referred to the inner side of the head of the tibia; the aching pain in the shaft continuing, but without aggravation. At this time there was no swelling to be detected at the painful spot. The only abnormal appearance was due to the curving of the tibia, the concavity being to the inner side. At this time she was able to walk without much difficulty. A week later, a small rounded swelling became evident on the lower side of the head of the tibia, regular and globular in outline, firm in feel, but fluctuating to the touch. It presented much the appearance of an enlarged bursa. On the appearance of the tumour the pain diminished, but did not entirely cease. The swelling gradually increased until the middle of November, when it was tapped with a fine trocar, with the effect of drawing off a small quantity of thickish serous fluid, at first clear, afterwards blood-stained. Bleeding to the extent of about one ounce occurred from the puncture during the night. The swelling could not be emptied, though it became less tense. In a few days it had become quite as large as before. By the middle of December the swelling had become more elongated; fine blood-vessels ramified over the reddened surface. I was now asked to see the case, and on close examination detected very faint pulsation in it. The swelling was about the size of a small orange, was not tender, but the pain was greater after manipulation. It appeared not to affect the knee-joint, but the knee had got bent and useless. On December 21st the

patient was placed under chloroform, and an Esmarch's bandage applied. The swelling was then cut freely into, and was found to be, as suspected, a large soft fungating tumour occupying the centre of the upper epiphysis. With the consent of the friends, the patient being still under chloroform, the limb was immediately amputated in the lower third of the thigh, under the carbolic spray. The stump healed primarily; all the pain ceased, and she was able to get up and move about for some months. About five months after the operation, serious lung symptoms began to appear. These had already shown themselves at the time of the amputation, but no very positive evidence of anything beyond a chronic bronchitis existed. There was no albuminuria. The patient died from the lung trouble after a few weeks' illness. A *post-mortem examination* was refused, but there could be little doubt that death took place from recurrence of the tumour in the lung. No curvature nor undue thickening could be detected in any other bone in the body.

This specimen was kindly examined by Sir J. Paget, and he concurs in the opinion that it belongs to the group he has described under the term "osteitis deformans." The tumour in the head of the bone was a large spindle-celled sarcoma. A transverse section of the thickened bone, examined microscopically, showed that the ordinary Haversian systems were much altered, and more resembled sections of cancellous tissue. The walls of the cancelli, however, were rather thick and tolerably abundantly sprinkled with bone corpuscles. The contents of the cancellous spaces were a few fat vesicles, rather more connective tissue elements than usual, and germinal cells, unlike ordinary marrow-cells, and more like similar elements usually seen in cases of scleriasis of the skin. Scattered amongst these were numerous groups of yellowish pigment masses, probably derived from blood extravasations. It is possible that these extravasations may have some relation to the purpuric affection described in the next case.

When this case first occurred to me I regarded the thickened tibia and the tumour as expressions of the same constitutional condition. That, in fact, bone belonged to the class of hardened connective tissues, and that the large spindle-celled sarcoma also was a perversion from the normal formation of connective tissue. In a communication to the Roy. Med. and Chir. Society ('Trans.,' vol. lx) Sir J. Paget, however, has taken a different view of these cases, in regarding the thickened bone as due to a low form of inflammation, and the occur-

rence of *tumour* in connection with it, as more or less accidental, though he admits that it existed in three out of five of his cases. This proportion, large as it is, has been still further increased since that paper was written. And I would suggest the inquiry whether the tumour in all the known cases of the disease, although called "cancer", is not really of the nature of malignant sarcoma, or, at any rate, one of the forms of connective tissue tumour, rather than one of epithelial origin. It is probable that, amongst sarcomata, the bone disease is related as certainly to the tumour, as a persistent chronic eczema of the nipple is to a carcinoma developing in the interior of the breast amongst epithelial growths,—using that term as including all the true carcinomata. *January 4th*, 1878.

---

5. *General hyperostosis with osteo-arthritis in a living subject.*

By H. G. Howse, M.S.

William C—, æt. 37, was admitted under my care into Guy's Hospital on June 6th, 1877. He was suffering from hyperostosis of many of the bones of the body, with osteo-arthritis of several joints. He is a tall, well-built man, of fairly healthy appearance. The following is a detailed statement of the condition of the various affected bones and joints. As the patient may come before the Society again at some future period, rather more exact measurements are given than would be otherwise necessary. It should be premised that none of the long bones are at all bent.

The *left knee* is very much swollen, the normal outline of the joint being quite destroyed, the circumference at the middle of the patella being seventeen inches. Fluctuation is very distinct in the joint on each side of the patella, it is especially so over an area as large as half a crown, just below the external condyle. The patella can be moved over the condyles with a distinct crackling movement. He can flex and extend the knee with difficulty, distinct crackling being felt by the hand placed on the joint whilst this is done. Along the external and internal condyles little irregular osseous deposits can be felt.

The *right knee* has a circumference of fifteen inches. Fluctuation can be felt on each side, and there is evidently fluid in the joint. There is marked swelling on each side and above the patella, but this is much less than on the left side.

Femora.—The lower end of each femur appears to be enlarged, and on the right side there is some tenderness over the lower quarter of the bone.

Left tibia and fibula.—There is a certain amount of thickening just above the ankle. At a point 2½ inches above the ankle-joint, the left tibia measures 2⅞ inches from the anterior to the internal line; at the same spot the circumference of the leg is 10⅞ inches, while 2 inches above this spot the circumference is 11⅛ inches. There are two scars over the seat of the old injury as we have mentioned. The fibula does not seem so much enlarged.

Right tibia and fibula.—The right fibula seems rather enlarged at its lower end, the enlargement extending up the lower quarter of its length. The tibia is large, but not especially so; measurements were taken at the same points as on the left side. The right tibia measures 2¼ inches across; the circumference of this leg taken at the same points as on the left side are 9 inches and 10 inches respectively.

Right forearm.—There is a pretty uniform enlargement of the lower three quarters of the forearm, ending abruptly at the wrist-joint. At a point three inches above this joint the circumference of the arm is 9 inches, while the left arm at this point measures 7⅛ inches. The enlargement is apparently due to swelling connected with both radius and ulna, in which both bones appear to share equally. The superficial veins over the part are much enlarged, and the temperature appears to the hand raised. He also says it is tender to the touch. The movements of the wrist-joint seem unaffected, and both pronation and supination are pretty free.

The *left radius* appears to be slightly enlarged just below its middle. The *left elbow* is swollen and somewhat tender, and there is some fluctuation on each side of the olecranon.

Clavicles.—Both clavicles are very large and massive. The *right* is larger decidedly than one would expect in even as muscular and hard-working a man as the patient is. The *left* is considerably larger than the right, and very much larger than normal.

Ribs.—All the ribs on both side are very massive, and the lower ones appear considerably enlarged.

Head.—Patient has always been accustomed to wear a soft cap, and although he has felt this "to be tight at times," he is not aware that he has had to get larger caps at any time. His head is 22½ inches in its fronto-occipital circumference.

The condition of the viscera, both thoracic and abdominal, was apparently healthy, with the exception of the kidneys. The urine gave decided traces of albumen in repeated testings; was, as a rule, rather dark in colour for healthy urine, but in amount, acidity, specific gravity (1020), scarcely differed from the normal. Once it deposited a slight mucous cloud, which, examined microscopically, showed bladder epithelium cells and a few crystals of uric acid, with one or two granular casts. My dresser, Mr. H. Davy, undertook a quantitative analysis of four specimens of the urine, under the supervision of Dr. Debus, but arrived at the result that the normal constituents were not materially altered. In other respects he seems quite well, eats, drinks, and sleeps well, except when a little troubled with the pain in the affected joints and bones.

The *history* the patient gives of himself, as it seems to bear somewhat upon the causes of so obscure a complaint, must be given in some detail.

Family history.—Father and mother both dead. Mother died of *cancer of the breast.* Cause of death in father unknown. Has lost three brothers and seven sisters, of whom the causes of death are unknown.

Personal history.—To the age of twenty years he enjoyed perfect health; was employed in carrying great weights as a corn and deal porter. At that age he enlisted in a line regiment, and remained in the army twelve years, serving eight years abroad, principally in Jamaica and Malta. Since he left the army he has been employed at a corn warehouse to turn the corn, and for the last three years as a gas-stoker, to push the coal into the retorts. Both employments he considers would throw undue stress upon the right forearm and the left clavicle, the bones of which are principally affected.

History of all his illnesses.—1st. Sixteen years ago, just after he entered the army, he received a kick on the left leg from a fellow soldier. The stocking and trowsers were cut through and driven into the flesh. He was laid up six weeks from the effects of this

and remained all this time in the hospital at Aldershot. Whilst in the hospital an abscess opened on both the inner and outer side of the leg, but he says no bone came away, and that it got all right again. The scars of these two openings are situated on the outer and inner side of the leg, about six inches from the malleoli. Patient says that immediately after leaving the hospital he noticed that the bone of the leg was enlarged, and that in fact it has not altered in size from that time up to the present.

2nd.—About fourteen years ago he had sores on the penis. He says that these consisted of warty growths underneath the foreskin, and that they were cut off. He does not remember that he had any discharge from the urethra at this time. Since this he has had sore throat many times, but this has always passed away in a few days without any special treatment. The worst he has ever had was about five or six years ago, when it had to be rubbed over with nitrate of silver. He has never had an eruption of any sort on his skin.

3rd.—About ten years ago he had yellow fever, from which he quite recovered.

4th.—About eight years ago he fractured his left humerus at about the junction of the upper with the middle third. The callus of this fracture can still be readily felt.

5th.—Seven years ago, whilst practising ball-firing in Nova Scotia, he slipped off a plank, and his left ankle was twisted under him. He was in the hospital over three weeks, and the ankle was blistered, &c. At the end of this time he was told to walk; his heel was drawn up, and for six or seven months he had to do light work, limping about with a stick. At the end of this time he says he began to put his heel to the ground. As soon as he did this the left knee began to swell. It was blistered, &c.; but as it got no better he was invalided from the army and sent home. For two years he worked in a corn warehouse, as he could limp about and use his hands. During this time his knee was swollen and pained him of an evening, after he had been about on it all day.

6th.—After this he slipped and fell down on his knee, which swelled up and became so painful that he was admitted into Guy's, under Mr. Birkett, on August 6th, 1873. The report of this date gives substantially the same account of his previous history as we have done. It states that he was suffering from chronic synovitis of the left knee. His condition on admission is thus described:—

"Left knee-joint is swollen very much, being eighteen inches in circumference. The skin is not discoloured although it feels very hot. The patella can be felt, but there is bulging on each side of it and above the joint. He can walk on the leg, and can flex the joint without pain and nearly extend it. The outline of the joint is, however, lost; there is much fluctuation in it, and occasionally he is troubled with shooting pains in it."

Whilst in the hospital his leg was strapped to a back splint and Ung. Hydrarg. applied. From a marginal pencil note by the Registrar, it appears that after he had been in some time it was noticed that the "left tibia is thickened from below upwards for two thirds of its extent."

He was discharged on September 30th, much relieved, but with his left knee still swollen.

7th.—Since this the knee has always been a little stiff, and he could feel crackling in it; but he has always been able to get on with his work at the gas works. Last Easter (about April 1st) he noticed that the right arm was swollen, and it has greatly increased in size since this. About the same time he noticed much pain in the small of his back. He says, also, that after he had been at his work all day, in the evening his urine was quite dark—as dark as porter, but that when he passed water in the morning it was light-coloured and normal. Shortly before admission his right wrist became red and tender, but this passed off.

He is unmarried, and has been a "hardish drinker," for the last two years especially, his usual allowance having been four or five quarts of beer and some spirits every day.

He was treated with five-grain doses of iodide of potassium with cinchonine. A fortnight later an eruption consisting of dark purple purpuric blotches, not fading on pressure, came out on his legs and thighs. The medicine was continued for a fortnight longer, the condition of the joints seeming to improve slightly, but that of the bones remaining *in statu quo*. At the end of this time, as the rash still persisted (though diminished), and as it was thought possible it might be due to the iodide, it was discontinued, and $\frac{1}{12}$th-grain doses of perchloride of mercury substituted. About a week later the eruption entirely disappeared. As regards bones and joints he remains in much the same state as when first seen. He has been up once or twice for a fresh bottle of the iodide, which he finds distinctly relieve the joint affection, though it seems to have no influence on

the bones generally. He refused to continue the perchloride on account of its nastiness.

The interest of this case lies in its relation to the cases of "osteitis deformans" brought by Sir James Paget before the Royal Med. and Chir. Society (*vide* 'Trans.,' vol. lx). After examining this case Sir J. Paget came to the conclusion that it did not come under the affection described by him on account of the absence of any evidence of curvature about the bones, from which character, and not from the mere enlargement, he applied the term "deformans." He considered that the *bending* would be evidence of altered nutrition, and of a retrograde change going on in the substance of the bones themselves, which would be entirely absent in this case; and that hence this case might probably be one of simple ostitis depending on syphilis, gout, or some other cachexia.

It seems to me doubtful, however, whether these cases are not much more closely related than Sir James Paget supposes, and it is with a view to inquiry on this point that I have brought them before the Society. I would suggest the possibility of this being an early stage of osteitis deformans occurring in a comparatively young subject. Most of the cases hitherto recorded have been in much older patients, and hence they do not appear to have passed through the condition of thickened bones without bending. At any rate the stage of simple thickening has not been noticed, the first symptom exciting attention being the bending. It must be admitted also that iodide seemed to do some temporary good in this case, at any rate for the joint affection, whereas it was quite inoperative in Sir J. Paget's cases.

The principal points of difference, then, in the two cases will be—(1) absence of curvature; (2) the joint affection; (3) the youth of the patient; (4) the action of the iodide. The principal points of resemblance: (1) the thickening of the bones; (2) the apparent futility of treatment as far as concerns permanent benefit; hence (3) the duration of the affection; (4) the history of a family cancerous cachexia (in the mother).

The question remains whether, as this patient grows older and the tendency to retrograde metamorphosis of his tissues becomes greater, the *bending* will not supervene, and possibly even whether some sarcomatous tumour in connection with one of the enlarged bones form, and thus convert the case into a typical one of "osteitis deformans."

January 4th, 1878.

6. *Case of impacted fracture of the shaft of the femur.*

By Thomas Bryant.

The preparation exhibited was taken from the body of a man, æt. 83, who was admitted into Guy's Hospital, under my care on January 7th, 1876, having fallen down some area steps.

The man believed he fell upon his right knee.

On admission the right thigh was much swollen and shortened to the extent of two inches, and the shortening could not be diminished by extension. The crepitus of fracture was felt above the knee, the position of the foot normal. The diagnosis made was fracture of the femur in its lower third, though the inability to extend the limb to its normal length was a source of difficulty. The limb was put up in Hodgen's splint, and everything went on well for three weeks, when symptoms of uræmia appeared, and death ensued on the 25th day.

At the *post-mortem*, suppurating kidneys were found to account for death, and an impacted fracture of the shaft of the injured bone.

The shaft of the bone had been clearly fractured at the junction of the middle with the lower third, and the extremity of its proximal end was driven to the extent of an inch and a half into the shaft of the distal portion: this process of impaction splitting the shaft of the distal extremity of the bone and producing a second fracture of the bone above the condyles (see Woodcut 5).

Woodcut 5.

Remarks.—The preparation exhibited proves that impaction of one broken end of the shaft of a long bone may take place into the other, as well as impaction of the shaft of a bone into its epiphysial extremity, or *vice versâ*, although, so far as my own knowledge is

concerned, this is the only preparation in existence which demonstrates the fact.

The accident must, however, be rare, since it can hardly occur otherwise than in the way the present accident was produced, viz., by a fall upon the distal end of the bone.

The practical bearing of the fact illustrated by the specimen is also great, for while it tends to explain why, in certain cases of fracture, extension fails to restore the limb to its normal length, it at the same time suggests the propriety, under these circumstances, of leaving the parts alone rather than by over manipulation of running the risks which necessarily attend the complete separation of the fractured fragments and more particularly dangers from vertical fissures of bone. *February 5th*, 1878.

---

7. *Very extensive caries of spine leading to fatal pleurisy.*

By Arthur E. Barker.

This case shows acute fatal pleurisy, caused by presence of large abscess in front of and due to diseased dorsal vertebræ, but without bursting of abscess.

M. W—, æt. 13; died Feburary 4th, 1878. On examination after death the following conditions were observed:—Acute pleurisy on right side, with collapse of lung. Pleurisy on left side, but not to same extent, the lung being also less affected. Heart normal; liver enlarged (68 oz.), firm and smooth, and glistening on section, amyloid reaction distinct. Spleen enlarged, firm, pale and fleshy, amyloid. Kidneys enlarged and nodular, pale, amyloid. Behind the root of each lung a large abscess bulged out on either side of spine into the pleural cavity. On its surface the pleura deeply congested and livid. The abscess, the walls of which are very thin, lies upon the front and sides of spine as far as upper dorsal vertebræ, and runs down as far as diaphragm, stripping off in its whole course the anterior common ligament and its coverings. It communicates under the diaphragm by a narrow passage on the right side, with two psoas abscesses one on each side. The left of them runs down in front of the muscle under Poupart's ligament, and then branches, one division following the

sartorius sheath for about three inches, the other running along the inner side of the great vessels as usual into the thigh. This abscess is about one and a half inches in diameter at its widest, fining off at either end. It communicates with that on the other side. The latter is shorter, but in other respects the same. Another abscess covers the whole front of the sacrum, but has no outlet below in perineum; above, it overflows into a large carious cavity lying between the eroded bodies of the fourth and fifth lumbar vertebræ. From this pus makes its escape into the large lumbar abscess opened a few days before death, and lying about the buttock. All these abscesses are lined by a grey tough, pyogenic membrane, and contain white curdy pus with granules of bone.

The first and highest abscess springs from the diseased tissue of the bodies, of most of the upper dorsal vertebræ, the intervertebral ligaments appearing unaffected. The bodies are eroded in almost their whole circumference but only superficially. The eroded surface is covered by smooth, pulpy granulations, turning grey from sloughy action in parts. The diseased process is plainly seated, chiefly in the bones, not in the ligamentous structures. The latter are comparatively unaffected, the intervertebral disks being exposed, and white but not much altered. The anterior common ligament is stretched by the underlying pus, but is not much changed, and its processes to the disks are still strong.

The greatest amount of disease, however, exists in the lumbar vertebræ, and adjacent surfaces of the second, third, fourth, and fifth being quite destroyed to a considerable depth, as also the interposed cartilage completely. Here the movement is extremely free between the upper and lower part of the spine, and as the body lies on the back the lower end of the upper portion drops backwards by its own weight about half an inch. The pus from this portion drains backwards into a lumbar abscess, but also into the sacral one. The latter appears to lie under the periosteum of the sacrum, which in its whole anterior surface is bared by it and is becoming carious. This abscess as mentioned, above, does not open on the perineum, where there are fistulæ, however, but of the ordinary kind.

There are also scars from old sinuses in the left groin, and one open in the right.

On cutting the column vertically in halves the cord is found perfectly intact even at the most bent point. At three or four spots, one high up and another lower down in the dorsal and one in the upper

lumbar region, the pus from along the column has reached the dura mater, bathing it pretty freely; but on opening the latter no trace of inflammation is observed, the cord and membranes appearing quite healthy.

The body, intervertebral discs, and ligaments of the second, third, and fourth lumbar vertebræ are all destroyed. The discs of the other healthier portions of the column appear peculiarly soft and pulpy. *February 5th*, 1878.

VII. MORBID GROWTHS.

1. *Congenital dermoid cysts occurring in the branchial, and other clefts.*

By W. W. Wagstaffe.

The specimens which are now brought forward have perhaps a greater interest from the fact of the subject of defective closure of the branchial clefts having recently attracted the attention of the profession at a meeting of the Medical and Chirurgical Society; and in the course of the discussion which took place upon the subject of branchial fistulæ, it was suggested that some of the cysts of the neck might, in like manner, be the result of imperfectly closed branchial fissures. The cases which I have to show this evening bear directly upon this question, which has been carefully studied in France by Mons. Cusset, at the suggestion of Dr. Leon Tripier, who was in England during last summer, and brought the matter under my notice. I am not aware that any cases have been brought forward in England in support or otherwise of the view that dermoid cysts of the face and neck are due to imperfect closure of the branchial clefts, and though I have carefully searched among English authorities, I do not find that the possibility of such a mode of origin is noticed.

The first of the three specimens was removed from a man named B—, 25 years of age, on Oct. 19th of the present year (1877). My notes of the case state that "there was a tumour at the inner angle of the right orbit, rather above the middle line, somewhat triangular in shape, evidently fluctuating, adherent below and at the inner side to the walls of the orbit, but not adherent to the skin, attached apparently to about the junction of nasal process of superior maxilla and the lachrymal, covered by orbicularis."

In size it appeared to be about one inch across, but it was difficult to say how deeply it extended into the orbit.

It was not tender or painful; did not vary in size, but sometimes seemed darker in colour than at others. It had existed since he was a year old, he said, and had followed an injury, and did not seem to have increased much since it was noticed, for a photograph, taken when he was 12 years old, showed the tumour proportionally as large as it was now. The question of injury as a cause I inquired into further, and received the following letter from his elder sister: "Sir,—The lump in my brother Richard's eye was caused by falling on the corner of a stool when he was about a year or two old, or a month or two more. My eldest brother and myself were learning him to walk from one to the other, when he fell on one side. It fetched blood, but very little, and it looked like a long vein with a lump in the middle, the size of a very small pea."

Seeing that the tumour, whatever it was, had such a definite attachment to the bone, and that it had not diminished or increased materially since its first appearance in early life, I could not but discard the notion of its being the result of the injury referred to, and looked upon it as probably a congenital tumour; and if so, was it a sac communicating with any of the cavities of the skull? Examining carefully, I could find no evidence of this. It did not produce any cranial pain on pressure; it did not affect the passage of the tears; it did not become altered in character on blowing his nose.

The age of it was rather against a sebaceous tumour, and moreover, it was very deeply placed and had no connection with the skin.

As the man wished to have it removed I excised it, making an oblique incision downwards and inwards towards the inner angle of the orbit. The orbicularis was exposed, and its thin pale fibres divided. The cyst was then exposed, and was extremely thin and adherent to the fibres of the muscle. It was found necessary to open the cyst, and the contents, which were partly clear fluid, partly opaque white masses, were evacuated. It was now found that although the prominent part of the cyst was very thin and almost transparent, the deeper attached part was very dense and of a yellowish-white colour; and when this deeper part was removed, the point of attachment was about the junction of the lachrymal with the upper part of the nasal process of superior maxillary, by a base about a quarter of an inch broad. The lachrymal sac was not seen or disturbed.

The wound was dressed with chloral oil, and healed without any complication.

The contents of the cyst, when examined microscopically, showed fine hairs, some epithelium, and a large quantity of oily matter.

The accompanying diagram, Woodcut 6, A, represents the point of attachment of the tumour.

WOODCUT 6.

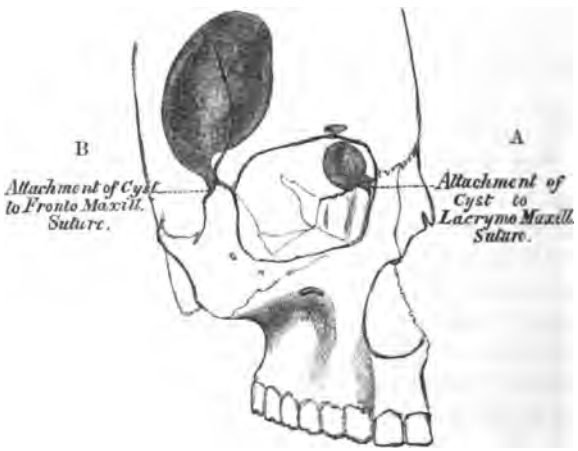

The above woodcut shows the points of attachment of the congenital dermoid cysts to the cranial sutures. The cyst on the left side, A, represents that of Case 1 attached to the lachrymo-maxillary suture. That to the right, B, relates to Case 2, in which the cyst was attached to the fronto-maxillary suture. For convenience the two cases are included in one diagram.

The second or largest specimen was removed from a young man, H. G—, seventeen years of age, on November 6th of the present year (1877), and was situated in the right temporal region. My notes state the tumour was "behind and over the right supra-orbital ridge, size of half a pigeon's egg, soft, fluctuating, but rather like an imperfectly-filled cyst than a tense one, and even doughy to the feel; skin nowhere adherent, and the anterior branch of temporal artery crosses it obliquely, orbicularis contracting over the tumour apparently; tumour movable freely downwards and forwards, but not backwards or upwards, apparently connected with bone about fronto-malar articulation." At the base of the tumour, on its inner

side, was a hard edge, feeling as if the temporal ridge was displaced inwards about half an inch, and deeply behind the fronto-malar articulation one could feel a hard nodule like a tooth projecting from the floor into the tumour. There was no pain on pressure.

It seems that it was noticed when he was only six weeks old, and was then about the size of a pea, and it had grown slowly without any pain, but during the last six months it had increased very much, and had become very unsightly. It had not, however, varied in colour, and had never diminished.

Seeing the depth and attachments of the tumour and the history of its almost congenital appearance, I concluded that this was also a case of congenital dermoid cyst, and probably growing from the fronto-malar suture.

As it was growing fast, and was large already, I removed it, making an oblique incision. The fibres of the orbicularis were exposed, and found stretched over the tumour, which was everywhere rather adherent. The exposed part of the cyst was thin and readily torn. The contents were, therefore, evacuated, and proved to be a pearly-white, waxy secretion, resembling sebaceous matter, but quite inodorous. The capsule was then carefully removed, but with some difficulty, and was found to be attached by a very firm yellowish-white and fibrous base to the fronto-malar articulation. The projection into the floor of the cyst, which felt like a tooth or piece of bone on external manipulation, proved now to be a hard lump in the root of the cyst, and the apparent deformity of the frontal bone was entirely due to marginal thickening round the cyst, just as is found at the edge of a hæmatoma.

The wound, which was necessarily a deep one, was closed with sutures, and healed without any complications.

The secretion of the cyst when examined with the naked eye contained numerous hairs, and microscopically was almost altogether composed of little fatty masses, of the shape and size of epithelial scales, many fine hairs, some with imperfect bulbs, but nowhere were any crystals of fat or cholesterine found.

The position of attachment of the tumour is indicated in the diagram (Woodcut 6, B).

Sections were made both through the lump noticed near the root and also through what appeared to be a representative part of the walls. From the appearances in the latter it would seem that above the investing connective tissue is a layer of well-defined epithelium, that

the papillary layer is not well represented, but that the epithelium, at first resembling that seen in the deepest layer of the epidermis, becomes gradually more flattened and condensed, until it is almost horny. Still nearer, however, to the interior of the cyst is a thick layer of succulent tesselated epithelium. There is also an appearance of a glandular structure in the deeper layers of what I have looked upon as the epidermal layer, or between it and the connective-tissue layer, and in one section this glandular-like structure followed the site of hairs running into the deeper subepidermal layers.

The lump referred to as existing at the root of the growth was composed of a greatly hypertrophied epithelial layer.

The third specimen was removed from a child named H—, only seven months old, on the 14th of December, 1877, and had been noticed since birth. Like the others, it was deeply placed and adherent, and it was apparently increasing a good deal. It was situated above the outer angle of the right orbit, and when operated on was found to be intimately adhering to the external angular process of the frontal bone, about the position of the fronto-malar articulation, but by no very distinct pedicle. Its contents were, like those in Case 2, steatomatous, and consisted of much fatty matter, mixed up with delicate hairs.

Although congenital cystic tumours of the orbit are referred to as of not uncommon occurrence by some authors, they appear to be most usually situated in the outer angle,[1] and not in the position occupied by the first of the cases here referred to. But besides the peculiarity of position here noticed, there were points of interest that stand out in perhaps greater relief by comparison of the three cases.

In each the tumour, though at first sight very superficial, was found, on careful examination, to be quite free of the skin; in each it lay deeply, and was obviously under cover of the orbicularis, and in one case under the temporal artery; in each there was evidently a firm attachment to bone. In each, therefore, there was a means of diagnosing the nature of the tumour.

But it is further noticeable that the point of attachment was in each case to a line of suture, and that from the neighbourhood of this line of suture the root sprung with evident origin—that the tumour had not dipped in from the skin so much as that it had

[1] Holmes, 'Surg. Dis. Children,' p. 38. Paget, 'Surg. Path.'

started from the suture and made its way towards the skin, for its base was in each case so extremely thick and firm and adherent.

Moreover, it cannot be overlooked that the points of attachment coincide with the position of a closed branchial cleft—of that between the parts developed from the trabeculæ cranii and those from the first post-oral arch.

My attention was called to this subject by M. Leon Tripier during the present year, and I am indebted to him for a pamphlet by M. Cusset, 'Sur l'appareil branchiale des Vertébres,' which treats at length of the faults of development in these branchial clefts. It is, however, for M. Verneuil[1] that is claimed the merit of having suggested the origin of dermoid tumours of the outer angle of the orbit and mouth in a faulty closure of the branchial cleft, and M. Broca[2] for those occurring at the inner angle of the orbit. However, Rémak,[3] in 1854, had suggested a similar origin for cysts of the neck, and had been supported in his views by Roser and Hensinger.[4] M. Cusset now collects a large number of cases bearing out the same view, and concludes, with reference to dermoid cysts of the face, "that they have all a constant situation, which corresponds with an anterior branchial fissure."

Following all the parts developed from, or in connection with, the different branchial arches, he has submitted a diagrammatic plan of the lines along which these dermoid cysts ought to be found, and a copy of this plan (Woodcut 7) is here appended. These lines represent those of the branchial clefts, and we ought, accordingly, to find congenital defects along them, in the way of fissures, fistulæ, and cysts.

I have searched rather carefully through a large mass of literature, and have been unsuccessful in obtaining much information upon the subject, and very little that can help to arrive at a positive conclusion with regard to M. Verneuil's theory. That a portion of dermal tissue or some dermal elements may be caught in, as it were, during the closing of the branchial arches, and ultimately form a dermoid cyst, is a reasonable hypothesis, and will

[1] 'Archiv. Gén. de Méd.', 1855, 3me sér., t. 6.
[2] 'Traité des Tumeurs,' 1869, t. 2, p. 78.
[3] 'Deutsche Klinik,' 1854, No. 16.
[4] Loc. cit., p. 28.

undoubtedly account for many, if not most, of the dermoid cysts found in the face.

WOODCUT 7.

To illustrate origin of dermoid cysts of the face, the woodcut indicates the lines showing the position of the branchial fissures (after Cusset).

(*a*). Between parts developed from trabeculæ cranii and those from first arch.
(*b*). Between upper and lower masses of first arch (maxillary).
(*c*). Between first and second arch (stylo-stapedian).
(*d*). Between second and third arch (hyoid).
(*e*). Between third and fourth arch.
(*f*). Below fourth arch.

The three cases I have narrated support this view; and the occurrence of branchial fistulæ[1] in like manner demonstrates this. And so far must this, I think, be accepted, that the situation of a cyst or fistula along one of these lines of the branchial fissures must be admitted as presumptive evidence that the cyst is dermoid or the fistula of branchial origin.

But it must be admitted that dermoid cysts have occurred where no branchial cleft existed. They rarely occur, I believe, out of the middle line of the body, except in the face and neck. I find no mention of them in the limbs or trunk, except in the ovaries, where, "even independently of impregnation, one discovers so many signs

[1] M. Cusset tabulates 49 of such cases.

of great capacity of development;"[1] and a casual reference is made to their occasional occurrence in the lungs and testes, but I do not know where the cases are to be found narrated. But in the 25th volume of our 'Transactions' an interesting case of dermoid cyst is recorded as occurring on the forehead, and simulating a meningocele. Mr. Holmes also refers to a case apparently like this, which occurred under M. Giraldès,[2] where a congenital dermoid tumour lying over the anterior fontanelle was mistaken for a meningocele.

There is also in the museum of St. George's Hospital[3] a skull in which a dermoid cyst occurs inside, in the dura mater, near the torcular Herophylli.

These cases show that dermoid cysts of the head are not necessarily developed along the lines of branchial clefts, but they do not oppose the general result arrived at by M. Cusset. They may, in fact, be accounted for in a very similar way from the retention of dermoid elements during the process of closure of embryonic clefts —clefts which may be either branchial or along the median line of the body.

In order to judge whether dermoid cysts are necessarily associated with developmental fissures, I have drawn up a table of such cysts occurring in unusual positions in the face and neck—by unusual meaning those occurring anywhere excepting at the common situation at the outer angle of the orbit, and the sublingual cysts, which are comparatively frequent and probably dermoid. I find records of 24 cases of dermoid cyst occurring elsewhere than at the outer angle of the orbit or beneath the tongue, but it is often difficult to learn what attachments the tumours had, as they are frequently only loosely reported. However, out of 23 in which it is possible to form some conclusion from the records, it would seem that 16 were probably situated along the line marked (*a*) in the diagram (Woodcut 7), *i. e.*, between the parts formed from the trabeculæ cranii and the first branchial arch; probably 1 or 3 along the line marked (*b*) between the two masses of the first branchial arch; and 1 or possibly 3 along the line marked (*c*) between the first and second arch; along this line may perhaps be placed the sublingual cysts referred to.

Of the whole number, 10 were situated at the inner angle of the

[1] Paget, 'Surg. Path.,' vol. ii, p. 90.

[2] 'Leçons Cliniques,' p. 342.

[3] Holmes, 'Surg. Dis. Child.,' p. 39.

orbit, 3 at the root of the nose, 2 at the floor of the orbit, 1 at the intermaxillary suture, 1 in the lower jaw, and 2 either in or near the external auditory meatus.

Besides these, there are three curious cases where dermoid cysts have been found, not along any of these lines in the head, but in the median line, 2 over the interfrontal suture, and 1 at the torcular Herophylli.

The right side seems rather more liable to these cystic developments in the proportion of 9 to 2.

I suppose that the questions of practical importance arising out of this subject are—

1. Are these tumours of the face and head recognisable as dermoid cysts before removal?

2. Are they best treated by early removal? and the answer must, I think, be given generally in the affirmative to both of these.

3. Are they developed along the lines of branchial fissures, in accordance with M. Verneuil's theory?

The answer to this question is more difficult, and it seems to me that we shall be right to go further, and look to the lines of any embryonic fissures, as those along which such cysts may be expected to occur. *January 15th*, 1878.

Abstract of Cases of Dermoid Cyst found in unusual position on the Face, not including the outer side of the Orbit.

Case.	Author.	Sex and Age.	Position.	Size.	Remarks.
1	Cruveilhier, 1817, 'Path. Anat.,' t. iii, 498.	Girl, 9-10 years old.	To naso-frontal suture.	Size of a large pea outside, but dipping deeply.	Punctured only apparently, hairs extruded.
2	Lawrence, 'Lond. Med. Gaz.,' 1838.	A young person.	At root of the nose, between the two lids.	Size not given.	Incomplete removal, would not heal, removed remnant of cyst with hairs.
3	Ditto, ditto.	Not mentioned.	At the root of the nose.	.....	Incomplete removal, would not heal, remnant of cyst with hairs removed.
4	Richet (Cusset), 'Journ. d'Ophth. de Galczowski,' 1872.	Boy, 16.	Inner angle of right orbit, above lachrymal sac, under orbicularis.	Size of a filbert, not fluctuating, noticed since birth as a pea, increased since 5 years old.	Removed, walls possessed hairs.
5	Richet (Cusset), 'Receuil d'Ophth. de Galczowski,' 1874.	Man already aged	Inner angle of right orbit, traced in operation to the frontal.	Similar to previous one.	Operated on 22 years before ligatured, now excised and root treated with chloride of zinc.
6	Fano (Cusset), 'Journ. d'Oculist et de Chir.,' 1873-4, t. i, p. 42.	Male, 15.	Inner angle of left orbit, immediately above the eyebrow.	Size of an almond, said to have been noticed only 6 months, rapid increase 2 weeks.	Excised, tumour walls examined and found composed of skin elements.
7	Tripier (Cusset).	„ 19.	Inner angle of right orbit deeply, evidently attached below and to inner side, found attached to lachrymo-maxillary suture.	Size of a large nut, noticed immediately after birth as a small grain, increased only since 16.	Operation, removal, dense by attachment, hairs.

Case.	Author.	Sex and Age.	Position.	Size.	Remarks.
8	Tripier (Cusset).	Male 20.	Inner angle of right orbit deeply, evidently attached below and to inner side.	Size of a large nut, elastic, noticed at birth, increase slow, hereditary antecedents nil.	Not operated on.
9	Wagstaffe(now reported).	„ 25.	Inner angle of right orbit deeply, attached to lachrymo-maxillary suture.	Size of filbert, noticed when 1 year old, very gradual increase.	Removal, cyst contained hairs.
10	Broca (Cusset).	A young woman.	Middle of lower border of orbit, root-like prolongation, attached to border of lachrymal.	Size not given, congenital.	Punctured and injected in vain, excised.
11	Spencer Watson, Ophthalmol. Congress of London, 1873.	Female, 49.	Floor of right orbit.	Fistula on inner side of orbit, rapid growth after a blow, producing displacement of eye inwards.	Front of cyst removed, interior made to suppurate.
12	Ditto, ditto.	Child, 12.	Over inner third of upper eyelid.	Fistulous opening, surrounded by hairs, rapid growth and inflammation after a blow.	Incision at first, entire removal of body.
13	Taylor.	Boy, 13.	Inner angle of left orbit.	Apparently like above case.	Removed.
14	Barnes, 'Med. Chirur. Trans.,' 1813.	„ 17.	Attached deeply towards ethmo-maxillary suture.	Size of small pea, noticed since infancy, increased rapidly after 12th year, till it filled greater part of orbit.	Removed, composed of two sacs, one contained a tooth.
15	Verneuil (Cusset).	Female, 24.	Occupying whole anterior aspect of the face on right side, found attached to border of intermaxillary suture.	Very large, bulging in front of upper jaw and lower jaw, noticed several years gradually increasing.	Removed, wall composed of skin structure.

Case.	Author.	Sex and Age.	Position.	Size.	Remarks.
16	Renault (Cusset), 'Arch. de Phys.,' 1872, p. 762.	...	External auditory meatus.	.....	Cavities hard, with ciliated epithelium.
17	Clerault, 'Bullet. de la Soc. Anat.,' 1874, p. 983.	Child.	Middle of palatine arch, attached by a pedicle to fissure, tumour hanging into mouth.	Size 1·5 × 6 cm.	? Removed, composed of two lobes, hairy outside, fibro-cellular inside.
18	Mikulicz, 'Wiener. Med. Wochn. Schr.,' 39 and 40, 1876.	Female, 19.	Over right half of lower jaw, bulging between incisor and 2nd molar.	Size of chestnut, noticed since 2 years old gradually increasing, taken for an osteoma.	Incised, walls scraped, removed wall.
19	Arnott, 'Path. Trans.,' xxv.	Child, 8 months.	Below anterior fontanelle, attached to inter-frontal suture.	Size of large walnut, simulating meningocele, congenital.	Died of pneumonia, specimen in St. Thos. H. Mus.
20	Giraldès, Holmes' 'Surg. Dis. Ch.,' p. 39.	Child.	Below anterior fontanelle.	Simulating meningocele.	Removed.
21	Holmes, loc. cit., 41.	Child, 2½.	.....	Died of brain symptoms.	Tumour containing hair, attached to dura mater by torcular Herophylli.
22	Osborn, 'St. T. H. Rep.,' vol. vi, p. 72, 'Ophth. Rep.,' vii, 245.	...	In front of ear above tragus, and another in the ocular cleft.	.....	.....
23	Mac Cormac, 1874, 'St. T. H. Rep.'	Boy, 16.	At root of nose in median line, attached deeply.	Size of large Barcelona nut.	Tumour contained hair.
24	Hamilton, 'Dub. Q.,' 64.	...	Inner angle right orbit, adherent for 1 inch along inner wall of orbit.	Translucent cyst, base evidently firm.	Tapped, cauterised.

2. *Specimen of cystic tumour of the thyroid gland successfully removed from the living subject.*

By John Wood, at King's College Hospital.

The tumour was situated in the median line of the neck and chest, reaching from the level of the upper border of the thyroid cartilage to the middle of the sternum, between 4 and 5 inches below the supra-sternal notch. It measured 24 inches in circumference and 9 inches in its lateral diameter, overlapping on each side the sterno-mastoid muscles. It was tense, elastic, and lobulated, with distinct fluctuation in its central and upper part. A median depression with a vertical direction could be felt, and in this could be seen a large venous trunk of the size of a saphena vein, which was joined by numerous lateral and radiating branches over the surface of the tumour. At the sides and below could be felt a solid formation, yielding no fluctuating impulse. The tumour could be lifted up from the sternum below, and from the sterno-mastoids at the sides, and then appeared to possess a broad pedunculated base, pushing aside the origins of the sterno-mastoid muscles, and attached closely to the larynx and trachea, by the motions of which, in deglutition, it was lifted up and down. The skin and fascia over it were movable, and the reticulated superficial veins could be seen all over the surface of the tumour. At the upper and lateral portions of its circumference the enlarged superior thyroid artery could be distinctly felt pulsating, and as large as, or larger than, the radial at the wrist. At the left lower portion also the inferior thyroid could be distinguished, but on the right side opposite no pulsation could be felt. On the front part of the mass, where the tension of the cyst was greatest, small, hard, nodular masses could be felt chiefly along the lines of the veins. There was evidently a great amount of tension in the cyst or cysts contained in the tumour.

The patient, Caroline P—, was a married woman, æt. 28, who had had three children. She was in a fair condition of health, but her lips were pale, and she seemed somewhat languid and depressed by her deformity, which she described as having been a great trouble to her, from increasing interference with the power of swallowing and

the dragging pain, weight, and tension of the tumour. It had been forming fourteen years, and had been growing of late much more rapidly. She was very desirous of being relieved from it, and was fully aware of the risk which such a formidable proceeding would probably involve. There was no exophthalmos, nor had she palpitations or beatings in the head or ears, and she ate and slept well, but thought she had been getting thinner lately since she had worried herself about the tumour. She was put upon iron, cinchonine, and the liquid extract of ergot of rye. The local treatment consisted, first, in emptying the cyst by means of the aspirator by a puncture in the median line at the lower part of the tumour, after a week's preliminary application of a bag of ice to diminish the vascularity of the mass.

Forty ounces of a dark serous fluid were drawn off, highly albuminous, and containing altered and shrivelled blood-cells in abundance, to which the colour was owing.

The result of the puncture was to cause a great depression by atmospheric pressure in the centre and upper part of the tumour, leaving a solid and hardish mass on each side and below, having altogether somewhat of the saddle-shape of the normal thyroid. This was easily movable to a limited extent upon the deeper parts, but dragged the trachea and larynx with it.

After emptying the cyst the puncture needles, connected with a Stöhrer's battery of thirty-five cells, were passed into the solid mass on each side, and a current of galvanic electricity passed through for a quarter of an hour. Three days afterwards the fluid had again accumulated, and the tumour measured 20½ inches in circumference.

On the 23rd October the cyst was again aspirated, and 36 oz. of fluid drawn off, lighter in colour than the first tapping, but of the same general character. Then, through another puncture made while the aspirator was in action, a strong solution of iodine with glycerine was passed into the cyst, and about one half of it left in the cavity.

On the 27th October the cyst was again emptied of 26 oz. of a lighter coloured fluid, and the galvano-puncture repeated with 15 cells for twenty minutes.

On November 2nd the tumour again measured 20 inches, and some darting pains were felt in it. The patient complained of headache, and the tongue was white. There was some discoloration and

ecchymosis between the galvano-punctures, and the integument felt somewhat œdematous. The patient complained of giddiness and palpitation, and a slight febrile reaction was apparent.

She wished much to have the tumour removed altogether, wishing to get home to her family, and indisposed to remain long enough in the hospital to give a fair chance to the galvanic and injection treatment.

On the 10th November, 1877, accordingly Professor Wood removed the whole of the diseased thyroid gland under the antiseptic spray and dressing, kindly assisted by Professor Lister and his staff of experienced assistants.

A vertical incision in the median line over the tumour, reaching from the thyroid cartilage to the middle of the sternum, was first made through the integuments and cervical layers of fascia, passing also through the deep fascia which invests the gland from the deep fascia of the neck, but not touching the vessels which were distributed over the gland itself.

The integuments and fascia were then dissected back on each side, and the finger passed round the tumour in the loose areolar tissue which separated it from its capsule derived from the deep cervical fascia, so as to isolate it on each side and below. A trocar and canula were then passed into the cyst, and 24 oz. of a dark sanguineous serum were drawn off. While this was being done the ecchymosed tissue around the puncture broke down under the grasp of the forceps, and a considerable branch of the thyroid artery began to bleed. This was at once stopped by passing with a curved handled needle a stout hempen ligature on each side of the opening through the cyst wall, and tying it up firmly. Each of the groups of vessels supplying the tumour were then made out and isolated by the forefinger, and stout, double hempen ligatures soaked in carbolic lotion were passed with the handled needle and securely tied, and the vessels divided between them, the ligatures being cut off short. The tumour was then rapidly dissected from its deeper connections, a considerable artery in the position of the "thyroidea ima" being cut and tied immediately. A small portion of the apex of the left upper lobe which had been left was then religatured and dissected out without the slightest bleeding. The dissection exposed the larynx, trachea, sterno-mastoids, and sheath of the carotid vessels. Not more than 8 oz. of blood was lost in the operation. The patient was a little faint at first, but this soon passed off, and, with the ex-

ception of some difficulty in speaking and swallowing, no unpleasant symptoms were apparent on the evening of the day of operation nor on the following morning. The pulse was then 140, and the temperature 101° F.

On the 13th the pulse was 124, temp. 100⅘° F.

On the 14th the pulse was 129, temp. 102⅘° F., with slight cough and headache.

On the evening of the 16th the pulse was 110, and the temp. 103° F.

On the 17th pulse 104, temp. 100⅕° F.

On the 18th the pulse fell to 96, and the temp. to 98⅘° F.

On the 29th severe pain was felt in the calf of the right leg, and there was swelling and œdema from the ankle to the calf, with tenderness along the course of the great saphena vein in the thigh and groin.

Next day the whole leg was enlarged to nearly double the size of the other; pulse 102, temp. 100⅕° F. After treatment by hot fomentations and bandaging, with flannel and cotton wool, the swelling, pain, and tenderness disappeared.

On the 17th December one of the hempen ligatures, which was put on double and the ends cut off short, made its appearance through a sinus which had been kept open by a drainage-tube.

On the 23rd the left leg began to be affected with pain in the calf, swelling, and tenderness along the saphena. These symptoms were, however, not so severe as those in the right leg, and with the same treatment soon subsided.

On the 1st January, 1878, the patient was up and about the ward.

On the 19th an œdematous fold of skin, which was redundant on each side of the vertical incision at the lower part of the neck, was removed, and the wound brought together by wire sutures.

By the 1st February the wound was nearly healed. A small sinus remains, however, at the upper part, which leads down by the side of the thyroid cartilage to a hardish substance, which feels like a piece of ligature thread. Its situation at any rate corresponds to the ligature placed on the right superior thyroid vessels.

The dressings throughout the case were conducted strictly upon Lister's antiseptic principles.

Dissection of the tumour.—The specimen consists of a unilocular cyst with thick walls placed at the upper and front part of an

enlarged thyroid. The enlargement is of the nature of simple hypertrophy or *adenocele*. The cyst is of the capacity of 40 oz., lined by a smooth membrane and presenting some projections or processes on its interior, one of which, attached a little above the middle of the right posterior wall, is about 2 inches in length, conical and tapering like one of the musculi papillares of the heart cavity. Its base is circular and attached opposite to one of the septa which separate the lobes of the hypertrophied gland tissue where a considerable branch of the right superior thyroid artery enters the substance of the gland. It seems to be the remains of one of the gland septa reduced and attenuated by the tension of the sac by its contents, and it may have been a source of the hæmorrhage into its interior. On its left may be seen a raised area, which formed the base of a similar formation. Shreds of lymph and easily torn layers of fibrin, which are also found on the inner wall of the sac, are probably the consequences of the iodine injection. The lobules of the glandular walls of the sac are well defined in the interior. The solid part of the tumour weighs 1¼ lb., and seems to be composed of the isthmus and lower part of the lobes of the gland. As shown by the dissection and the accompanying drawings it is enveloped by at least three layers of capsule besides the investment of the cervical fascia which was left in the patient. The deepest layer is a tough resisting fibrous framework, which closely invests and supports the gland tissue and ending in numerous septa between the lobes. Next to this comes a looser connective tissue, in which the smaller branches of the thyroid arteries ramify before entering the lobules by the septa. Outside this is a stronger and thicker layer of capsule, in which lie the larger arteries and veins, and which will be seen in the dissection still to invest them. The chief supply to the tumour is by the two superior thyroids, which are as large as the ulnar arteries. One of the inferior thyroids is but small and both of them ramified chiefly on the lower and hinder surface of the tumour. The veins chiefly join a large venous sinus, which lies in the investing capsule on the front of the tumour. This large vessel could be traced distinctly through the skin before the tumour was removed, though the usual blue colour of its contents was not present, yet the fulness and tension of the vessel could be made out and the vessel emptied by pressure. Its walls seem to be formed in the intimate investing capsule of the tumour, much in the same way as the sinuses in the dura mater. It opens

into the two superior thyroid veins, which were connected by transverse anastomosing branches uniting with this central vein.

The lobular nature of the solid part of the tumour is seen both on the outer posterior surface and from the interior of the cyst. In the posterior view of the preparation a portion of the intimate fibrous capsule is dissected off and the glandular substance exposed, showing the lobules into which the adenoid enlargement is divided by septa passing from the capsule between the lobes. The structure of these lobes appears to be the ordinary gland tissue of the thyroid.

The patient has recovered her health and strength wonderfully, and during the last fortnight, since the antiseptic dressing has been discontinued, two more ligatures have been discharged from the small sinus before alluded to, which still remains and discharges a little pus. She is here to-night for the inspection of the members of the Society. *November* 10*th*, 1877.

P.S.—Since the above was written the patient has entirely recovered her health and strength. The sinuses closed entirely a few weeks after she left the hospital.

---

3. *A case of multiple round-celled sarcoma in a boy.*

By Henry T. Butlin.

C. L—, a boy, ten years old, was admitted into St. Bartholomew's Hospital, under the care of Mr. Holden, in June, 1875. He was suffering from a tumour, the size of a walnut, which had been growing about a year in front of the left ear. The tumour lay beneath the integument, apparently in the substance of the carotid gland. It was firm, almost hard, in fact so hard in parts that it felt like cartilage. A second small tumour lay in the subcutaneous tissue, over the left side of the forehead, high up; from its general characters it was thought to be a sebaceous cyst. The parotid tumour was removed by operation, which proved to be much more difficult than was expected on account of the adherence of the growth to all the surrounding structures, its lack of capsule, and the free hæmorrhage which took place. The general and micro-

scopical characters of the tumour after removal were those of a round-celled sarcoma, for it was without capsule, very freely supplied with vessels, infiltrating all parts with which it came in contact, was of a greyish-brown colour, homogeneous, not fatty or caseous in any part, and was much softer after removal than it appeared to be before removal; whilst microscopically it consisted almost wholly of round cells about the size of, or rather larger than, leucocytes, with granular, intercellular substance, and tolerably frequent remains of fibrous or adipose tissue. The boy recovered completely from the operation and left the hospital at the end of a month. He returned in October of the same year, with the tumour of the forehead much increased in size, infiltrating the skin and subcutaneous tissue, and with a second tumour, bearing exactly the same characters, separated from the first by a slight interval. The larger of these two tumours measured ¾ in. across. The skin affected by them was of a dull blueish-red colour, not hot, painful, or tender. They had been slowly growing from the time he left the hospital. These tumours were removed by Mr. Holden, together with an ample margin of the surrounding tissues. Microscopical examination gave precisely the same result as the examination of the former tumour had done. (*Vide* Plate V, fig. 6.) In six weeks the boy left the hospital quite well.

From this time nothing was seen of him until he returned in August, 1876, suffering from enlargement of both testicles, the left having commenced to enlarge two months previously, the right a little later. Both presented the same characters; they were quite hard, generally smooth, but here and there projecting in the form of large nodules or tubers, not hot, painful, or even tender. The scrotum was not adherent, and beyond being slightly stretched was not in any way affected. The general feel of each testis was that of a cartilaginous tumour; the left was the size of a bantam's egg, the right smaller. The case had now attained such a degree of interest that two consultations were held, and doubts were expressed whether, judging from its peculiar course, the disease was really round-celled sarcoma, or indeed any form of tumour. On this account, although there was no appearance of syphilis in any form, it was thought well to place the boy upon mercurial treatment. This was carried out for several weeks with much care, but without the slightest improvement in the characters of the disease. Indeed the testicles both continued to increase steadily in size. At the

end of October the boy ceased to attend the hospital, but returned again at the beginning of September of the present year. The testes had almost doubled their size when last examined, the left being still much larger than the right, and both had exactly the same characters as formerly. The scars of the old operations were quite sound and free from all appearance of recurrence. A large tumour, much inflamed, of six months' growth, existed in the middle of the back of the right thigh; a small tumour of four months' growth in the skin and subcutaneous tissue below the left scapula. The boy had grown very much, and seemed well and strong in every respect, save that he complained of occasional shortness of breath and inability to run about as much as his companions. Examination of the chest failed to elicit any signs of disease. Since September he has been almost continually under observation. The tumour of the thigh has completely sloughed out, and has left a perfectly sound scar. The tumour of the back has more than tripled its size, and has become adherent to the skin covering it. A new tumour has appeared over the trochanter major of the right thigh, apparently in connection with the deep fascia; and within the last few days another tumour has rapidly formed in the skin and subcutaneous tissue over the left pectoral muscle. The left testicle has maintained a steady increase in size, but has not become adherent to the scrotum; it is now as large as a goose-egg. But the right testis has markedly *diminished* in size, still retaining, however, the same characters of hardness and nodulation as before.

This case presents many points of great interest, both clinical and pathological, but I will confine my attention as far as possible to the latter. I believe the original diagnosis of the nature of the disease to be correct. The tumours do not bear the stamp of being connected with any of the diatheses, or with syphilis, congenital or acquired. There is no appearance in the boy himself of any of these diseases, nor is there any family history of them. Even those tumours which have undergone the most rapid increase of size have not become fatty or caseous, and have not suppurated. With one important exception they have all increased in size, though sometimes very slowly. Their general characters, both before and after removal have always been those of sarcomatous tumours, and the microscopical characters have fully borne out this impression. It is not easy to understand the exact relation which these different tumours bear to one another. The most common view would pro-

bably be that the disease commenced in the carotid region, and that the tumours which have formed at various periods since then are secondary to this as the primary growth, having arisen by the carriage of germs or corpuscles by the blood to various parts of the body. If this be the case it is strange that the internal organs have not shown any signs of disease, whilst parts far distant from one another, unconnected by blood-relation, by lymphatics, or in any other way, so far as I am aware, are the seats of these secondary growths. I am inclined to believe that each one of these tumours is a separate and fresh outbreak of the original disease, due to some form of irritation acting upon portions of tissue in a patient who is in an extreme degree predisposed to this disease. Hitherto all the tumours have occurred in parts of the body which are exposed by their situation to injuries, or to the friction of clothes, or other such forms of irritation. Whether they are actually produced by such causes as these I do not pretend to say. There is no evidence that the disease is a blood-disease any more than there is evidence of the predisposition consisting in a local weakness of certain tissues. It is very probable that many cases which are regarded as a recurrence of an original tumour are really separate outbreaks of the same or similar disease. For instance, a man suffered amputation of the foot some years since in St. Bartholomew's Hospital, for a sarcomatous tumour. The local disease was completely removed, and the patient remained in good health and without any appearance of recurrence of the disease for upwards of four years. At the end of that period he returned to the hospital with a tumour of the inner aspect of the thigh of the amputated extremity, not in the situation of or connected with the lymphatic glands. This tumour was removed, but recurred *in situ*, and finally sloughed, until the patient was worn out by exhaustion. After death a secondary growth was found in the pleura, none in any of the lymphatic glands. It seems very improbable in this case that the tumour of the thigh stood in direct blood-relation to that of the foot, and that it had remained dormant for four years. It is certainly much easier to believe that these two tumours were separate outbreaks of the same disease, and that the tumour of the pleura was directly secondary to that of the thigh.

Cure of tumours by sloughing out is not sufficiently uncommon to call for any particular comment.

It is a point of great interest that up to this time the internal

organs (with the exception of the testes) have escaped infection, but there can be little doubt that they will be attacked ere long.

One might have expected that the tumours removed would have recurred *in situ*, but this particular form of sarcoma, provided it be thoroughly removed, does not appear to exhibit local recurrence as a prominent character.

The diminution in size of the right testis is a matter of great astonishment to me, for it is so marked and so considerable as to admit no doubt. The diminution in size of a tumour is of extremely rare occurrence. Cohnheim says, a neoplasm never spontaneously retrogrades and disappears.[1] This tumour certainly has not disappeared, but it has retrograded to a marked degree. What the nature of this change may be is not clear. Perhaps a form of fatty degeneration, in which the fatty elements have been removed as they were formed.

I hope to be able to bring forward the sequel of this case at a future meeting of the Society. *December 4th*, 1877.

---

4. *Spindle-celled sarcoma in the muscles of the calf, from a child aged five months.*

By W. J. Walsham, for Dr. Lewis W. Marshall.

This specimen, which was sent to me by my friend Dr. L. W. Marshall, Surgeon to the Children's Hospital, Nottingham, is a large spindle-celled sarcoma growing between the superficial and the deep muscles of the calf of the left leg, which was removed at the knee-joint by Dr. Marshall.

The following are the brief notes of the case furnished to me by Dr. Marshall:

"The patient was a female child, five months old, in perfect health. It was brought to the Children's Hospital, Nottingham, on January 20th, by its mother, who stated that a fortnight after birth a swelling was noticed in the middle of the left calf and rapidly attained its present size. The leg appeared enormously large and

[1] Cohnheim, 'Vorlesungen über Allgemeine Pathologie,' s. 658, 1877.

was found to be twice the size of the opposite leg, the one measuring 12½ inches, the other 6½ inches, in circumference. (See the accompanying photograph of the leg taken before amputation). The veins were much enlarged and the tumour had a semi-fluctuating feel, as if it were cystic, and the contents fluid. There were no enlarged glands in the groin. The surface was equal and not nodulated. On the 29th, a small needle of the aspirator was passed and nothing but a little blood and grumous matter removed; a large needle was then introduced, when a free escape of bright blood took place. The point was freely movable, thus leading to the belief that the disease was a malignant tumour or a sanguineous cyst; but the latter appeared the more probable because the child was in perfect health, the glands were unaffected, and there was the sense of fluctuation. Operation was decided on and amputation at the knee-joint performed. The child stood the operation well and has quite recovered the shock. The point of puncture was at the lower portion where the clot is. After the tapping the mass increased rapidly, and considerable oozing of bloody serum took place up to the time of the operation."

The tumour (see Plate VI, A), which extends from just below the articular surface of the tibia to within an inch of the ankle-joint, is situated between the superficial and deep muscles of the back of the leg. The gastrocnemius and soleus are evenly spread out over the posterior surface of the tumour, and the deep muscles, namely, the tibialis posticus, the flexors longus digitorum, and the flexor longus pollicis, are stretched over its anterior or deeper surface and can be distinctly recognised. All of these muscles appear to have undergone fatty changes.

The tibia and fibula are markedly flattened out, and curved with their convexity forwards by the pressure of the growth, forming, as it were, a cup-shaped depression, in which the tumour, separated by the posterior tibial muscles, lay. The tibia and fibula, in the middle third of the leg, are wider apart from each other than natural. The tibia in its middle third measures from its internal to its external border ⅞ths of an inch, whilst from its anterior border or spine to an opposite point in its posterior surface it measures only a ¼ of an inch (the proportion between these measurements being as 7 is to 2, whilst the proportion between corresponding measurements of a healthy adult tibia is as 3 is to 2.)

The fibula measures from its internal to its external border ½ an

DESCRIPTION OF PLATE VI.

Drawing A is taken from the photograph of a child aged five months, with a Spindle-celled Sarcoma in the Muscles of the Calf. Case exhibited by Mr. Walsham for Dr. Marshall. (Page 215.)

Figs. 1 to 4 illustrate Mr. Nettleship's specimen of Recurring Carcinoma of the Orbit. (Page 230.) From drawings by himself.

FIG. 1.—Alveolar spaces stuffed with epithelial cells. From a glycerine preparation. (× 425.)

FIG. 2.—Two alveoli partly emptied by pencilling. Some cancer cells are also imbedded in the wall between two alveoli. (× 425.)

FIG. 3.—Cells closely packed, with scarcely any intervening tissue, and no alveolar arrangement. (× 425.)

FIG. 4.—Formation of minute cysts by mucous degeneration. (× 120.)

FIGS. 1 and 2 are from the large infiltrating growths numbered 1 and 2 in the text. Fig. 3 is from the centre of one of the small movable subcutaneous encysted tumours, numbered 5 in the text; the periphery of the same tumour was distinctly alveolar. Fig. 4 from a soft portion deep in the orbit, undergoing cystic degeneration (No. 3 in the text).

A

Fig. 4

× 125

Fig 3.

× 425

Fig. 1

× 425

Fig 2

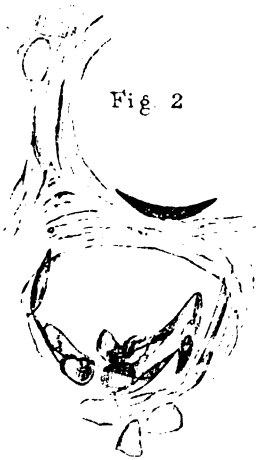

× 425

inch, and from its anterior border to the middle of its posterior surface only $\frac{1}{8}$th of an inch (by calipers). The intra-osseous space in its widest part (*i.e.* at the junction of the middle and upper thirds) is $\frac{1}{2}$ an inch across. The head of the tibia is also flattened from before backwards, and widened from side to side, its transverse diameter being $1\frac{1}{2}$ inches, its antero-posterior $\frac{1}{2}$ an inch. The limb is encased with a layer of adipose tissue from a $\frac{1}{4}$ to $\frac{1}{2}$ an inch in thickness.

The tumour is irregularly oval, with its long axis parallel to the limb. Its circumference, taken in the direction of its longest diameter, is $10\frac{1}{2}$ inches, in the direction of its transverse diameter, $6\frac{1}{2}$ inches. Its longest diameter on section is 4 inches, its transverse $2\frac{1}{2}$. It is surrounded by a capsule of condensed cellular tissue and appears to have enlarged by interstitial growth, not by infiltrating the surrounding muscles.

On section the basis substance of the tumour is cream white in colour and of a homogeneous or obscurely fibrous texture.

In its interior, near the posterior and inner surface, is a large cyst containing a clot of blood; the cyst, of an irregular oval shape, measures 3 inches in its longest, and $1\frac{1}{2}$ inch in its widest diameter.

Microscopically the tumour presents the characters of a well-marked spindle-celled sarcoma. It consists principally of spindle-shaped cells containing elongated staff-shaped nuclei; of free nuclei, some staff-shaped, some round; of granular material; and of very scanty intercellular substance displaying no alveolar arrangement.

From the situation of the tumour between the superficial and deep muscles, it is probable that it had its origin in the fibrous tissue forming the deep or intermuscular fascia of the back of the leg. *February 6th*, 1878.

5. *A specimen of colloid cancer of the breast.*

By W. Spencer Watson.

An unmarried woman, æt. 42, rather inclined to corpulence, and of a somewhat florid complexion, noticed a lump in her left breast fourteen years before she was seen by Mr. Watson (January, 1877).

There was no history of cancer in the family, which, however, was not a particularly healthy one. The lump had given her no pain, and had not increased in size till about four years ago, but has rather rapidly increased during the last two years, becoming also painful, especially at night. In January, 1877, it was of about the size of a hen's egg, very hard and nodular, and most prominent at the upper and axillary part of the breast. The skin was freely movable, except at the nipple, which was very slightly tucked in towards the side occupied by the tumour. Little or no pain or tenderness was complained of on manipulation. The growth was freely movable over the pectoral muscle. No enlargement of superficial veins. Glands in the axilla not felt, *i. e.* not large enough to be distinguished by touch from the surrounding tissues.

The tumour was removed at the Great Northern Hospital on January 31st, 1877. The subsequent progress of the case has been favorable, though some hæmorrhage came on on the third day, and the wound was very slow in healing. Up to the present date (Oct. 2nd, 1878) there has been no return of the disease either in the cicatrix or the axilla, and no indication of any of the internal organs having been affected. The general health has been better than before the operation.

To the naked eye, the tumour when cut across presented a number of translucent areolar spaces, the outer limits being defined by a distinct capsule and a nodular surface, quite separated from the surrounding fat at all points except near the nipple, which, with the surrounding skin, was adherent to the capsule and continuous with it. The gland tissue of the mamma had almost entirely disappeared.

Dr. Goodhart kindly examined the specimen microscopically, and

he reports as follows:—"I cannot see a single characteristic cell, . . . but I have no doubt that it is colloid cancer. I think so because the stroma is very alveolate and fibrous, and because the other colloid diseases of the breast have usually villous processes growing into them. This is really a scirrhus, with gelatinous material in its alveoli, and much fatty matter also."

My own microscopic examination of the growth inclines me to agree with this view, and I see that Rindfleisch's description of colloid cancer closely corresponds with what I observed in this specimen, viz. a fibroid translucent tissue surrounding alveoli, filled with glandular tissue in some sections, the spaces being completely filled with transparent fibroid tissue in others.

This case, therefore, is an instance of great rarity, and if the ultimate result of the operation should be as favorable as it at present promises will be a very remarkable argument in favour of operating for what may appear to be a form of schirrus in its clinical aspect, and pathologically an equally dangerous and malignant disease. Out of ten cases recorded in the 'Pathological Transactions,' the final result of operations was only given in one. But in Mr. Travers' case (subsequently operated on several times by Mr. Fergusson) the patient lived at least eight years after the first operation.

No.	Recorded by	Age of Patient.	Reference.	Results, &c.
1	Mr. Chas. Brooke	40 yrs.	Path. Trans., vol. xv	Not recorded.
2	Mr. W. Adams, for Mr. Price	54 yrs.	Vol. viii	Ditto.
3	Mr. Adams, for Mr. Fergusson	38 yrs.	Vol. v	Breast first removed by B. Travers in 1845. Recurrent tumour in cicatrix removed in Sept., 1848, and several removed by Mr. Fergusson in May, 1853.
4	Doubtful case	—	Vol. iv	Not recorded.
5	Mr. G. Critchett	42 yrs.	Vol. ii	Ditto.
6	Mr. De Morgan	56 yrs.	Vol. xx	Ditto.
7	Mr. De Morgan's report, a case of Mr. G. Lawson's	—	Vol. xx	Ditto
8	Mr. Butlin, for Mr. Savory	43 yrs.	Vol. xxvii	Ditto.
9	Mr. Croft	60 yrs.	Vol. xxiii	Ditto.
10	Mr. Croft	68 yrs.	Vol. xxiii	Ditto.

February 1st, 1878.

6. *Colloid cancer of rectum, anus, and buttocks.*

By R. W. Lyell.

This was a recent specimen of colloid disease affecting the rectum and anus, and invading both buttocks. It was removed from a woman æt. 46, who died in the Middlesex Hospital January 13th, 1878.

She was admitted on July 14th, 1876, under the care of Mr. Hulke, with a large, oblong, warty growth involving the anus and the skin immediately around, and extending up the posterior wall of the rectum as high as the finger could reach. Her condition was fairly good, the constitution not visibly affected, but the local suffering very considerable, especially prolonged after the act of defæcation. She had been married eight years, but had had no family, and menstruation at this period was regular. When twenty-two years of age she had suffered from some uterine complaint, with prolapse of the rectum and attacks of hæmorrhage; this lasted for some years. Her father died of cancer of the stomach.

The growth in the rectum began five or six years before her admission as a small hard lump forming by side of the anus, and unaccompanied by discharge; twelve months after a purulent discharge appeared. Till twelve months before admission the growth very slowly increased; then she fell downstairs, after which accident all symptoms were aggravated—with occasional attacks of hæmorrhage, increasing difficulty of defæcation, and intensification of local suffering.

To relieve the latter, which was then the most prominent feature of the case, the operation of left colotomy was performed six days after the patient's admission; the gut was found more than usually enveloped by peritoneum, and the operation was followed by a slight attack of localised peritonitis, which, however, subsided quickly. This operative measure was productive of marked benefit in relieving the sufferings of the patient, but the disease made steady progress, infiltrating the tissues of both buttocks, with a firm brawny swelling, the skin over which first becoming reddened and then ulcerating, formed a coarse warty granulation surface.

On July 9th of the following year the infiltration and ulceration

were spreading rapidly, and both buttocks were involved, although the disease had made greater ravages in the left than in the right. Considerable difficulty was experienced in keeping the artificial anus properly patent, owing to a strong tendency to contract and close, and thus to neutralise the beneficial effects of the operation, the presumptive cause of this being the inability of the patient to lie on the left side (the almost continual recumbency on the right side dragging the gut from the side of the skin), owing to the greater progress the disease had made in the left buttock than in the right.

On October 5th, 1877, the ulceration and growth had formed a large warty mass, burying the anus, which was hardly visible; the tendency of the artificial anus to contract had been to a certain degree remedied by the use of tents. The glands in both groins were enlarged.

She died from exhaustion on January 13th, 1878, exactly 543 days after the operation.

The *autopsy* was made fourteen hours after death. There was extreme emaciation, œdema of both feet, with fixation of the left hip in a flexed and adducted position. A large ulceration, measuring transversely about 5 inches in diameter, had destroyed in part the tissues of both buttocks, the left much more extensively than the right. Situated eccentrically in this ulceration was visible an irregular opening, somewhat depressed, which represented the position of the anus; from this the ulceration had extended outwards about 3½ inches on to the left buttock, and about 1½ inch on to the right; posteriorly it was limited by the coccyx, and anteriorly the infiltration extended into the vulva. The base of the ulceration was formed by a growth composed of a typical gelatinous or gum-like material, soft, trembling, and semi-translucent. The surrounding margins were infiltrated, thickened, and the skin covering them discoloured, of a brownish colour, not infiltrated to an equal degree, but ulcerating from growth of the jelly-like material beneath. On dissecting this from the buttocks the growth was found to extend deeply, filling both ischio-rectal fossæ and in front of the great sacro-sciatic ligaments, and on the left side slightly invading the gluteus maximus. From the ischio-rectal fossæ the growth passed into the pelvis, surrounding the rectum, and completely filled the whole of the lower part of the pelvis, from the coccyx to the vaginal septum in front. I had detached and partially laid bare the lower end of the sacrum at one point. For two inches

above the anus the natural tissues of the rectum had been completely invaded and destroyed by the growth, leaving a narrow channel, the walls of which were formed by the growth, and along which the little finger could just be passed. Above this the mucous membrane of the gut terminated by a well-defined, loose, very irregular ulcerated margin. The infiltration, however, did not cease here, but externally rose as a rounded, ovoid swelling, about an inch above the ulcerated margin of the mucous membrane, so that the extent of rectum from anus invaded was about 8 inches. In front the growth had invaded the posterior vaginal septum, forming an ulcerated surface here about the size of half a crown. The inguinal glands on both sides were enlarged, that in left groin being about the size of a pullet's egg, that on the right side smaller.

In the left loin the colotomy operation formed a slit-like orifice, about ¾ of an inch in length, which led easily into the gut above and below.

All the other organs of the abdomen were small and pale, and the kidneys somewhat granular, two small cysts being developed in the left.

To the unassisted eye, this growth destroying the rectum and anus appeared to resemble typical colloid or alveolar cancer, being composed in great part of a fibrous stroma, variable in its development, so arranged as to form spaces or loculi, which were filled by a soft gelatiniform substance. The development of the fibrous stroma regulated the density and firmness of the growth; in the more recent extensions of the growth the consistence was firm and fibrous, the loculi small, and the colloid material slightly developed; around the anus and also extending into the pelvis the microscopic alveolar appearance was lost, owing to almost complete disappearance of the fibrous stroma, the growth bearing in its external characteristics the strongest resemblance to ordinary jelly. The loculi in size were widely variable, and this variation was considerably extended when viewed microscopically.

By the latter investigation the naked eye alveoli (in the firmer portions of the growth) were seen to be subdivided into much smaller spaces by a delicate fibrous (or in other places membranous) stromal tissue, which occupied the larger alveolar spaces. These contained the jelly-like material, which in many of the smaller spaces appeared perfectly homogeneous; in others, contained nuclei scattered in their substance, or arranged around the inner surface

of, and apparently connected with, the delicate stroma. Elsewhere in the growth these alveoli circumscribed the typical colloid corpuscles—globular masses—the centre of which formed by an aggregation of granules and cells (the outlines of the latter in most cases indistinct), and around which was arranged the gelatiniform substance, with a concentric laminar appearance, the concentric arrangement being rendered obvious by groups of cells or granules.

In those parts of the growth which resembled jelly the stroma was absent, the structure microscopically was composed of a homogeneous basis, which took the logwood staining feebly, having scattered throughout it, in groups or singly, cells, nuclei, or granules of varying sizes, having in places a striated arrangement, in others irregularly scattered throughout the ground substance.

January 15th, 1878.

---

7. *A case of fleshy polypus (round-celled sarcoma) involving the antrum, orbit, and nostril.*

By W. Spencer Watson.

Mr. E—, a solicitor, æt. 59, was brought to me by Mr. Evan Smith, of Nottingham, on November 8th, 1877. He was a short, stout, florid man, with no cachexia, but presenting a protruded left eyeball and a fluctuating swelling of the left cheek, with total obstruction of the left and partial obstruction of the right nostril. His hearing was defective on both sides, and he was almost absolutely deaf on the left.

The left eyeball was thrust upwards and outwards as well as forwards, the pupil being dilated and immovable, and vision being reduced to doubtful perception of light in this eye. The orbitar tissues were full and prominent around the protruded globe. Occupying the centre of the left cheek was a prominent semi-fluctuating swelling, best felt within the mouth, and evidently caused by an expansion of the anterior wall of the antrum.

In the left nostril a greyish ragged mass was seen not far from the orifice, which bled very readily when touched by the probe. A

constant flow of offensive sanious discharge escaped from this nostril. This obstruction of the left nostril had been noticed first six months ago. The cheek became swollen soon after, and the eyeball began to be protruded a few weeks before I saw him. He had been a great snuff-taker, and had enjoyed very good health until the commencement of the swelling in the nostril. The family history gave no indication of any hereditary disposition to cancer. He had been accustomed to athletic sports of various kinds, and had often had severe blows on his head, but did not recollect having been more especially injured about the nose or eye.

The right nostril was only partially obstructed by the displaced septum thrust over from the opposite side by the tumour.

Treatment.—November 8th, 1877. The fluctuating tumour was punctured within the mouth and above the alveolar ridge, and a quantity of glairy semi-fluid material of coffee-ground colour evacuated. On introducing my finger into the opening I could feel the ragged edges of the bony wall of the antrum, through which the accumulated fluid had forced its way by absorption.

A very slight improvement followed this operation, and on December 18th Mr. E— again came to London, his condition being very little altered. He now complained of occasional severe pain in the head, sometimes coming quite suddenly in the region of the ear (left), and causing him to start violently, as if stung or struck in the part. Nevertheless he sleeps well, and his aspect, apart from the hideous distortion of the features, is not unhealthy.

On December 20th, with the able assistance of Mr. Bellamy and Dr. Evan Smith, I made an exploratory incision into the antrum within the cheek, and passing my finger into the cavity found it completely filled with firm, fleshy masses, some of which I removed through the opening. I then laid open the left side of the nose along the line of the outer limit of the ala, continuing it upwards to the angle of the eye. Then clipping through the bones I laid open a cavity common to the nostril, antrum, and orbit, the normal septa between these cavities having been absorbed by the growing tumour now filling them. By means of gouge, scoop, and forceps, I cleared out this common cavity as far as possible, but I was aware that the outer limits of the growth were not reached, and that nothing short of complete excision of the upper jaw would enable me to get to that part of the disease lying in the spheno-maxillary fissure. The base of the growth was in the spheno-ethmoidal cells,

and was very broad, and possibly extended deep into the base of the skull. Under these circumstances, and having regard to the patient's age, I considered it unwise to proceed with the operation any further.

On January 17th, 1878, the growth had spread very much towards the roof of the mouth, and the antrum had become filled up again. With the hope, therefore, of clearing out the left nostril, I incised the soft palate, but found that the obstruction was caused by a growth within the thickness of the soft palate itself.

The patient has since returned home, and, notwithstanding the free use of antiseptics in the form of spray and douche, the disease made very rapid progress, and I received a letter from Dr. Evan Smith, telling me that he died on February 15th, but without any warning of his approaching end, except that he seemed to have a presentiment on the night before. The pain in his head and ear continued to be very prominent symptoms up to the last.

A section through one of the larger masses had a greyish-white surface with mottled streaks of a cream yellow, the cream-yellow portions presenting a much more opaque aspect than the intervening substance, which, in some parts, had a semi-transparent appearance. The consistence was that of brain in some parts and of liver in others; but it was, for the most part, easily broken down.

Under the microscope it was found to consist entirely of cells of the granulation-tissue type, with no intercellular tissue and no definite arrangement into lobes or alveoli. Here and there, however, the round cellular elements were surrounded by fibroid bands, giving the arrangement somewhat like that of glandular tissue, but with no true epithelial elements. *February 20th*, 1878.

---

8. *Melanotic sarcoma of the eyeball; secondary growths in the organs of the chest and belly, particularly in the liver.*

By J. Wickham Legg, M.D.

Jane D—, aged 39, was admitted into St. Bartholomew's Hospital, under the care of Dr. Church, on January 15th, 1878.

In July, 1876, she had been under the care of Mr. Vernon, and

her eye had been excised. On examination the globe was found to be soft, and on dividing it, the vitreous chamber was seen to be filled by a black hardish mass, which on section was yellow and soft in the centre. The new growth seemed connected with the sclerotic. The lens was quite opaque and soft. On examination with the microscope, after hardening in chromic acid, the tumour was found to be a melanotic sarcoma. For these notes I am indebted to Mr. Barton.

On her admission again into St. Bartholomew's, she said that she had intense pain in the belly, which had lasted for two or three months; and for the same time she had noticed her belly to be hard and swollen. A large nodular mass was found filling the belly, and reaching almost to the pubes, being continuous with the liver dulness above and stretching into the left hypochondrium. In the chest there was no impairment to percussion, but râles were heard on both sides, with prolonged expiration. There was no history of malignant disease in the family.

She was delirious during the few days that she was in the hospital. Death on January 19th.

Examination, forty-five hours after death.—Height, 5 feet 4 inches. Rigor mortis well marked. No jaundice; no œdema of legs. Belly much swollen, and a firm tumour with a thin edge fills the whole of upper part of belly. The breasts are shrivelled, but full of nodules, the size of filberts and smaller. The right eye has been cut out. There are a few small tumours in the skin near the breasts.

On opening the belly a large quantity of light brown-coloured fluid comes out. The omentum is folded up below the colon, but can be stretched out; it is then seen to be made up of thousands of small whitish tumours the size of hempseeds; there are some few larger, the size of a pigeon's egg, but the greater number are small. The liver is enormous; it fills nearly the whole of the belly, descending below the iliac crest on the right side and to the level of the iliac crest on the left. In the middle line the lower border is 8½ inches from the tip of the xiphoid cartilage; the veins in the suspensory ligament are greatly enlarged and very numerous; one of them is filled with an adherent clot, which in places is seen to be alternated with a white milky juice. Just below the left breast are small white tumours underneath the skin, from which, on section, comes out a milky fluid. The left breast is full of small, white, new growths; many are coloured brown, others very deeply so, almost

black. The new growths in the right breast are much smaller, about the size of pins' heads, but there are two or three the size of pigeons' eggs, highly pigmented, and one is breaking down apparently from the presence of blood.

Calvaria very thick; longitudinal sinus empty. Meninges of the brain watery; base and vessels natural. Brain natural throughout; sinuses at base natural. There is no recurrence of the disease in either orbit.

Tongue, tonsils, pharynx, larynx, and trachea natural.

The left pleura is free from adhesions, and holds two or three ounces of a bloody fluid. On the ribs, near the vertebræ, and on the narrow tongue of the upper lobe of the lung, are numerous new white growths, very vascular. The right pleura is free from adhesions, and holds but a table-spoonful of fluid; many new growths in the pleura, which are white. At the base of the lung is a flat growth, highly pigmented, the size of a sixpence.

The pericardium shows many new growths, both outside and inside; the surface covering the left ventricle shows these nodules most abundantly; there are but few on the right side. The inferior cava, on passing through the diaphragm, looks as if coming out of a funnel, the liver is raised so much on each side. One of the pericardial new growths is distinctly pedunculated. Water poured into the aorta and pulmonary artery does not run through into the ventricle. Within the right auricle, close to the foramen ovale and attached to the septum, is a pedunculated white tumour, the size of a marble. There is a smaller tumour also attached to the septum, sessile. There are a few small tumours in the wall of the right ventricle, close to the attachment of the tricuspid valve, at the apex of the ventricle and in the conus arteriosus. There is none in the left auricle; there are but few in the left ventricle, and these not bigger than pins' heads, and pigmented. The valves are natural. The muscular tissue is flabby and mottled; under the microscope a scraping of the fresh tissue shows abundance of granules and small fat drops in the fibres. Weight 9¼ ounces, or 266 grammes.

The right lung holds a few tumours, some white, some pigmented, none larger than a hazel-nut. The same in the left lung. In both lungs the tumours are more abundant at the bases. The lower lobes are œdematous and fuller of blood than the upper lobes.

Spleen small, pulpy, of a dark brown colour. Malpighian bodies not visible. Weight 5½ ounces, or 155 grammes.

Intestines on mucous surface quite natural. The bowels show, where the mesentery is attached, innumerable new growths, the size of split peas.

Between the right lobe of the liver and the diaphragm is a thin extravasation of blood, covering a spot the size of half-a-crown. The bile-ducts are stained with bile, and the portal vein quite natural. Immediately after being taken out of the body, and without being cut into, the liver weighs 21 lbs. 8 oz., or 10·2 kilogrammes. The gall bladder lies in a trench of its own, is empty, but stained with bile. The liver is enormously enlarged in all directions, but preserves its shape roughly. The surface is not granular or rough, but there are large smooth projections, two or three as large as goose eggs. On cutting the liver vertically in slices, beginning with the right border of the right lobe, the lower part shows the most natural appearance; it is pale, yellow, flabby, and looks as if the cells held fat. This more natural-looking part forms the lower part of all the right lobe, and is most sharply marked off from the layer of tissue above, and in a singular and capricious manner, depending on no vascular arrangement. The stratum above about fills the greater part of the rest of the right lobe. It is firm, mottled green, and shows a network of broad bands of green tissue, in the meshes of which brown spots are seen. In the midst of this stratum is a rounded mass, greener, raised above the cut surface, and formed of new growths arranged in circles with a vessel in the centre. There are about six of these together, each about the size of a florin. Towards the left lobe these new growths show a dark green ground, in which white growths, the size of barleycorns, are strewn. Where the liver is thickest there is a large new growth, the size of a child's head or bigger, quite at the back of the right lobe; this tumour is coarsely granular, less pigmented, colour of a grey green. The left lobe shows altogether different characters. It is almost uniform in colour, a very dark brown green, very tough, no natural structure visible, and through it are scattered two or three large tumours, the size of hens' eggs—some smaller. Some of these are firm, others are soft.

Stomach much dilated; there is a small new growth in mucous membrane, size of split peas, and white. The pylorus is free, the pancreas natural. The prævertebral glands are large and filled with large white soft material. Suprarenal capsules natural. The vena cava is free from clots.

Both kidneys together weigh 13 ounces, or 365 grammes. The capsules, being torn off, leave a smooth pale surface, which are studded with about a dozen white nodules the size of hempseed. The right kidney shows two pigmented tumours. These new growths are seen on section in the medulla. Cortex is pale, indistinct. Medulla pink.

Bladder natural. Uterus shows a new growth in the fore wall, the size of a pea. Numerous new growths on peritoneal surface. Both ovaries are the size of walnuts, and are formed of four or five new growths, without fluid contents.

Aorta tolerably free from atheroma.

The contents of both orbits were carefully examined by Mr. Walter Griffiths. There was no return of the new growth in the right orbit, nor any disease of the left eyeball to be detected with the microscope.

Parts of all the organs found to contain new growths were hardened in chronic acid. The pigmented growths showed the same histological characters; to wit, those of a spindle-celled sarcoma. The white growths all showed the appearances of a round-celled sarcoma. This rule prevailed in all the specimens that were examined, and there were no mixed forms between the two. In some measurements which were taken of the spindle-cells from growths in the kidney, the length varied from 0·03 to 0·015 of a millimeter, and their breadth from 0·009 to 0·003 of a millimeter. When the pigment allowed the nucleus to be seen, it was a large oval one in the central part of the cell.

The cells from the colourless tumours were rounded or inclined to be somewhat oval in shape, with a large prominent nucleus filling up about half of the cells. From measurements taken from a colourless growth in the liver their diameters were about 0·021 millimeter.

Sections from that part of the liver which still showed to the naked eye the appearance of an ordinary fatty liver, that is, the under part of the right lobe of the liver, were seen under the microscope to have the following characters:—The hepatic cells are still arranged in rows; they appear to be slightly altered in shape and somewhat more rounded than polygonal; they contain a nucleus, well shaped, but in many obscured by the granular contents of the cell; no large fat drops are to be seen; the borders of the cells are in many cases indistinct. Scattered sparsely through the tissue are

highly pigmented cells, slightly smaller than the hepatic, and rounded. Some of these pigmented cells are spindle-shaped and caudate. The cells vary in abundance in different parts of this stratum. There appears to be here no increase of connective tissue. In the rest of the liver, that is, the greater part of the right lobe and the whole of the left lobe, no natural liver structure could be made out, nor could a single natural liver cell be seen in all the sections made; and these were taken from the most diverse parts of the organ.

The colourless tumours, even in the midst of the highly pigmented liver tissue, showed the same structure as the colourless tumours in the rest of the body, that is, a round-celled sarcoma. They showed no transition from the one kind to the other. In passing from the pigmented tumour to the colourless, the cells lost their pigment as soon as they became round, and no mixed forms were seen between the two at the line of contact; but there was a sharp line of separation between. *February 19th*, 1878.

---

9. *A case of carcinoma of the orbit recurring fourteen years after its second removal.*

By E. Nettleship.

The first part of this case was recorded just twenty years ago by the late Mr. Zachariah Laurence, and I take the following facts from one of the three publications in which it is to be found.[1]

The case is headed "Encysted encephaloid of the orbit." The patient, Elizabeth P—,[2] æt. 28, was admitted under Mr. Laurence's care in January, 1858, on account of a smooth, lobulated tumour, apparently about the size of a bean, beneath and expanding the upper lid of the right eye. The eyeball was pushed forwards and downwards, and its mobility somewhat impaired, but it did not

[1] 'The Ophthalmic Review,' vol. ii, p. 381. 1866. The case is also published in two other places: 'The Diagnosis of Surgical Cancer,' by Zachariah Laurence, 2nd Edition, p. 55; 'Medical Times and Gazette,' 1858, i, p. 449 (May 1st).

[2] Mr. Laurence does not give the woman's surname in full. But the Christian name and the initial of the surname are the same as in my patient. This fact and the internal evidence of the case remove all doubt that my patient is the person referred to in Mr. Laurence's record.

appear to be enlarged. The protrusion had been noticed for more than a year; the sight of the eye had been failing for six weeks, and with it she could only see very large objects; excepting congestion of retinal vessels there were no ophthalmoscopic changes. No tumours in other parts of the body. At the operation the tumour was reached by an incision through the upper lid, and then found to extend almost to the apex of the orbit. It weighed, after removal, more than half an ounce. It was lobulated, and "enclosed in a firm cyst of cellular tissue." Mr. Laurence describes the tumour very briefly as looking like encephaloid cancer, and as "unequivocally cancerous" in microscopical character; it showed no pigmentation.

Five years later (February, 1863) Mr. Laurence noted, "tumour not recurred; globe somewhat prominent. . . . Some small, hard, movable tumours under the skin of the eyelid;" he does not mention any operation at this date, but the patient tells me that at about the time above referred to he performed a second and slight operation, removing "some little tumours," which she states were present. About two months after this operation Mr. Laurence again examined her in company with another surgeon, and it appears to have been decided that no further interference was needed. She did not see Mr. Laurence again.

The patient had (as she told me) no further trouble till a few months before I saw her, when, after fourteen years' interval, she again began to feel something at the seat of the original tumour. Severe aching and burning pain came on, and it was chiefly the loss of rest caused by this that brought her to the South London Ophthalmic Hospital on July 23rd, 1877.

My notes at this date were substantially as follows:[1]—Elizabeth P—, æt. 48, married. The right upper eyelid droops over the eye. There are three or four small movable tumours, about as large as peas, under the skin of the lids, near the outer and lower parts of the border of the orbit; the skin over them is freely movable. A firm growth, with ill-defined borders, is felt adherent by a wide base at the outer angle of the orbit, and apparently extending back along its outer wall. Movements of the eyeball much limited every way, and almost entirely lost in the outward and upward direction; it is displaced slightly forwards, downwards, and outwards. There is a supple, linear scar in the outer two thirds of the skin of the

[1] I had not at this time seen Mr. Laurence's account,

upper lid. No enlarged glands. Eyeball slightly reddened; vision only shadows; pupil small and inactive, after atropine it remains circular, but not fully dilated; some superficial haze of cornea obscuring the fundus; optic disc pale but apparently not capped, a large patch of dark pigment close to it at the (real) outer, upper part, perhaps the result of a former hæmorrhage. No history of injury or other exciting cause preceding either the original growth or the recurrences.

She gave an account of Mr. Laurence's operations, and of the state of her eye, at her second visit to him several years later, which left no doubt that she was the woman referred to in Mr. Laurence's account above quoted. No family history of tumours.

A few days later I excised the eyeball and removed almost the whole contents of the orbit. The globe was firmly fixed, some of the muscles being, as afterwards found, matted to that part of the growth which adhered to the orbital wall. Nearly all the periosteum was peeled off, particular pains being bestowed on the marginal part of the orbit, where the membrane is naturally thickest and most adherent, and where it was in parts infiltrated with new growth. The bleeding from the apex of the orbit was stopped by perchloride of iron. On the fourth day afterwards chloride of zinc paste was applied on pieces of lint to the whole of the orbit, and on the temporal side, where the growth had been most firmly adherent, it was applied to the soft tissues and bone just outside the cavity.

She has gone on well. A good deal of the upper lid and skin covering the outer angle of the orbit and some of the lower lid sloughed, and several large scales of bone have exfoliated. The cavity has been filled up and very much contracted by the formation and organization of granulations. When I saw her a month ago (April) there was no sign of local return nor of visceral disease.

The parts removed consisted of—

(1) A considerable mass, nearly in the position of the lachrymal gland. It was very firmly adherent to the outer wall of the orbit, and particularly to its edge, from which part distinct spicules of bone projected into the tumour. The part of the external rectus muscle, which lay between the growth and the eyeball, was infiltrated and discoloured. The growth posteriorly was well-defined, sub-lobulated, and covered by fascia. On section, septa of fibrous-looking tissue, radiating chiefly from the periosteal attachment, divided the tumour into lobules, several of which were cheesy and friable, but the majo-

rity greyish and slightly translucent. The cut surface of the lobules became convex, the septa remaining flat or relatively concave.

(2) A large, rather flatter mass, resting on the lower and inner part of the orbital floor, and, like the former, firmly fixed to the corresponding part of the orbital rim, and invaded by a few spicules or granules of bone. The inferior rectus and inferior oblique muscles were lost in this mass. Excepting at the front part, it was well-defined, covered by an easily separable fascia or capsule, and somewhat lobulated. It was softer and more easily broken up than the former, and contained a cyst full of dark mucous fluid.

The periosteum uniting these two masses was thickened, and probably infiltrated.

(3) A much smaller mass behind the last, of similar appearance, and containing one or more cysts.

(4) A small, pea-like mass, attached to one of the orbital nerves far back. The nerve ran along one side of the little growth, and was not expanded upon it.

(5) Two small round tumours removed from beneath the skin, and which were felt to be freely movable before operation (see above). They were rather soft, and each was enclosed in a tough capsule.

All the tumours were well-bounded posteriorly, and all were external to Tenon's capsule. The two largest adhered very firmly to the front part of the wall and corresponding part of the rim of the orbit. The deeper tissues of the orbit were somewhat thickened.

The tumours all showed the characters of carcinoma, but the proportion of the cells to the stroma, as well as the size and definiteness of the alveoli varied much in the several specimens. Many sections closely resembled a scirrhus of the breast (see figs. 1 and 2, Plate VI). In some parts, particularly in the softer of the two large masses, there was a suggestion of glandular structure in the arrangement of the morbid growth. In this softer growth, and also in the small encapsuled tumours, the amount of fibrous stroma was much smaller than in the firmer principal tumour, and the cells were on the whole rather smaller.

Fatty, pigment-granular, and mucous degeneration was going on in different degrees in the several growths, and the formation of minute and of larger cysts was easily traceable in several places (fig. 4).

The small encapsuled growths were surrounded by a dense though thin capsule of well-formed fibrous tissue, and their alveoli were very small. One of the subcutaneous ones (No. 5) contained a

moderate number of small blood-vessels, and showed some large patches of degenerated blood, and at one part, just beneath the capsule, commencing cystic degeneration. The other two (Nos. 3 and 4), which were deeply seated, contained scarcely a blood-vessel; one of them was undergoing central mucous and cystic degeneration; the other, attached to a nerve, showed no such change, but a large amount of granular pigmentary degeneration of its cell elements.

In some parts of the large growths there was well-marked small cell infiltration, but in the majority of specimens this was not a marked feature.

Although the general characters of the tumours in this case are clearly those of epithelial cancer, the appearances in the firmest parts being often exactly like those in hard cancer of the breast, yet the definite limitation of the growths in some parts, and the tendency to formation of a fibrous capsule, perhaps point to some alliance with simple glandular tumour.

Although carcinoma is by no means common in the orbit, the chief interest of the case appears to me to lie in the length of the interval between the recurrences; unless, indeed (as has been suggested to me), the case is to be regarded as an instance of cancer, originating in scar-tissue, and as standing in no relation to the original tumour; and in this respect the brevity of Mr. Laurence's description is most unfortunate. It is probable, though unproved, that the original tumour began in the lachrymal gland, since this organ was not found in my operation; and it may be mentioned that the cells in almost all the parts removed were larger than those of the healthy adult human lachrymal gland. *May* 21*st*, 1878.

---

10. *Sequel to a case of sarcoma of the anterior part of the sclerotic; death from recurrent tumours nearly four years after excision of the eye.* (See vol. xxvii, p. 227.)

By E. Nettleship.

In July, 1876, the patient was found to have some firm enlargement of the thyroid body; he had it painted with iodine at a Throat hospital.

I saw him again some months later, and found the thyroid a little larger. Soon after this his health began to fail, and he became so weak that in March, 1877, he had to leave off work. In the summer he was under care for abdominal symptoms in a hospital, and fæcal accumulation appears to have been suspected at first. On leaving the hospital he was treated at home by Dr. Ffrench Blake until his death in May, 1878.

On December 11th, 1877, I saw him, and found the thyroid considerably larger than it had been, especially on the right side; it was firm and nodulated. In the lower part of the epigastrium, and passing over to the left side, was a large hard tumour, feeling smooth, deeply-seated, and not well limited; the skin was freely movable over it; it had been present some months. Below the lower angle of the left scapula a prominent, firm, nodulated growth, as large as a small orange, quite movable over the deep parts, and unattached to the skin; he had known of it for two months. There was also a hard oval lump as big as a walnut in the right groin of two months' duration. The orbit was now, and had always been since the operation, perfectly healthy, and there were at no time any enlarged lymphatic glands. He was very weak and emaciated, and suffered much both from difficulty in swallowing and from vomiting. I saw him once more in March but noted nothing of importance. He died of exhaustion in May. No *post-mortem*, not even permission to cut into one of the tumours, could be obtained.

In this case a small tumour on the outer surface of the sclerotic in the ciliary region, uncomplicated with the slightest trace of infiltration in any of the tissues surrounding the eyeball, and treated by removal of the globe and of that part of the conjunctiva which covered the tumour, was followed after a considerable interval by multiple tumours in distant parts. It is perhaps open to question whether the firm, nodular, infiltrated enlargement of the thyroid body, which was the growth next in order of time to the ocular tumour, was secondary to it, or was an independent growth; and it is, therefore, on this view uncertain whether the other tumours posterior in date to that of the thyroid were derived from it or from the eye. In future cases of this kind it would, I think, be well to act on the belief that even a very small and comparatively early growth may have already infected the orbit to a slight

though imperceptible degree, and to apply chloride of zinc freely.

May 21*st*, 1878.

---

11. *Case of epithelioma of the lip in a woman.*

By George Thin, M.D.

(Introduced by the President.)

E. R—, widow, æt. 65, was admitted into the Edinburgh Royal Infirmary, on January 2nd, 1878. The report of the surgical clerk states that "the patient had smoked a pipe for twenty-eight years. About nine months before her admission she got a new clay-pipe, which burned her lip at the right angle, raising a blister. She then exchanged the pipe for an old short *cuttie*, which she smoked for two months longer, till the lip became so painful that she gave up smoking. The lip, however, did not get well, and after some delay she came to Edinburgh for treatment."

On admission the lip at the right angle of the mouth had the appearance of an ulcer, with a hard, dry base, and the disease extended downwards and outward about an inch and a half. Mr. Bell removed the tumour and forwarded it to me.

An examination of sections through the growth showed that the epithelium of the part of the mucous membrane next the skin was the seat of changes characteristic of epithelioma. There were growths downwards of epithelium into the subjacent connective tissue. These epithelial prolongations did not penetrate to a great depth, the new growth of epithelium having to a large extent undergone a horny change, numerous "laminated capsules" being scattered through them.

A special feature of the case was the condition of the mucous glands of the lip. The ducts of some of these glands had become much dilated, forming veritable cystic cavities, from two to four times the diameter of the sections of the gland tubules near them. The cells of the columnar epithelium lining these cavities were regular, and there was a well-marked layer of sub-columnar cells on the basement membrane. The cavities contained amorphous matter, partly granular and partly homogeneous.

In the skin near the mucous membrane the hair follicles were much distended with sebaceous matter. A cavity had formed between the shaft of the hair and the internal root sheath, in which sebum had accumulated, until in extreme instances the diameter of the shaft was only a fifth or sixth of that of the cavity surrounding it.

The sebaceous glands had developed to an unusual size and form, extending between the bundles of the lower stratum of the cutis in a cylindrical form. No signs of morbid change were detected in the cells of the glands. The rete mucosum adjacent to the distended hair follicles was unchanged.

I have considered the case worthy of being reported on account of the sex of the patient, and on account of the condition of the glands of the lip and of the sebaceous glands. Perl, in his 'Lehrbuch der Allgemeinen Pathologie,' quotes from Warren that with seventy-three cases of cancer of the lip in men there were associated four cases in women, and that three of the women smoked.

May 7th, 1878.

---

12. *Cancerous ulcer of forty-three years' duration.*

By George Thin, M.D.

The following history of the case, dated February 12th, 1878, has been furnished by Mr. Edward May, M.R.C.S., of 86, Pentonville Road, N.

"Mrs. A—, æt. 68, has always enjoyed good general health. Her paternal grandmother died of cancer of the breast. She is one of a family of eight children, none of whom are known to have had cancer. About forty-three years ago, being then twenty-five years of age, she first noticed a pimple or wart, not bigger than a pin's head, over about the middle of the spine of the left scapula. Her dress chafed it, but nothing was done for it for about five years, when it had grown to the size of a pea. It was then pronounced to be a common wart, and removed by ligature. It soon reappeared, and in ten more years had attained the size of a moderate strawberry. It was again removed by ligature (this time being diagnosed as 'a vascular wart'). The base did not heal, but in spite of the

free use of caustic spread as a superficial ulcer. The ulcer gradually and steadily increased in size for the next twenty-seven years, giving little or no pain, but discharging freely and occasionally bleeding slightly, especially at each catamenial period, when it usually became somewhat turgid in appearance. The rate of progress throughout its course is described as being tolerably uniform until the last year, when it first came under my observation, and during that time the pain has materially increased together with the rate of progress. These two considerations, together with the fact that her health was beginning to suffer, induced her to submit to the removal of the ulcer by excision, which was done by Sir James Paget, on January 21st, 1878. The ulcer at this time covered the whole of the scapula from top to bottom, and from side to side.

"The patient has not, nor ever has had, any glandular or other swellings or ulcers of any kind. She married a few years after the first discovery of the 'wart,' and had two children, both of whom are now in good health."

I am indebted to Sir James Paget for the opportunity of examining the ulcer. The portion given me consisted of a central smooth red surface, a raised border covered with epidermis, and externally normal skin. The incision had been carried through the subcutaneous fat.

The thickened skin immediately external to the border of the sore presented a peculiar appearance. The epidermis was raised considerably above the level both of the margin of the ulcer and of the surrounding skin, a "ridge," more or less pronounced, encircling the edge of the sore. At some parts this ridge bulged out laterally, so that a sulcus was formed between the projection and the skin; at others the ridge was undermined on both sides, remaining attached to the skin by a narrow pedicle.

A section extending through the whole thickness of the skin, from the healthy tissue to the surface of the ulcer (see Plate VII, fig. 1), shows that the ridge is produced by an exuberant growth of epithelial cells, arranged in well defined groups. Groups of similar cells are found in the tissue of the cutis, immediately under the ridge, and in the upper strata of the ulcer adjacent to the margin. Neither under the ridge nor in the ulcer are they found in the deeper strata of the cutis, nor do they extend outwards towards the healthy skin much beyond the line of the sulcus formed by the outer edge of the ridge and the skin.

DESCRIPTION OF PLATE VII.

The figures in this Plate illustrate Dr. George Thin's case of Cancerous Ulcer of forty-three years' duration. (Page 237.)

FIG. 1. Vertical section through the margin of the ulcer.

a. Surface of the ulcer. *b*. Healthy skin external to the "ridge." The dark objects in the figure represent the cell-groups as seen slightly magnified. The ridge *d* is divided through the centre by a septum of epidermis. At *c* the connective tissue is healthy, no cell growth being found at this depth. (× 6.)

FIG. 2. Shows parts of two large cylindrical cell-groups with the connective tissue between them. (× 400.)

FIG. 3. A group of cells extending between the bundles of connective tissue in the middle strata of the cutis.

a. Elastic fibres (made prominent objects by eosin staining). (× 400.)

FIG. 4. Part of a sweat-coil greatly distended and filled with a homogeneous substance. (× 400.)

FIG. 5. Sections through sweat-coil. The lumen of the tube is filled with cells. At *a* a section through a normal sweat-tube (part of the same coil) is drawn for the sake of comparison. (× 400.)

Fig. 4.

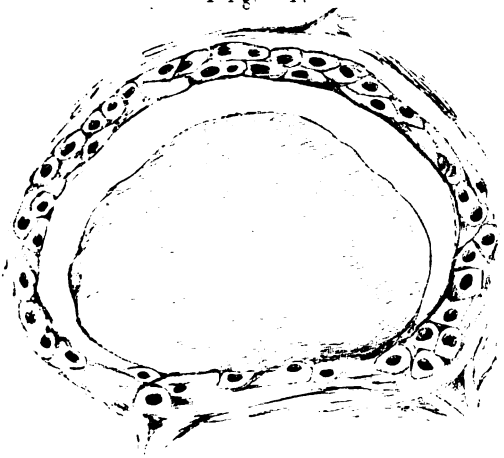

Fig. 3.

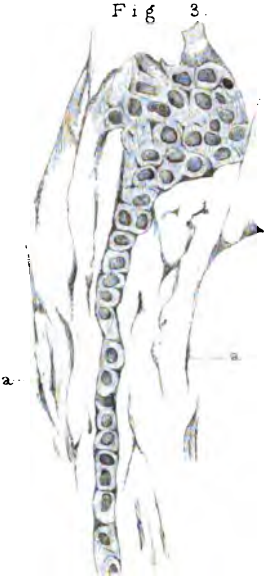

Fig. 5.



Fig. 1.

Fig. 2.

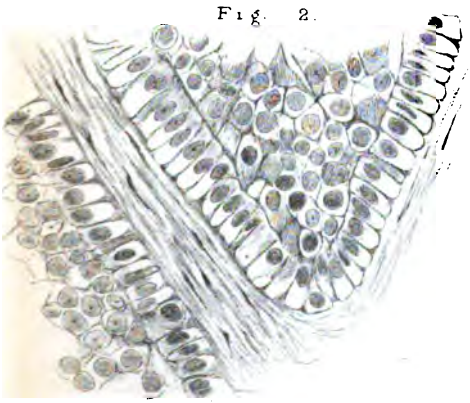

R. Maxson lith.

The forms assumed by these groups can be classified as belonging to one of two kinds. The ridge is composed of groups, which uniformly tend to assume a cylindrical character, and they are, therefore, seen in section to be cylindrical, pyriform, ovoid, or circular. From the cylindrical mass thus formed similarly shaped buds are thrown out, the connective tissue between them becomes more and more encroached upon, until finally adjacent groups join and form large cylindrical masses. When the masses have acquired a certain size they begin to break down in the centre, by a formation of small cavities, the largest of them being literally honeycombed. At the same time the connective tissue between these masses and the rete mucosum becomes thinner and thinner, until the new epithelial growth and the lowermost stratum of the rete cells are in contact, and the vascular supply is thus completely cut off.

Many of the cells of the rete mucosum over the most projecting of these cylindrical columns show the usual appearances of nuclear degeneration. In some the nucleus has disappeared, leaving a vacuole in its place; in others a crescent-shaped remnant still stains with logwood. In others, again, a small round nucleus, staining deeply in logwood, or two, more rarely three, still smaller nuclear bodies, also staining deeply, are found in the cavity left by the destruction of the old nucleus. Similar small nuclear bodies are found between the cylindrical cells which form the lower boundary of the rete, and in spaces between cells which are more or less broken down. Where the cell masses of the new growth are in contact with the rete the numbers of these small nuclei are greater, and towards the border of the ulcer, as the rete becomes more broken down, the number of these small cellular elements increases. Finally, the epidermis proper is for a short distance represented by the horny layer alone, until at last the exposed surface of the ulcer is reached.

The other form assumed by the cell-groups is in marked contrast with that just described. Whereas in the superficial parts of the cutis the connective tissue yields to the growing masses, in the central stratum the resistance is so great that the direction of the new growth is everywhere determined by the arrangement of the bundles of connective tissue. The new cells are found in clusters of indefinite shape, situated in spaces formed by separation of the bundles, and the groups grow by the cells extending, at

first in single file, between the bundles (see fig. 3). They do not penetrate to the deeper layers, where the bundles are thick and strong, and the elastic fibres very large.

The external or bounding cells of the cylindrical groups have a columnar form (see fig. 2). The other cells of these groups, and all those in the cutis tissue, are composed of a spherical nucleus, which stains deeply with logwood, and a scant amount of yielding cell substance, which resisted badly the action of the ordinary hardening solutions. All the groups of cells were penetrated freely by elastic fibres, which passed straight through them unaltered. The connective tissue between the groups was well supplied with blood-vessels.

The sebaceous glands and hairs in the adjacent skin degenerated before they came in contact with the cell growth.

There was no growth either from them or from the epidermis. The small cell infiltration beyond the area of the ulcer and its immediate vicinity was very moderate.

The sweat glands were in the great majority of instances normal, but in several sections the following morbid appearances were found in these structures. The tube of the coil had in some parts become greatly dilated, the lumen being filled by a homogeneous structureless substance (see fig. 4). At other parts a dilated tube was found partly or completely filled by cells. In both cases the epithelium of the wall was complete, thus giving evidence of new cellular growth. The cells in the lumen of the tube were smaller than those of the cell growth (compare fig. 5 with figs. 2 and 3). The affected sweat glands were beyond the area of the growth, and in the sections examined no continuity was traced between the glands and the cell groups.

Sections through the central of the ulcer showed superficially an amorphous substance infiltrated with white blood-corpuscles, and more deeply the ordinary connective tissue of the cutis. In some sections fragments of cell groups were found near the surface, but in many no traces of them were seen.

In forming an opinion as to the nature of this ulcer, it is to be noted that the absence of growth from the epithelium of the rete mucosum, hairs and ducts of the sweat glands, distinguishes it from epithelioma. The cells also differed from those of epithelioma. They were of uniform size, never became horny; there were no prickle cells, and no formation of laminated capsules. The only

structures of the skin found diseased were the sweat glands. This fact, and the tendency of the new cells to from cylinders, with a columnar arrangement of the outermost layer of epithelium, point very strongly to the probability of the disease having in the first instance taken its departure in these glands. The term cancerous ulcer has been used in order to denote that the destruction of tissue was produced by an epithelial growth, and the term epithelioma has been avoided, in order to mark the distinction between this case and the cases of cancer of the skin so designated.

If the view that the new growth has the characters of the glandular epithelium of the sweat glands be accepted, then the case is most accurately described as one of adenoma of the sweat glands, and would thus fall in the same category with one of this nature described by Verneuil ('Archives Générales de Médecine,' 1854, vol. ii, p. 458), to which, in its histological characters, it bears a strong resemblance.

[The bearing of this case on the pathology of the "rodent" ulcer of English surgeons, of which I believe it to be a well-known example, is pointed out in the next paper. *May 7th*, 1878.

---

13. *Pathological histology of a case of rodent ulcer of the scalp.*

By George Thin, M.D.

I am indebted to Mr. Morrant Baker for the specimen and for the following history of the case.

"The patient, J. W—, æt. 60, first came under my care at St. Bartholomew's Hospital, in July 1873, with a circular or rather nummular ulcer of the scalp over the left parietal bone, of about 1¼ inch in diameter. The ulcer had a moist and red glazed surface, with sharply-cut edges. There was no induration of the base. The discharge was somewhat offensive, and the ulcer was painful.

"The patient gave the following history:—About three years before admission, a small pimple, like a mole, formed on the scalp, and remained, with scarcely any alteration, for a year. Then it broke and began to discharge—at first blood, and afterwards matter. Of late it had much increased in size.

"There was no history of syphilis, and no scars or sores were visible in any other part of the body.

"The ulcer was treated at first with nitric acid, and subsequently with Vienna paste, and with apparently much benefit. But before the ulcer was healed the patient was lost sight of, on account, as he afterwards told me, of his living in another part of town, and I did not see him again until the latter end of 1877, when he was brought to the Royal Medical and Chirurgical Society by Mr. Gaskoin. At this time the ulcer measured about 3 inches by 4 inches, still preserving the same characters that led me, four years ago, to call it 'rodent ulcer.'

"The patient has, at Mr. Gaskoin's suggestion, again applied for admission at St. Bartholomew's Hospital, and I have removed the whole of the ulcer with the knife. The large wound thus made is now healing well (June, 1878)."

This ulcer is identical in its nature with the one removed by Sir James Paget, and described in the previous paper. A detailed description of the microscopic appearances is therefore unnecessary. It differed in so far that there was no "ridge" external to the margin of the ulcerated surface, and consequently the large cylindrical masses of cells seen in section in the former case were absent in this one. The ulceration was produced, however, in the same way. Immediately under the border of the ulcer, and for a very small distance under the epidermis of the margin, clusters of cells separated the bundles of connective tissue, and grew most luxuriantly towards the surface. The clusters were largest in the upper strata of the cutis, and caused the progressive ulceration by obliterating the connective tissue and blood-vessels of the papillary layer.

A section through the centre of the ulcer showed it to be composed, as in Sir James Paget's case, of a substratum of unaltered connective tissue of the cutis covered by an amorphous substance containing blood-vessels and large numbers of colourless blood-cells. Sparsely scattered through this tissue were patches of the above-mentioned cell-clusters.

In the sections examined the only changes found in the rete mucosum, sebaceous glands and hairs were retrogressive, thus contrasting with what is found in epithelioma. Diseased sweat glands were not found.

The cells of the new growth were, as in the previous case, characterised by a spherical nucleus of uniform size, staining deeply in logwood, and scant, ill-defined cell substance. The columnar form of the external cells of the groups was in this instance less pro-

nounced. As before, a complete absence of laminated capsules and horny or prickle cells in the morbid growth.

The results of the examination of this ulcer, which has been diagnosed as a rodent ulcer, and of Sir James Paget's case, which combines the chief features which are considered by English surgeons as characteristic of rodent ulcer, show that in some at least of the cases distinguished by this name we have to do with a special pathological condition, and that this condition has no near relation to epithelioma. The resemblance of Sir James Paget's case to the ulcer described by Verneuil, in which the departure of morbid action was definitely traced to the sweat glands, and the evidences of a tendency to new cell formation in the sweat glands observed by me in the former one, further point to the strong probability that the rodent ulcer of English surgeons and the adenoma of the sweat glands of the French surgeon, are one and the same disease.

May 7th, 1878.

---

14. *Primary cancer of the tonsil.*

By Lennox Browne.

Charles F—, æt. 53, a carpet beater and layer, first came under observation at the Central London Throat and Ear Hospital on September 17th, 1877, complaining of throat trouble, and giving the following history:

Had long been subject to catarrhal attacks in the throat, during one of which four years previously the voice had been temporarily lost. Had never suffered from any injury to the throat, nor had the tonsils ever been subjected to operation. With the exception of a gouty tendency, his family history was good, there being no evidence of any relative having suffered from a tumour, simple or malignant.

The present affection was considered to have commenced in the preceding May, when he first experienced a soreness of the throat, which had continuously increased, and had been followed a month later by difficulty in swallowing. These symptoms had recently been much aggravated. The pain was contant; was of a lancinating character, and extended from the fauces to the ears. The dysphagia had been succeeded by difficulty in nasal respiration, especially

through the right nostril, from which there was a constant viscid and fœtid discharge.

Eight weeks previously the glands on the right side of the jaw had become swollen and painful. He was conscious of having lost flesh for some months.

On examining the interior of the mouth the mucous membrane of the whole of the soft and hard palate on the right side was seen to be uniformly and intensely congested. The right tonsil was considerably enlarged, but no fluctuation was to be discovered at any point. The soft palate and uvula were pushed towards the left side. Behind the right posterior faucial arch and apparently continuous with the enlarged right tonsil, projected an irregular fleshy mass, reaching nearly to the middle line, extending below the level of the tongue, and obscuring the view of the pharynx; it was of a deep red colour, firm in consistence, and when first seen was free from ulceration. There were no fungating masses, and there was no tendency to hæmorrhage.

WOODCUT 8.

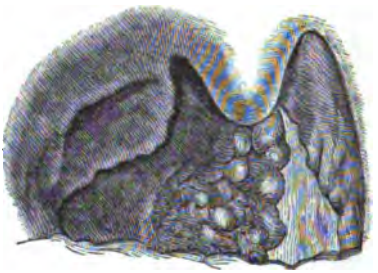

Externally there was a well-defined lobulated and firm swelling behind the ascending ramus of the lower jaw, extending posteriorly as far as a line at fall from the back of the ear, and below as far as the level of the jaw. The skin was freely movable over the swelling, and was somewhat congested. The whole mass appeared movable on the subjacent parts. The sterno-cleido-mastoid muscle was highly projected at the upper attachment. There was no pulsation, inherent or transmitted. The glands in the neighbourhood of the parotid were not enlarged, and no pain was caused by movement of the jaw. Weight of the patient at first visit was 12 stones.

On October 12th, a month after his first application, the patient's condition was reported as having steadily deteriorated; his expres-

sion was worn, and his countenance was very anæmic, though he had lost no blood from the mouth, nor had he suffered from any other hæmorrhage. He suffered great pain in swallowing, and at other times, so that he was quite unable to masticate; his breathing also was more obstructed. The growth had become more prominent in the fauces; there was much saliva secreted, and there was very marked and characteristic fœtor of the breath. An irritative cough gave him much trouble, and his rest was greatly disturbed thereby. His weight had decreased 4 lbs.

A piece of the growth was removed by means of the galvano-cautery loop with but little pain, and with very trifling hæmorrhage. The piece removed weighed about 3 drachms, was of a greyish-yellow colour, mottled, with purplish spots. At one point it showed commencing ulceration. The mass was slightly lobulated, and was freely supplied with blood-vessels. The central part was of dark apple-jelly colour, semi-transparent, and elastic in consistence. Microscopic examination confirmed the diagnosis as to the malignancy of the growth, which was thought to be encephaloid in character.

Twelve days later (October 24th) the patient expressed himself as much relieved; swallowing was attended with less pain, and breathing was easier. His weight showed a decrease of 2½ lbs. since the last date.

On November 1st another piece of the growth was removed, having much the same character, but more ulcerated. The operation was again followed by considerable relief. Deglutition was easier, the lancinating pains were seldom experienced, but the patient complained of a dull heavy pain over the right ear and side of the head.

He visited the hospital on December 23rd, walking both to and from his house, the distance of both journeys being fully two miles. His weight was 10 st. 2 lbs., showing a decrease of 26 lbs. in ninety-eight days. He had lost 7 lbs. in the last fourteen days.

On the evening of the 24th (that is, on the day after his last visit to the hospital) a sudden attack of hæmorrhage took place, and death was reported as having ensued in less than a minute.

Autopsy made sixty-three hours after death by Mr. G. R. Steil.—The larynx and pharynx with the tongue and the cervical swelling were removed entire.

The cervical tumour was marked by a shallow groove running

downwards and outwards, and dividing it into a posterior upper and an anterior lower and larger part. Above the mass, lying in front of the internal jugular vein and against the pharyngeal wall, was seen the spinal accessory nerve, which, passing beneath the upper part of the tumour, emerged at the groove. The posterior division of the mass was firmly attached at the upper part of the base of the skull and the transverse processes of the upper two vertebræ; in front of it was the styloid process of the temporal bone. The anterior and larger division, ovoid in shape, was partly covered by the sterno-cleido-mastoid muscle. Above it lay the posterior belly of the digastric and the stylo-hyoid muscles; below it was free, whilst in front it merged into the thickened and infiltrated pharynx. The tumour was of a smooth, slightly lobulated surface, of a pinkish-yellow colour, and semi-elastic to sense of touch, giving the idea that it contained fluid. On section it was at first firm, but the centre part was softer. It was of a yellowish-grey colour mottled with pink. On pressure there was characteristic juicy exudation. There were a few smaller, enlarged, and indurated glands in the neighbourhood.

The common carotid artery, with the internal jugular vein and accompanying nerves, were pressed back and lay beneath the tumour; the external carotid was seen to emerge from behind it at its upper border. Anteriorly it was pierced by the superior laryngeal and the lingual arteries.

The whole of the soft palate and the upper walls of the pharynx were thickened and infiltrated. The tonsillar mass, which originally projected from behind the posterior arch of the palate, had become greatly reduced by sloughing, which had also attacked the right pharyngeal wall. Several vessels were seen to be dissected by the ulceration in the wall of the pharynx, but even on most careful examination no arterial branch, tonsillar or pharyngeal, was traceable from the facial to the ulcerating and sloughing parts; so that it was impossible to say exactly whence the hæmorrhage had proceeded. The larynx was healthy, and the tongue also was uninvaded. No other organs were permitted to be examined.

Remarks.—Primary cancer of the tonsil is exceedingly rare, and in my experience does not occur more often than about once in every 5000 cases of throat diseases. This is the sixth case I have seen, but the first in which an autopsy was obtainable. The

variety of cancer in this region has been generally considered to be that of scirrhus, or encephaloid. It is probable, from the result of the examination of this specimen by the Morbid Growth Committee and of those exhibited by Dr. Moxon ('Transactions,' vol. xx, p 369), and by others that primary malignant disease of the tonsil is most usually of the nature of a lympho-sarcoma. This view is confirmed by the account given by Mr. Butlin to the Society, on the occasion of exhibition of this specimen, of a case which he had seen in conjunction with Mr. Thomas Smith; and also by the clinical history of two cases which have occurred in my own practice.

It is worthy of remark how much relief was experienced by the patient after removal of some portions of the growth. The same benefit is always reported after slight hæmorrhages, so frequent in these cases, or when the mass which so much impedes deglutition and respiration commences to ulcerate.

Death appears to most often result from hæmorrhage; failing which, death from pneumonia or œdema of the larynx is the usual termination. *February 5th*, 1878.

Report of the Committee on Morbid Growths.—The parts forwarded to us consisted of a piece hardened in chromic acid, some pieces of diseased gland in glycerine, and the tongue, larynx, and adjacent parts in spirit.

The latter parts are the seat of a large soft growth which, springing from the right side in the neighbourhood of the tonsil, infiltrates and thickens, the posterior wall of the pharynx and the soft palate. The posterior walls of the pharynx and the tonsillar region show a ragged sloughy surface.

Under the microscope all these parts have a very similar structure. The stroma forms a delicate reticulum, enclosing small cells with single nucleus, and occasionally much larger cells also with single nucleus. In the tonsillar region the cells, though small, are decidedly angular; in the glandular mass outside it they are mostly circular. This difference in the shape of the cells appears to be a local accident, due rather to mutual compression than to any essentially different type of growth in the two parts, and we consider the disease to be a lymphosarcoma. The nature of the growth, and the absence of any tonsil structure, make it probable that the latter may have been the original seat of the disease.

JAMES F. GOODHART,
HENRY T. BUTLIN.

March, 1878.

15. *Epithelioma of tongue invading the tonsil; living specimen.* By LENNOX BROWNE.

JOHN SMITH, æt. 44, a painter, was brought to the Central London Throat and Ear Hospital in October, 1877, by Mr. Lloyd, of Bloomsbury, and was seen by my colleague, Dr. Llewelyn Thomas.

His history was that he was married and the father of eight children, of whom the eldest was nineteen years, and the youngest five months; all of them healthy. He had suffered from primary syphilis (followed by secondary rash and sore throat) twenty-four years previously, and fifteen years since had had a sore tongue, which speedily yielded to treatment. He had never suffered from painter's colic. He had been a free drinker of rum. His present trouble had existed eight months, and had commenced with difficulty in swallowing, thickness of speech, and pain with impaired mobility in the tongue. When first seen by Dr. Thomas there was induration and deep ulceration of the back of the tongue on the left side. There were also several enlarged and hardened glands under the jaw, but the tonsil and the palate generally were uninvaded. There was no doubt as to the malignancy of the disease, but iodide of potassium was ordered with a view to subduing any syphilitic element which might probably coexist; and certainly under this drug the patient did for a time improve, so much so that he declined to become an in-patient, and spoke of resuming work. He had, however, lost flesh and strength since his attendance. In November the left tonsil was observed to have become red and swollen;

WOODCUT 9.

a day or two later there were several points as of commencing ulceration on the tonsil, which on his next visit were seen to have broken down, and to have resulted in one large ulcer con-

tinuous with that in the tongue. It was about this time that I saw him, and with my experience of the relief afforded by means of galvano-caustic treatment, Dr. Thomas decided to pursue the same measure in this case. The procedure was attended with apparently an equally good result; at any rate it induced greatly to the patient's comfort in swallowing.

On December 10th the patient had an attack of hæmorrhage, and he was taken to the hospital nearest to his residence—St. Mary's—where he remained two weeks. He again came under Dr. Thomas's care at the Throat and Ear Hospital, and was admitted as an in-patient. He had become greatly emaciated, and all his symptoms were worse. Speech was quite unintelligible. It could be observed how the disease had advanced since the drawing was made, the tongue having considerably shrunk and become quite immovable, while the faucial ulceration had also greatly extended.

February 5th, 1878.

Three days after his appearance at the Society he had been attacked with another violent hæmorrhage, which was somewhat arrested, though slight sanguineous oozing continued to occur for some days whenever food was taken. The patient became very weak, and the sloughing considerably extended. Early on the morning of February 19th he had died, after a very short attack of suffocation, which awoke him from sleep.

No autopsy was allowed, but permission was given to remove as much of the diseased portions as could be taken through the mouth. This mass, which included the remains of the tongue, the soft palate, and a portion of the epiglottis, was submitted intact and fresh to the Committee on Morbid Growths.

Remarks.—While primary cancer of the tonsil is rare, cases of invasion of the gland from malignant disease in the immediate neighbourhood is still more uncommon, since, in cases of epitheliomatous ulceration of the pharynx and floor of the mouth, it is matter of remark that the tonsil usually escapes. This fact was well illustrated in the specimen showed to the Society by Dr. Goodhart ('Transactions,' vol. xxiv, page 90). No report of a case exactly similar to the present one has been found, but since exhibition of the specimen the author has seen another case of epithelial cancer of the tongue invading the tonsil in precisely the same manner.

February 19th, 1878.

Report of the Committee on Morbid Growths.—Only the epiglottis, soft palate, uvula, and tonsils reached us. The right tonsil is healthy, but the left is to a great extent defaced by a new growth, in the form of a ragged ulcer, which appears to extend from the base of the tongue.

Parts of the uvula, the soft palate at its base, and the right tonsil were hardened for examination. The uvula is healthy, but the muscular structures at the base of the tongue and tonsil show circumscribed masses of cells of epithelial type, with numerous cell nests, which pass between the individual fibre of the tissues.

We have no hesitation, therefore, in describing the disease as epithelioma, the original seat of which was probably the tongue.

JAMES F. GOODHART,
March, 1878. HENRY T. BUTLIN.

---

16. *Epithelioma of pharynx invading the larynx; living specimen.*

By LENNOX BROWNE.

THIS specimen and the next were shown in conjunction as illustrating the two most common varieties of cancer when attacking the larynx. In this case the disease was seen to commence on the right pharyngeal border of the larynx, and so to press on the right arytenoid cartilage, the action of which was somewhat paralysed, and against the cricoid. The disease had now extended right across the back wall of the larynx, concealing its posterior border and greatly diminishing the orifice of the gullet. Later, the cartilages would probably undergo carious degeneration.

WOODCUT 10.

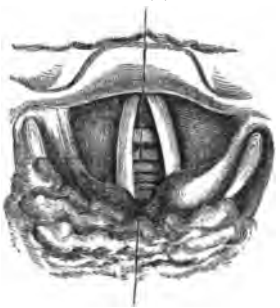

Appearance of larynx during full inspiration showing fixed position of right arytenoid cartilage and vocal cord.

The case well illustrated the clinical and physical characters of the disease. The patient was a female, æt. 62, who had suffered from difficulty of swallowing for eight months, followed by shortness of breath on very slight exertion, hoarseness, and pain extending to the ears. There was enlarge-

ment of the cervical glands on the right side, and the patient had steadily lost flesh and strength. *February 5th*, 1878.

---

17. *Encephaloid cancer of the larynx.*

By Lennox Browne.

The patient from whom this specimen was taken was a female, æt. 47, in whom the nature of the disease was diagnosed by means of the laryngoscope fifteen months before death. In this case the first symptoms were hoarseness, and later almost complete aphonia, then dyspnœa, both constant and with paroxysmal exacerbations, but dysphagia was never severe. Pain, extending to the ears, was an early and constant symptom.

Woodcut 11.

Woodcut 12.

The bright red colour and smooth lobulated character of the growth shown in the illustration, served to well differentiate the disease from epithelioma, which, when commencing within the larynx, is of a much paler colour and of warty appearance, while, as in the preceding case, when attacking the pharyngo-laryngeal boundary, it commences as an advancing infiltration and ulceration. In medullary cancer ulceration is a late manifestation. These laryngoscopic features are well illustrated in the two drawings (Woodcuts 11 and 12); the one taken on first seeing the patient, the second more than a year later, and shortly before death.

The patient was also under the care of Dr. Brown, of Kentish Town, and it was remarked at the autopsy that the body was even more than usually well nourished, as far as the presence of fat was concerned, though the tissues had the characteristic pale and bloodless appearance seen in the victims of malignant disease.

Microscopic examination gave clear evidence of the character of the growth. *February 5th*, 1878.

VIII. DISEASES OF THE SKIN.

1. *Bromide of potassium eruption in an infant.*

By H. Radcliffe Crocker, M.D.

Lydia D—, æt. 8 months, was sent to University College Hospital on December 22nd 1877, for the diagnosis of a peculiar eruption on the face and limbs, which, as usual, was laid to the charge of vaccination.

The child was vaccinated in the previous August, from the same lymph as thirteen other children who remained well; on the 12th day after vaccination a rash appeared all over the body, consisting of small red spots the size of a millet seed, raised above the surface with whitish watery heads. This rash died away, but fresh crops appeared lasting on and off about three weeks, and the skin remained clear from that time until the appearance of the present eruption, which came out in the beginning of December. The child, however, was never quite well, and had convulsions on the 12th November, which continued at intervals until the 19th. For this one grain of bromide of potassium was prescribed three times a day; on the 16th the same dose was given every four hours, and on the 19th ¼ grain iodide of potassium was given with each dose of bromide up to the 24th, when the iodide was omitted, but the bromide continued in two-grain doses three times a day up to December 13th. The eruption came out in the beginning of December, appearing first on the site of vaccination, looking, the medical attendant said, like a vaccine vesicle of the tenth day, in the pustular condition (see Plate VIII); patches next appeared on each cheek, and then on the buttocks and loins, in some parts, symmetrically distributed. When I first saw the case there was an irregular patch the size of a crown piece, with a raised, irregularly sulcated scab, with two small pustules on the border of the patch, but no inflammation round it. On the face the scabs had been rubbed off and the patches were discharging,

DESCRIPTION OF PLATE VIII.

This plate illustrates Dr. Radcliffe Crocker's case of Rash from Bromide of Potassium. (See text, page 252.)

but there were several pustules in the neighbourhood. On the buttock some of the patches showed a central scab with an oval raised, pale, fleshy looking rim of tissue surrounding it. On December 31st the eruption was much more copious; numerous fresh places had come out on the arms and face, but those on the body were dying away. The fresh appeared as pustules from a millet seed to a pea in size; there were also patches which possess some resemblance to a vaccine vesicle in the pustular condition, but closer examination showed that the patch was composed of an aggregation and coalescence of pustules, while the central scab was produced by rubbing. There was a pink areola of about ¼ inch in diameter round each pustule, which was situated on a slightly raised base. No bromine was detected in the urine.

This case closely resembles one by Dr. Lees published in 'Pathological Transactions' for 1877, and another case is well recorded by Dr. Cholmeley in the 'Clinical Society's Transactions' for 1870. Cases are also related by several foreign observers, Neumann, Voisin, and others; nevertheless, these cases are very rare when compared with the number who take bromide of potassium, and appears due to a special idiosyncrasy, so that even a very small dose will produce it in those susceptible. I quite agree with Drs. Cholmeley and Lees as to its nature—that it is made up of an aggregation of acue pustules. It begins as an inflammation of the follicle, but the process seems more acute than ordinary acue, and there is more cell infiltration and pus formation. The red papule, first formed, becomes soon an acuminate pustule on a soft, red, and raised base. Several of these become aggregated and may coalesce into an irregular patch of from ½ to 2 inches in diameter (see Plate VIII); but as long as there is pus present, the individual pustules are discernible. Subsequently thick tuberculated crusts are formed, much raised above the surface; but between this and the primary pustular stage the raised base on which the pustules were situated have the dry, fleshy appearance I have alluded to, looking as if due to a single lesion, though even here a solitary pustule may occasionally be seen independently of the patches.

These cases last two or three months after the cessation of the drug, and this one is interesting because most of it came out after the drug had been discontinued, it appeared first on the site of vaccination, while the dose of bromide was very small even for an infant.

January 4th, 1878.

2. *A case of "hypertrophic lupus," with an account of the histology of its various stages.*

By A. Sangster, M.B.

The following is a short history of the case :—The patient, A. C.—, æt. 24, was an engine-fitter by occupation; he was healthy-looking, and stated that he never ailed to any degree.

For fourteen years he had been troubled with a sore on the buttock, which had crusted and bled, so as to stain his linen. When he was about ten years old the place is said to have been no larger than a florin; it had gradually and steadily increased in size, in spite of treatment by medicine and "salves," and had caused more inconvenience than pain. The latter symptom, however, had been present at times during the last year or two, and was described as being piercing or knife-like. There was nothing of interest in his family history, excepting perhaps that a maternal aunt is said to have died consumptive.

When first seen, June 21st, 1877, there was, directly over the right tuberosity of the ischium, a raised nearly circular patch of diseased skin, measuring four inches across from side to side, and rather less from above downwards. Below, the disease extended almost to the fold of the buttock, which hung on a slightly lower level than its fellow on the opposite side. On the left, it was partly overlapped by the approximating buttock, but stopped short of the anus. The entire centre of the diseased area was hard to the touch, feeling like bacon-rind: the surface was polished, of a livid-white colour, and marbled with a superficial veal-like scarring. This hard centre was bounded by a margin, festooned in outline, averaging three-quarters of an inch to an inch wide, and made up of deep livid-red tubercles. Many of the latter had the semifluctuating feel of lupus-tubercles, while others were crusted with dried secretion, or covered with scales of exfoliating epidermis.

On the right the diseased patch gradually reached the level of the surrounding skin in an inclined plane, but on the left, where overlapped by the approximating buttock, the large exuberant tubercles rose abruptly from the sound surface, causing the disease in this situation to present quite the general appearance of condyloma. The skin was congested for a short distance beyond the diseased

patch. A Cast, and Photograph of the disease, *in situ* were taken. The case was diagnosed to be one of lupus, from the commencement, but in view of the bare possibility of its being specific, the patient was ordered iodide of potassium. This he took for some weeks without appreciable result. At length, the growth was freely excised by Mr. Hird. All the tissues of the integument were found to be infiltrated, the tumour being adherent to the fascia covering the gluteal muscles. The large exposed surface was allowed to granulate up, and the patient recovered without a bad symptom. As yet (about three months after the operation) there are no signs of "recurrence in the scar."

Before entering upon any detail as to microscopical appearances, it is necessary to state that material for examination was taken from different parts of the growth, viz.:

1. From the advancing edge.
2. From the abruptly elevated tubercular surface on the left (alluded to in the foregoing description).
3. From the hard cicatricial centre.[1]

The following description corresponds to appearances seen in sections cut from No. 1 specimen, the sections being cut in a plane more or less vertical to the surface, and in a direction towards the centre of the growth.

In examining that end of the section which was nearest to the sound skin, first of all, there may be noticed changes in the epidermal layers, which are peculiar to these structures when they cover a chronically inflamed papillary body. The cells composing the different layers do not pass through those conditions or attain that development which belongs to normal epidermis, and, as a consequence, the boundaries between the layers become ill-defined, and irregular; for instance, in the specimen before us, long, finger-like processes form the Malpighian layer dip down between the papillæ, following no order as to size or direction; the cells—at least those of the first tiers—are distorted, being for the most part much elongated, with their long axes following the direction of the papillæ. The regular palisade-like arrangement of the first tier is completely

[1] These specimens were cut from the growth as soon as it was removed, and placed in a solution of chromic acid and water (1-6th per cent. chromic acid) for three days, then gradually hardened off, first in methylated alcohol and water, equal parts; next in a mixture containing 75 per cent. alcohol; and finally in pure methylated alcohol.

lost in places, and the boundary line between the rete Malpighii and papillæ is ill-defined. There are a few vacuoles to be seen.

Towards the distal surface of this (Malpighian) layer the cells become pale and granular, the nuclei are indistinct, and there is an abrupt transition from these pale cells, probably representing the "Stratum Lucidum" to the next layer, the "Stratum Corneum." The cells composing the latter structure, instead of showing that fibrous appearance which is peculiar to the Stratum Corneum of normal epidermis, and due to extreme flattening, appear swollen and irregularly polygonal; flattening being seen only in places, where they have been submitted to pressure, *e. g.* in the choked-up, widely dilated mouths of hair-follicles.

Passing on to the other epidermal structures, there is the same irregularity to be observed in the hairs and their coverings.

The different root-sheaths are indistinguishable; and the outlines of the follicles, instead of being round, or oval, as seen in transverse or oblique section, take shapes more approaching the *trefoil* or *quatrefoil:* a result of unequal peripheral cell growth. The boundary line between the external root-sheath and the follicle is completely obscured in places by germinating cells. As yet, however, the hair belonging to the follicle is properly formed, but, in addition, lying amongst the cells of the external root-sheath, may often be seen yellow masses of imperfectly formed hair-substance. There is another peculiarity connected with the root-sheaths and follicles which may be mentioned.

Circular areas of cells occasionally appear in the thickened fibrous sheath of the hair follicle, sometimes accompanied by similar collections in the external root-sheath. When in the latter situation, the character and arrangement of the cells in these areas distinguish them readily from the surrounding cells amongst which they lie. These appearances have been described[1] as due to hornification of the cells of the external root-sheath. Processes of these imperfectly hornified cells are said to extend beyond the root-sheath into the surrounding fibrous tissue. The whole is said to be a result of abortive hair-formation.

The change, or rather the absence of change, in the sebaceous glands is interesting, because the essential nature of lupus has

[1] "Beitrag zur lehre von der Icthyosis," &c. Dr. Johannes Esoff, 'Virchow's Archiv,' 1869, vols. iii and iv.

been said by some[1] to be an "adenoma of the sebaceous and sweat glands."

Such sebaceous glands as are to be seen in these specimens present no striking change, even when compared with those of normal skin; the most that can be said is that their cells are large and their nuclei indistinct.

On comparing the sweat glands with those of normal skin, there is marked departure from the type, although it is difficult at first to point out in what the departure consists—*e. g.* in normal skin, it is not an unfrequent occurrence, instead of a single layer of regularly placed epithelial cells lining a sweat tube, to see the latter crowded with irregularly placed cells, and the lumen almost, or quite, obscured. This latter condition, however, is the rule in the specimens under examination; but the chief departure from the normal consists in the increased amount of fibrous tissue and cells surrounding the sweat tubes. This cell growth is so great in places as to give rise to the appearance of a confused mass of cells, only recognisable as a mass of degenerated sweat tubes, by the fact that these structures exist in the vicinity, and are still faintly indicated in the mass by the grouping of the cells. The *membrana propria* of the sweat glands is swollen.

Turning now to the *corium* and *subcutaneous tissue* nothing definite can be remarked about them. There are many cells in the papillary body, but not more than may be counted in a similar area of normal skin, nor do the cells appear to be aggregated about the vessels.

It will be remembered that the changes hitherto described belong to that part of the section which was nearest to the sound skin. On examining other parts of the section, these changes are seen to become exaggerated as the opposite end of the section is approached. The Malpighian layer of the epidermis becomes gradually thicker, its cells larger, and their outlines indistinct; "*vacuolation*" becomes more frequent, the nucleoli appear double, and by the time the opposite extremity of the section is reached, where the disease is fully established, the appearances of the Malpighian layer are exactly similar to those to be described in the next specimen. The cells increase in the neighbourhood of the hair follicles. The outline of the hair itself is lost; its substance, retaining its fibrous yellow colour, is seen to become merged into the mass

[1] Rindfleisch, "Pathological Anatomy," 'New Syd. Soc.,' vol. i, p. 400.

of cells surrounding it, processes passing between them; finally the hair substance is no longer recognisable, its place being taken by a concentric lamination of cells (fig. 1, *c*). This appearance may, however, be accounted for by the section having traversed the bulb low down.

In the *corium* and *subcutaneous tissue* straggling groups of small cells (many with blood-vessels in their midst) gradually appear; and where these groups of cells lie close beneath the rete Malpighii, there is much germination of cells from the margin of the latter structure.

Fig. 1 represents a part of the section just described, where the first well-marked groups of cells appear. Two groups (*f*, *g*, fig. 1) are seen, lying scattered round blood-vessels, in which blood-corpuscles (not represented in the drawing for the sake of clearness) may still be recognised. A third group (fig. 1, *e*) lies nearer the surface, its cells blending with those germinating from the rete Malpighii. Deep below the surface, are two somewhat obliquely divided hair follicles, with their contents; their condition has been noticed in the description.

From this point in the section the cell-growth becomes more marked, the groups of cells coalesce until at the opposite extremity, viz. that remote from the sound skin, the cell growth forms a continuous layer, replacing all superficial structures below the rete Malpighii.

Passing on now to the microscopical appearances seen in specimen No. 2, the sections being cut in the same plane and direction as those from No. 1, *i.e.* at right angles to the surface, and in a direction towards the centre.

The entire section bears a great resemblance in its general appearance, to that portion of the last preparation which was described as the part where the disease was fully established. The Malpighian layer seems to have reached a climax of irregularity; processes of all sizes and shapes, dipping down into the small-celled growth beneath. In some places, the processes seem, as it were, to anastomose with each other, enclosing islands of cells; in others, there are broad tracts of epithelial cells extending obliquely far beyond the other epithelial prolongations, sometimes communicating with spaces in the cell growth beneath, as seen in fig. 2. Not unfrequently there may be seen, beneath the Malpighian layer, isolated tracts, and rounded masses of epithelial cells. The corneous layers

DESCRIPTION OF PLATE IX.

The figures in this and the following Plate illustrate Dr. Sangster's Observations on a Case of Hypertrophic Lupus. (Page 254.) From drawings by himself.

FIG. 1.—From a vertical section through the advancing border of a patch of lupus on the buttock, showing—(1) Early changes in the epidermal structures, (2) small-cell growth round the vessels.

a. Hypertrophied and irregular rete Malpighii.

b. Transversely-cut hair-follicle, with saccular dilatations.

c, Concentrically-arranged cells, occupying position of hair.

d. Degenerate root-sheath cells.

e. A group of small cells beneath the rete Malpighii.

f. Small cells aggregated round longitudinally cut blood-vessel.

g. Small cells round transversely cut blood-vessel.

Hartnack, Oc. 3, Obj. 4. Tube drawn out.

Fig. 1.



A. Sangster del. R. Mutlow lith.

are represented in places, by a pale green, faintly striated layer, showing an abrupt contrast to the dark purple Malpighian layer, (the specimens are stained with logwood) on which it is placed, or, this pale layer is reduced to a thin band between the Malpighian layer, and a broken layer of fibrous-looking cells; for the most part, however, the Malpighian layer is naked to the surface, the corneous layers having probably become detached in preparing the specimen. On examining the Malpighian layer with a high power (Hartnack, oc. 3, obj. 7, tube out) it presents more the appearance of a number of oval nuclei, scattered at tolerably regular intervals through a somewhat homogeneous matrix (fig. 4, *a*). This is especially the case deep down where the outlines of the cells are very indistinct. The cells and nuclei have attained a very large size.

As the free surface is approached the cells become flat, and their contents, darkly stained and granular, remind us of the changes seen in this situation in normal epidermis. Vacuoles (fig. 4, *b*), which were mentioned as occurring (at first sparingly) in the last specimen, are met with in great abundance; they appear as sharply defined oval or round spaces, occupying the position of the nuclei. There is always to be seen at some part of the circumference of a vacuole, a darkly-stained, crescentic body, sometimes showing itself as a mere dark line bounding part of the circumference, sometimes encroaching more upon the vacuolar space, and occasionally occupying half of it.

Vacuoles are most numerous amongst the proliferating cells, towards the deep boundary of the rete Malpighii; they are, however, to be met with elsewhere, excepting amongst the flattened cells towards the surface. Besides the large oval nuclei of this layer, frequently possessing double nucleoli, there are other nuclear bodies, lying sparsely scattered amongst the cells, and apparently on the same level as the latter; in appearance they are very similar to the smallest cells to be met with in the cell-growth below. In many places two or three of these bodies occur together, giving an *hour-glass* or *trefoil* appearance (fig. 4, *c*).

But it is below the rete Malpighii that there are the most striking changes. With a low power (Hartnack, obj. 4, oc. 3.) a dense cellular infiltration is seen extending to a variable depth. With this magnifying power nothing else is visible as far as the infiltration extends but small darkly stained cells. Frequently, however, it may be from a level close beneath the rete Malpighii,

the cell-growth is seen to be traversed by strands and bundles of fibrous tissue. Forming a marked feature in the section under examination are certain round or oval spaces (fig. 2, *c*), placed at varying depths beneath the rete Malpighii, but at tolerably regular intervals. On placing one section over another, these spaces are seen to correspond in position. In nearly every instance some prolongation from the rete Malpighii communicates with the above-mentioned spaces (fig. 2); the latter are lined wholly, or in part, by epidermal cells exactly similar to those of the rete Malpighii (fig. 2, *d*). These cells are arranged concentrically.

Scattered throughout the cellular infiltration are the multinuclear bodies, which have been described as the giant-cells of lupus (Langhans, Freidländer). Recently Prof. Lang[1] has denied that they are of the nature of giant-cells, and gives reasons for supposing them to be degenerated sweat tubes. Certainly, there are to be met with in these specimens bodies indistinguishable from giant-cells, while there are others which would seem rather to be of the nature described by Prof. Lang.

On examining a portion of the cell growth with a high power, say at a spot close beneath the rete Malpighii, the dissimilarity of the cells composing it becomes apparent. The cells differ in size, shape, and in other particulars—*e. g.* the degree to which they are stained by logwood (fig. 4). The smallest cells are round and darkly stained, resembling, in every respect, similar bodies, which may be seen lying amongst the red blood-corpuscles (when the latter are found occupying blood-vessels), and presumably white blood-cells. There are other round cells, larger than the above, lighter coloured, and with granular contents.

Lastly, there are oval bodies, conspicuous for their shape and faint colour; they resemble the nuclei of the deep Malpighian cells, many of them leaving a point-like nucleus (nucleolus?).

Often, in this situation, close beneath the Malpighian layer, these varieties of cells bear no definite relation to each other as regards their arrangement, appearing to be scattered promiscuously through the meshes of a faint, structureless, intercellular substance; however, at a lower level, the oval cells become arranged end to end in rows (fig. 4, *e*), the space between the rows being sometimes occupied by blood-corpuscles. This indefinite tissue passes into that

[1] "Proceedings of the Neusbrücker Naturw-Med. Vereines vom., 1 Juli, 1874."

DESCRIPTION OF PLATE X.

Illustration of Dr. Sangster's Case of Lupus—(*continued*).

FIG. 2.—From a vertical section through the exuberantly tubercular portion of a patch of lupus on the buttock, showing the superficial layers of the skin replaced by lupus tissue.

a. Rete Malpighii hypertrophied and irregular.
b. Prolongations from rete Malpighii continuous with
d. Epidermal cells, partly lining
c. One of the spaces from which degenerated epidermal structures (hair, gland, &c.) have dropped out during the preparation of the specimen.
e. Fibrous tissue of skin.

Hartnack, Oc. 3, Obj. 4. Tube drawn out.

FIG. 3.—From a vertical section through the cicatricial centre of a patch of lupus on the buttock, showing—

a. Imperfectly formed corneous layer.
b. Rete Malpighii.
c. Irregular papillæ occupied by
d. Lupus tissue.
e. Fibrous tissue bundles crossing in all directions and enclosing
f. "Nests" of lupus tissue.

Hartnack, Oc. 3, Obj. 4. Tube drawn out.

FIG. 4.—From a vertical section through a lupus tubercle, showing the proliferation of cells at the margin of the rete Malpighii, and also the adjoining lupus tissue.

a. Nuclei with nucleoli of Malpighian cells.
b. Vacuoles.
c. Migrant cells, dividing
d. Germinating cells at the margin of rete Malpighii.
e. Oval nuclei in the walls of the vessels traversing lupus tissue.

Hartnack, Oc. 3, Obj. 8.

Fig 3

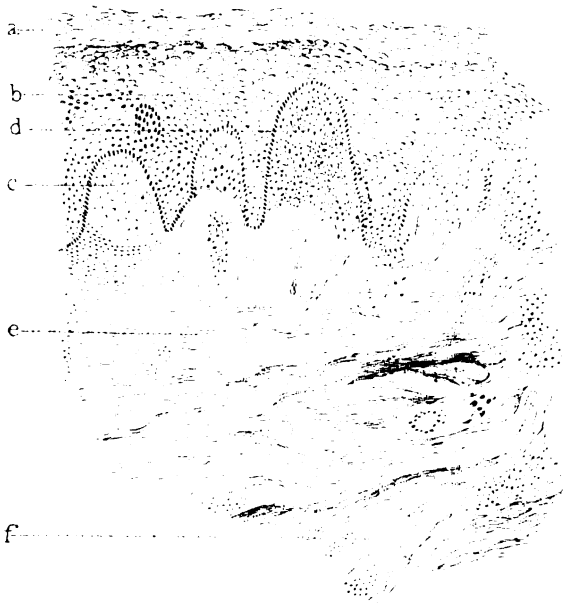

Fig 4

Fig 2

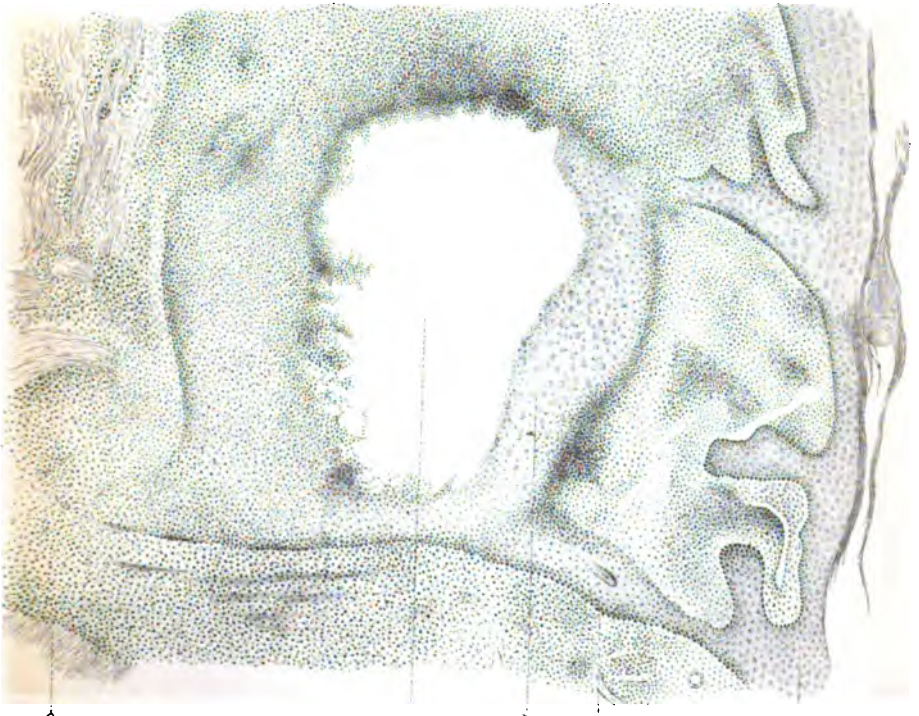

composing the fibrous bundles in a manner exceedingly difficult to trace.

Fig. 3 (Plate X) represents part of a vertical section of material taken from the hard cicatricial centre of the growth. The papillæ are irregular in size and shape, and there is a corresponding irregularity in the Malpighian layer as it dips between them, but the last-mentioned stratum assumes a tolerably uniform thickness, and its individual cells approach the normal type. The Malpighian layer is covered by a thin stratum of corneous cells, irregular and polyhedral in outline, resembling those described in specimen No. 1.

The substance of the papillæ is still occupied by the indifferent lupus tissue before alluded to, but there is more intercellular substance present in it. Close beneath the papillæ appear bundles of fibrous tissue, bold in outline, and cut in every direction, while in compartments formed by the interlacement of these bundles are seen collections of small cells.

In commenting upon the appearances just detailed, first of all attention may be drawn to the fact that changes are observed in the epidermal structures before the characteristic lupus cell growth can be made out in the corium. The above epidermal changes, however, belong to cell-germination (proliferation); hence the irregularity of the different strata composing the epidermis, and the outgrowths from the root-sheath of the hairs, &c. Consequent upon this rapid cell germination there is departure from cell type, until, at a spot where the lupus cell-growth first appears in the corium (Plate IX, fig. 1), the cells composing the hair structures are so far degenerated as to be scarcely recognisable. Next, as to the lupus cell-growth in the corium, the cells appear clustered round blood-vessels, and where they approach the Malpighian layer, at that spot there is cell-germination from the margin of the last-mentioned structure.

These facts are of special interest, as bearing upon the question of the point of origin of the lupoid infiltration. It was formerly maintained by observers[1] that the rete Malpighii was the origin of the lupoid process; in other words, that the cells found in the corium were germinated from its margin; and it must be allowed that if a specimen of skin, affected with advanced lupus change, were selected, such as that represented at fig. 2, the above theory might well be put forward where the cell infiltration is seen extending

[1] Berger, "De Lupo Dissertatio inauguralis Gryphiæ," 1849; Pohl, 'Virchow Archiv,' Band vi, p. 174.

beneath a Malpighian layer in an active state of germination, and with a margin almost obscured by young cells. It is now, however, generally believed that the earliest changes of lupus are to be sought for in the shape of an independent cell growth in the corium, either affecting it as a whole, as held by Neumann,[1] Auspitz;[2] superficially, as held by Virchow,[3] Billroth;[4] or beneath the vascular layer, as held by Kaposi.[5]

The cell-growth is to be found in the neighbourhood of blood-vessels, and the last-mentioned author, in his article on lupus, in Hebra's work on 'Skin Diseases' (Trans. New Syd. Soc.), has very rightly maintained that other theories which assign to the neighbourhood of the sebaceous glands and hair follicles the primary seat of the disease, are only apparently in contradiction, inasmuch as the connective tissue surrounding these structures forms the most vascular portion of the corium. The same author remarks:—"The manifest discrepancy which exists between the views above noted depends simply and solely on the circumstance that most of the investigators have drawn their conclusions from lupus in a more or less advanced stage of development."

It is somewhat difficult to make the appearances detailed as belonging to Specimen 1, where the disease is advancing upon the sound skin, fit in with the theory which supposes the essential nature of lupus to be a cell infiltration round the superficial vessels of the corium.

How are the degenerative changes seen in the epidermal structures, before the cell infiltration is to be recognised in the corium, to be accounted for? Probably as due to the collateral hyperæmia and inflammation, which is present in the neighbourhood of most growths. Certain it is, that such epidermal changes are not peculiar to the skin in the neighbourhood of lupus, but that they occur in many morbid conditions (Rindfleisch).[6] On the other hand, may they not be due to an early stage of cell infiltration, such as might escape notice, but still be sufficient to give rise to an irritative growth from epidermal cells in the neighbourhood?

However this may be, it would seem from appearances, such as

[1] 'Text-book of Skin Diseases,' translated by Pullar, 1871.

[2] "Die Zelleninfiltration der Lederhaut," 'Med. Jahrb.,' Wien, 1864.

[3] 'Geschwülste,' Band ii, p. 487.

[4] 'Allg. Chirurgie,' 1869, p. 449.

[5] 'Archiv f. Dermatol. und Syphilis,' 1869.

[6] Loc. cit.

may be seen at (*e*) fig. 1, and from those described in the text as belonging to the sweat-glands, that where cell accumulations occur in the neighbourhood of epidermal structures, they are partly made up of small-cell growth in connection with blood-vessels, partly of epidermal or epithelial cells in a state of irritative germination.

In fig. 4 the condition of the Malpighian layer may be noticed as showing the changes its cells undergo when multiplying rapidly. The large swollen cells, with their nuclei and double nucleoli, point in this direction. Vacuoles, also signs of rapid cell-growth, are plentiful, and are probably produced by shrinking of the young nuclei as a result of the preparation undergone by the material. This is supported by the fact that all gradations may be seen from the crescentic body, occupying part of the circumference of the vacuole, to the slightly shrunken nucleus with crumpled borders, scarcely filling the vacuole in which it lies. As the nucleus gets smaller it becomes more darkly stained, and, where it reaches the condition mentioned above, namely, that of a crescentic body occupying part of the circumference, it gives an appearance as if the vacuole were a cavity punched out of material whose thickness was indicated by a dark line (fig. 4, *b*). The existence of lymphoid cells in the rete Malpighii (fig. 4, *c*) is a phenomenon which occurs in many pathological conditions of the skin. The above-mentioned cells migrate from the papillary body.

The large round or oval spaces in the cell-growth indicate the positions formerly occupied by the degenerated hair and gland structures, which have fallen out *en masse* during the preparation of the specimens. As favouring this view may be mentioned—(1) the conspicuous absence of hair or gland structures in the specimens of advanced lupus cell-infiltration; (2) the tolerably regular position occupied by these spaces and their correspondence in sections cut from the same material; (3) the fact that they are nearly all in relation with the Malpighian layer, by prolongation from that structure extending to them; (4) they are, for the most part, lined wholly or partially by flattened epidermal cells, the degenerate cells of the sebaceous glands or external root-sheaths. But the best proof is seen in one specimen, where a stunted hair still occupies the centre of a mass of degenerated epidermal cells prolonged from the rete Malpighii, and in connection with one of the cavities above mentioned.

In fig. 8 the lupus is undergoing involution, and the nests of cells

are probably becoming metamorphosed into the fibrous bundles amongst which they lie.

In this stage of lupus, as is well known, there is cicatrisation; this is the sign which betrays the lupoid process, however mild it has been; but, although the superficial structures of the skin are destroyed, there is sometimes a gain, rather than a loss, of tissue.

This has happened in the present instance, where, by the extreme chronicity of the lupoid process, the infiltration, instead of becoming destroyed by ulceration, deep and rapid, has gradually extended through the entire tegument; and, undergoing fibroid change, has given the hypertrophic character to the disease.

Summary of Microscopical Appearances.

1. Changes (cell-germination proliferation) are observable in the epidermal structures before the lupus cell-growth can be made out in the corium.

2. The lupus cell-growth in the corium appears first in clusters round the blood-vessels.

3. Where the clusters occur in the neighbourhood of epidermal cells, they are accompanied by what appears to be an irritative germination of the latter.

4. Where the cell-infiltration is great, it replaces all superficial structures below the rete Malpighii; the hair follicles, sweat glands, &c., disappearing as a result of degenerative change.

5. The rete Malpighii, covering extensive cell-infiltration, is in a state of extreme activity, simulating appearances seen in epithelioma.

6. In the cicatricial stage, there are seen only lupus "nests" lying in meshes of fibrous tissue, covered by an irregular Malpighian layer, with flattened cells representing a stratum corneum.

March 5th, 1878.

---

3. *The minute anatomy of dysidrosis.*

By Tilbury Fox, M.D., and H. Radcliffe Crocker, M.D.

A. General Remarks.—The section we now show to the Society, and from which the accompanying drawings have been taken, illustrate the minute changes in the skin in dysidrosis, origin-

ally described by Dr. Tilbury Fox's 'Skin Disease, their Description, &c.,' 1874, and figured in his atlas in Plate 51. They were made from a portion of skin removed from the palm of the hand of a young woman admitted by Dr. Fox into University College Hospital under his care.

The disease was at very different stages in the particular case referred to, but a portion of skin was selected for removal where the disease has existed between three and four days only, the object being to determine the earliest changes that occur, or, in other words, the initial lesions; since, in the later stages, the inflammatory changes spread somewhat to the parts adjoining the original anatomical seat of the disease, and more or less mask its real nature.

The clinical features of the disease in the portion of skin before its excision were briefly as follows:—Redness: slight tumefaction, prominence, or increased distinctness of the *ridges* of the papillæ, the openings of the sweat follicles being more than usually distinct, and in many cases enlarged, the formation of small vesicles, presenting the appearance of little boiled sago grains, *imbedded in the surface, and not at all raised or projecting above the level of the skin, as in ordinary vesiculation*, these vesicles developing in the site of the previously distended sweat ducts. In many cases the opening of the sweat duct occupied as it were the centre of the imbedded vesicle, and was recognisable as a minute white rim in the area of the latter. In other parts of the skin the disease, in its more advanced stage, was attended by the formation of distinct raised vesiculations, loculated bullæ, bursting of the bullæ, and discharge of inflammatory fluid, &c.

B. Microscopic Examination.—Under a low power the horny layer of the skin presented no change, but loculi were observed to be formed in the rete Malpighii, and to be interpapillary in situation. The capillaries of the papillæ were normal apparently, but the sweat ducts were very distinct in certain parts in their whole course, and the sweat glands *apparently* swollen and somewhat infiltrated. There was no appreciable change in the true corium structure, but its capillaries, especially those that ran to and from the sweat apparatus, were here and there somewhat large and distended.

The accompanying drawings were taken from specimens selected from some 70 or 80 sections, to illustrate in detail the minute changes that take place in dysidrosis.

Fig. 1 (Plate XI) is a correct representation of the upper part of a sweat duct, magnified about 200 diameters. The duct immediately adjoined other ducts which were larger than usual. The illustration shows the commencing dilatation of the duct began to be very perceptible just at the point of the entrance of the duct into the rete from the horny layer, whilst a distinct globular dilatation was formed at the upper portion of the rete, as shown at (*a*) in the middle part of the drawing. There are three points where the duct coil is cut, one above where the duct enters the globe, one at the left side, and one below where the duct continues from the dilatation. It is difficult to say whether the duct has burst here or not, or been dilatated, or both, but at all events the cell tissue round about the dilatation has been flattened or stretched out by the globular enlargement, which was filled with epithelial and granular matter. Lower down at (*b*) the duct seemed to be completely choked and obliterated, and about it at this part was distinct inflammatory cell infiltration. The globular dilatation, or commencing "sago grain-like vesicle," (*a*) is represented as entirely connected with the sweat duct, and as having no connection with the vessels of the papillæ, but to be situated, as was the case in the original specimen, between the vascular papillæ In many other specimens the lumen of the sweat ducts was more or less narrowed or filled with epithelial products. Fig. 4 (Plate XII) is a representation, under a power of 250 or rather more, of a portion of the rete wall about a commencing globe, showing the stretching out of the rete cells into pseudo-fibres, under the influence of dilatation of and effusion from the sweat ducts. The epithelial rete cells tend to assume the several forms seen in the formation of a blister, the cells moreover become granular, and in a more advanced stage leucocytes appear in the part. The vesicles begin, therefore, *so far as the tissue of the rete is concerned*, by the cells of the rete becoming more transparent when they are unstained by carmine, so that a bright circular area is formed, containing the elongated epithelial cells, in which the nucleus and nucleoli are clearly discernible, surrounded by granules, with which the whole cell is filled.

Fig. 2 (Plate XI) (× 150 diameters) shows the nature and structure of one of the imbedded "sago grain-like vesiculations," seen through the skin in the early stage of dysidrosis before there is any elevation of the cuticle like ordinary vesiculation. This constitutes the next stage of the disease. The drawing really explains

DESCRIPTION OF PLATE XI,

The figures in this and the following plate illustrate the observations of Dr. Fox and Dr. Crocker on Dysidrosis. (Page 264.)

FIG. 1.—The upper part of a sweat duct, showing at—*a*. Commencing dilation of the duct into a globe in the rete. *b*. Cell infiltration around the choked duct lower down. × 200.

FIG. 2.—One of the "sago grain-like vesiculations" seen imbedded in the skin in an early period of dysidrosis, showing its connection with the sweat duct, which is seen entering the globe above and leaving it below. × 150.

FIG. 3.—Two globes or vesicles in a more advanced stage, situated side by side.

Fig 1.

Fig 2.

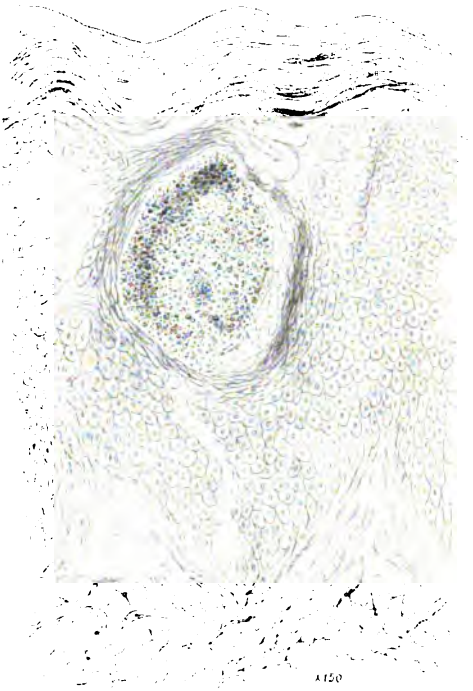

Fig 3.

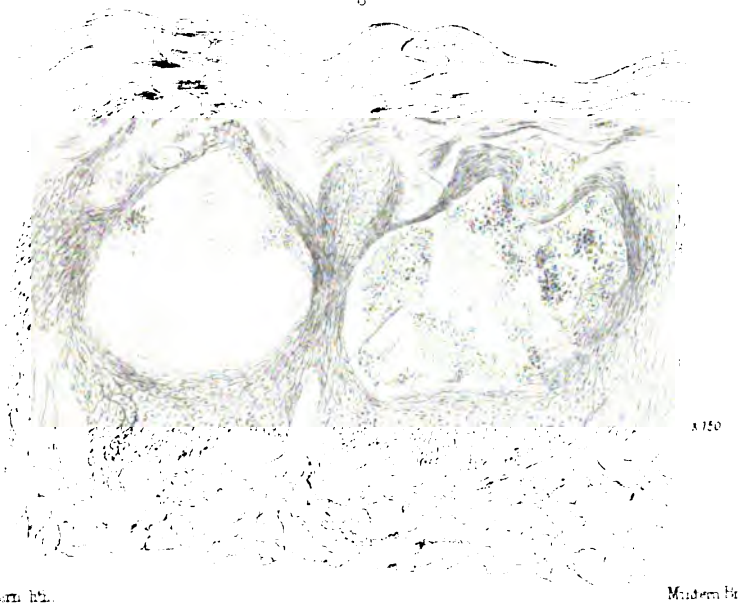

itself; there is a dilatation in the rete, interpapillary in situation, that is, in the line of the run of a sweat duct. The outermost wall of the globe is formed by stretched-out rete cells (see fig. 4). The sweat duct is seen entering the globe to the right of its apex, and also leaving the globe below. The contents of the globe are young epithelial cells, probably those of the duct, and granular matter. The tissues immediately outside the vessels in the papillæ are normal. It is impossible to refuse the conclusion that the globe must be regarded as originating in dilatation of the upper part of the sweat duct and the rete Malpighii tissues, around the cells of which are put upon the stretch by the fluid which is secreted from the sweat apparatus and its vessels.

Fig. 3 (× 150) shows a similar condition, as illustrated by two "globes" seated side by side. The sweat ducts were in the original specimen seen to enter the globes from above as indicated, but only in the globe to the left was there any sign of the exit of the duct from the inferior part.

The largest of all vesicles in the disease, and as shown by other specimens, appear to be formed by the coalescence of several smaller ones, for various intermediate conditions are formed with more or less of the ruptured walls of the compound vesicles projecting into the large compound vesicle. But at this stage of matters, clinically, there exists distinct elevation of the cuticle into vesicles and small or larger blebs; and it is worthy of note here that the bullæ that form secondarily in dysidrosis are loculated, and are in their early stage till broken up unlike those of pemphigus in this respect.

Of course in many of the sections vesicles without sweat ducts going into them may be seen, but this might be anticipated, since in making vertical sections of a flask-shaped body, many more of the bulb alone would be made than of the bulb and neck together, but as a matter of fact the sweat ducts can be seen entering the globes in a considerable proportion of instances. In no case can the vesicle be made out to be formed in connection *with the vessels* or the escape of fluid from them. This fact, and that of the commencement of the vesicles in the interpapillary spaces, demonstrate that the diseased process begins either in or around the sweat apparatus, where the coils become close together, but since the sweat glands can be shown, as will be directly illustrated, to be inflamed, that it commences primarily *in* and not around these sweat structures.

Figs. 5, 6, and 7 (× 200) (Plate XII) illustrate the changes that

go on in the deepest parts of the sweat structures. In fig. 5 a dilatation of the sweat duct in the Malphigian layer is shown with a really less force than in the original specimen. There are indications of the duct entering the highest part of the rete. The duct, as it is continued downwards, is exceedingly distinct, and its walls are certainly thickened and loaded with cell infiltration; its lumen is not so obscured as in other cases. Largish capillary vessels course to it, but the vessels of the papillæ themselves are not unusually prominent. Fig. 6 is the portion of a gland to which the duct in fig. 5 ran. The arteries, *a*, *a*, in it were large and full; the connective tissue elements enclosing the gland structure were increased, and the cell elements were marked and distinct, the lumen of the gland coils was in parts obscured by choking with cells within the coils, and the walls of the coils were loaded with cell infiltration. These changes were better seen in a portion of an adjoining gland, which is represented in fig. 7; in this case the gland seems to be stuffed, and its form and structure rendered indistinct by the free cell infiltration, which was more distinct in the original specimen than the drawing.

Throughout the portion of excised skin containing the deepest portion of the gland, *i. e.* the gland coil, these changes were common. They are not at all exaggerated in the present figure. In some cases, just where the arteries reached the gland, there was free cell infiltration about the arteries and the adjoining coil of gland.

From the facts before us we conclude that anatomically dysidrosis is an inflammatory affection of the sweat apparatus in which the ducts in the Malpighian layer probably become choked, but certainly distended, which is followed by the escape of fluid from them into the tissue around, giving rise to the formation of characteristic vesiculations which are at first imbedded in the skin, but afterwards, in consequence of the increase of effusion, enlarge so as to cause uplifting of the cuticle and the formation of loculated bullæ. Dysidrosis is, therefore, wholly distinct from eczema, and deserves recognition as a special form of cutaneous disease.

May 21*st*, 1878.

DESCRIPTION OF PLATE XII,

Illustration of Drs. Fox and Crocker's remarks on Dysidrosis.—(*continued.*)

FIG. 4.—A portion of the rete tissue which bounds a globe, showing the stretching out of the cells under the pressure exerted by the dilating globe. × 250.

FIG. 5.—Shows a commencing globe in the rete, with cell infiltration along the wall of the duct as it runs downwards through the corium. × 200.

FIGS. 6 and 7.—Cell infiltration about the coils of the sweat glands. In fig. 7 the coils are rendered indistinct by the large amount of inflammatory cell infiltration.

Fig. 4

x 250

Fig. 5

Fig. 6

x 400

Fig. 7

x 400

F. Mitchell, Del.

W. Ogden, Sc.

IX. SPECIAL COMMUNICATIONS.

(A) ON DISEASES OF THE LYMPHATIC SYSTEM, INCLUDING LYMPHADENOMA AND LEUKÆMIA.

1. *Lymphadenoma and leukæmia.*

By SAMUEL WILKS, M.D.

DR. WILKS exhibited the original specimens, collected by Dr. Hodgkin, of the disease associated with his name. He observed that Dr. Hodgkin was the first to write an original paper on this matter, although, as he truly points out, the appearances described must have been met with before. Indeed, Morgagni and others had mentioned cases, and specimens were even brought before the Pathological Society, at a time when Hodgkin's paper lay buried in the 'Medico-Chirurgical Transactions.' Dr. Wilks took credit to himself for having unearthed that paper, which is contained in vol. xvii of the 'Transactions' (for 1832), and is entitled, "On some Morbid Appearances of the Absorbent Glands and Spleen." Six cases are described in that paper, and the viscera from five of these are preserved. Dr. Wilks then gave a brief *résumé* of four of these cases, as recorded in Dr. Hodgkin's paper. The first case was that of a boy, aged nine, admitted into Guy's Hospital, under Mr. Morgan, in 1826. He died of dropsy and peritonitis. There was enlargement of the bronchial and mesenteric glands, and a continuous chain of enlarged lumbar glands occurred around the abdominal aorta and along the iliac vessels. The liver "contained a few tubercles somewhat larger than peas, white, semi-cartilaginous, and of an uneven surface. . . . The spleen was large and contained numerous tubercles." The second case was that of a boy, aged eleven, under Dr. Bright's care in 1828, with enlarged cervical glands and spleen. The glands in the neck were in the "form of large, smooth, ovoid masses, connected together merely by loose cellular membrane and minute vessels;

when cut into they exhibited a firm cartilaginous structure, of a light colour and very feeble vascularity, but with no appearance of softening or suppuration." The bronchial, mediastinal, and abdominal glands were similarly enlarged. The spleen was enlarged to "four times its natural size, its surface was mammillated, and its structure thickly sprinkled with tubercles, presenting the same structure as the enlarged glands." The third case (No. 4 in Dr. Hodgkin's paper) was that of a man aged fifty, who was under Dr. Addison in 1829, with enlargement of axillary, inguinal, cervical, and lumbar glands. Those in the neck were of soft consistence, and Dr. Hodgkin says that the change seemed to consist in an interstitial deposit from a morbid hypertrophy of the glandular structure. The spleen was greatly enlarged and studded by numerous "small, white, nearly opaque spots." A fourth case (No. 6 in the paper) was of a man, aged fifty, under Dr. Bright's care in 1830, with glandular enlargement in axilla, neck, and groins, and also of the mediastinal and lumbar chains. There were "two or three white tubercles" in the liver, but the spleen was unaffected. Dr. Hodgkin then makes some remarks upon the disease, arguing against its inflammatory character, or its being due to any adventitious formation. He concludes :—"Notwithstanding the different characters which this enlargement may present, it appears nearly in all cases to consist of a pretty uniform texture throughout, and this rather to be the consequence of a general increase of every part of the gland than of a new structure developed within it, and pushing the original structure aside, as when ordinary tuberculous matter is deposited in these bodies." And with reference to the spleen, which, with one exception, was more or less diseased, he concluded that, "if there be a close connection between the derangement of the glands and that of the spleen, the latter is a posterior effect, and on this account may not always have been produced when that of the glands or some other disease carried off the patient." It was clear, then, that Hodgkin saw he had to deal with a new disease associated with the malignant diseases; and at the end of his paper he refers to some papers shown him by Dr. Carswell of a case he had met with in Paris, and which he had called "cancer cerebriformis of the lymphatic glands and spleen." After giving Carswell's description, Hodgkin says: "Although the doctor has employed the term 'cerebriform cancer,' which conveys a ready idea of the texture of the diseased glands, he will excuse my differing

from him so far as to regard the affection in this case as distinct from cerebriform cancer." Bright, in his papers on "Abdominal Tumours," describes the condition of the spleen met with in association with general enlargement of absorbent glands, as pointed out by Hodgkin, and describes it as a form of malignant disease. He gives a drawing of the spleen from such a case (see collected papers, New Sydenham Society, p. 180, fig. 49). In 1858, before Hodgkin's paper had been brought to light, specimens of "fibrinous deposits in the spleen, thoracic glands," &c., were shown to the Pathological Society by Dr. Markham. The tumours were examined by Drs. H. Jones and Sieveking, as well as by himself, but not found to have any cancerous characters. Dr. Bristowe, reporting on the specimens, corroborates Dr. Markham's view, and says "that the condition seems to be the result of a fibrinous deposit, probably caused by slow inflammatory changes," adding that "certainly there is little evidence, microscopic or otherwise, to induce a belief in its malignant character, and the evidence in favour of its scrofulous nature is scarcely stronger." It was clear, then, that Hodgkin's disease has relations with malignant disease, and upon this Dr. Wilks hoped to hear some further remarks. It must be remembered that our classification of disease is artificial, and not natural, and lymphadenoma might, as he had said, behave just as cancer does, and lead to death by invasion of vital organs. Not long ago he saw a case in which an intra-thoracic growth of this kind had infiltrated the chest-wall, and led to fracture of the ribs. He hoped also the relation of this disease to tubercle would be discussed, and he might also ask if it had any relation to lardaceous disease. He thought he had met with some cases which showed an alliance between these two conditions. He hoped also that the discussion would not close before a definite conclusion was arrived at as to the state of the blood in Hodgkin's disease. Virchow, in his 'Cellular Pathology,' had discriminated between leukæmia splenica and leukæmia lymphatica, and Dr. Wilks thought that confusion had arisen between the latter group of cases and those of Hodgkin's disease; for there seemed to be a prevalent opinion that in Hodgkin's disease there was also leukæmia, or at least leucocytosis. But he had never met with marked leucocytosis in Hodgkin's disease. The subject of leukæmia was a large one; but in regard to it he hoped to hear more of a remarkable discovery made last year in University College Hospital, in a case under the care of Sir W.

Jenner, where the presence of a large excess of leucocytes in the blood coincided with the formation of an abscess, the temporary leukæmia disappearing after the abscess was opened. One thing he would urge was that the definition of leukæmia should be restricted to the cases where the white blood-corpuscles abounded in numbers equal to or exceeding the red, and not, as had been loosely stated, when twenty or thirty white corpuscles were visible in the field of the microscope. *March 19th*, 1878.

---

2. *Specimens illustrative of the pathology of lymphadenoma and leucocythæmia.*

By W. S. Greenfield, M.D.

In bringing before the Society specimens illustrative of the pathology of lymphadenoma and leucocythæmia, it will be convenient to give some account of the cases from which most of the specimens are taken, then to describe the histological characters of the morbid changes in different organs, and afterwards to discuss some points in the general pathology and relations of these diseases. But in order to bring more completely into relief the morbid anatomy and histology of lymphadenoma, I have exhibited to the Society a number of specimens from other cases than those now recorded, some of which have already been shown to this and other societies, and have thus endeavoured to illustrate the several stages of the changes in various organs. Briefly to mention these, they are specimens from the liver in two cases, the spleen in three cases, the glands in three cases, and drawings of the naked-eye appearances of the liver and spleen in typical cases. The microscopic specimens were selected from sections of the glands in various parts of the body in seven cases, from the spleen in seven cases, the liver in two, and the skin in two, and also from growths in the omentum, the lungs, &c. Together with these, microscopic drawings illustrative of some of the most important changes are shown.

I have been able only to bring one case of leucocythæmia, of which specimens and drawings from the liver, spleen, and kidney, and microscopic sections and drawings from the same organs, are shown.

CASE 1.—*Hodgkin's disease, with affection of the cervical and mediastinal glands and typical affection of the spleen.* (For the notes of this case I am indebted to Dr. Murchison).

Frederick B—, æt. 26, a gasfitter, admitted to Arthur Ward, St. Thomas's Hospital, under Dr. Murchison, on June 7th, 1875.

Family history.—Parents both alive and healthy. Two brothers and one sister fairly healthy. No family history of gout, rheumatic fever, or other illness. No history of any ailment similar to that from which the patient suffers in his family.

Previous history.—Not sure whether he has had measles or hooping-cough. Has not had scarlet fever or smallpox, gout, nor rheumatic fever. Has never had any venereal disease except gonorrhœa. Was in this hospital three years ago, under the care of Dr. Clapton, for eczema, which was general.

Present illness.—Began about three years ago, when, on recovering from eczema, he perceived a lump beginning on the left side of his neck just below the ear and just outside the jaw; from his description this seems to have been an enlargement of the parotid. From this first enlargement seems to have started a general enlargement of all the lymphatic glands of the neck. The glands in the axilla are also enlarged. These glands have all varied in size from time to time, so much so that they seemed to be going to return to their normal state. For the last year they have not changed in size. Though he has been under treatment on and off for the last three years it does not appear that the improvement was due to medicine. During the last two months his belly has swollen, and he has discomfort after food. About a week ago he caught cold and had pain in his side, and a cough which interfered with his sleep. He had not lost flesh till about two months ago, since which time he has become much emaciated. On June 6th his ankle began to swell, and he thought he had dropsy. This alarmed him, and he consequently applied for admission. He is feeling very weak, and his bodily condition has been further aggravated by business worry.

State on admission.—A large lobulated tumour, consisting apparently of enlarged glands, on either side of neck; the total girth of the neck is nineteen inches. No pain or tenderness. The glands in both axillæ are also much enlarged. There is, however, no enlargement of the glands in the groin. Patient is anæmic; complains of great weakness and inability for exertion. Tongue pale, coated. Appetite generally good. Bowels usually costive. Has uncomfortable

distension after food. Hepatic dulness does not ascend too high. Lower margin of liver cannot be made out distinctly, but the organ does not appear to be enlarged. In the left hypochondrium is a firm large tumour, extending forwards to within half an inch of the navel and going down to the brim of the pelvis; its anterior margin is distinctly indented in two or three places, and the dulness is continuous with that in the normal position of the spleen. Blood contains about ten or twelve white corpuscles in the field of a ¼ inch objective. Pulse 84. Heart sounds normal. Temperature last night 101·2°, this morning 99·5°. Urine 1015, no albumen. The temperature rises at night, but in the morning is normal. Occasional cough and expectoration of a small quantity of frothy mucus. No dulness, râles, or tubular breathing over chest.

Ordered Pot. Iod. gr. v, Syr. Ferri Iod. ʒss, Aq. ʒj, t. d. s. Full diet. The following temperature observations were noted:—

	Morning.	Evening.
June 6th	—	101·2°
„ 7th	99·5°	101·2
„ 8th	99·5	100·2
„ 9th	—	102·2
„ 10th	—	(p.m. 98·6) 100·8
„ 11th	99·2	100
„ 12th	98·8	—
„ 13th	98·	—
„ 14th	99·	100
„ 15th	98·6	99·9
„ 16th	—	100·2
„ 17th	98·6	99·8
„ 18th	97·8	—
„ 19th	98·2	100
„ 20th	—	100·4
„ 21st	99·8	100
„ 22nd	98	—
„ 23rd	—	99
„ 24th	—	100·5
„ 25th	100·2	—
„ 26th	—	99·6°
„ 27th	98·6	—
„ 28th	—	100
„ 29th	—	98·4
„ 30th	—	100·
July 3rd	97·8	—
„ 8th	—	100

June 26th.—The appetite failing, the medicine was changed to Ac. Nitro-Hydroch. dil. ♏xv, Tr. Nucis Vom. ♏x, Aq. ad ℥j, t. d.

14th.—Patient began to take ♏x of Phosphorated Oil in mucilage and water three times a day. The appetite, which had improved with the acid treatment, continued pretty good, and the patient began to feel stronger, but on September 18th, the signs of left pleurisy supervened, and he died on the 19th.

Examination nine hours after death.—Body considerably emaciated; large glandular swellings in neck on both sides. Recent longitudinal incision over upper part of trachea (tracheotomy).

Thorax, &c.—On opening the thorax there was found to be considerable œdema of the subcutaneous tissue. Beneath skin, just below the clavicles, were found one or two small white, glandular-looking nodules, not adherent to the surrounding tissues. On removing the sternum and cartilages, two or three small glandular masses were found in the anterior mediastinum, closely adherent to the sternum and rib cartilages; one of these, about 1½ inch long by ¾ wide, was situate opposite the second left intercostal space, which it partly occupied. No larger masses were found in the anterior mediastinum, but there was some œdema of the areolar tissue.

On following the course of the vessels upwards in the neck it was found that from beneath the clavicles upwards there was enormous enlargement of the lymphatic glands. Close behind the right clavicle, to which it was partly adherent, was a large solid mass, extremely dense, hard, and tough, which pressed upon and displaced the right subclavian artery and vein, some of their branches being completely surrounded by the mass. The whole of the anterior and posterior triangles of the neck on the right side were filled and distended by similar glandular masses, all more or less connected together, extending upwards as high as the lobule of the ear. One nodule, which was extremely hard, lay on the inner side of and behind the internal jugular vein, which was tightly stretched over it, and closely adherent to it; but there was no infiltration of the walls of the vein.

On tracing the right vagus nerve downwards, it was found to be free from direct implication as far as the origin of the laryngeal recurrent, at which point there was a hard nodule ¾ inch in diameter, which was firmly wedged between the two, and must have given

rise to considerable pressure. The neurilemma was closely adherent to the nodule.

A mass of glandular enlargement completely surrounded the submaxillary gland, which was found imbedded in the mass, being itself apparently unchanged.

No direct pressure on the trachea could be discovered on the right side. On the left side the enlargement was almost symmetrical with that on the right, but in the lower part of the neck it was even more considerable, being continuous with a mass which passed beneath the clavicle, and along the course of the subclavian vessels, to the axilla, at the anterior border of which was a large irregularly rounded mass.

In the posterior mediastinum were only a few enlarged glands of comparatively small size, not forming a conglomerated mass and not apparently giving rise to any considerable pressure on the trachea or bronchi.

On following the trachea upwards, in the lower part of the neck just above the entrance into the thorax, a glandular nodule, about 1½ inch in length and ¾ inch in diameter, was found on the left side of and slightly behind the trachea, compressing it on that side, the wall of the tube being flattened for about 1 inch, but the compression was not such as to occlude the tube; the little finger could be passed upwards through the stricture pretty readily.

Pleuræ.—Each contained about 2 pints of fluid; slightly turbid on the right side, but with no sign of inflammation.

Lungs.—Both much collapsed towards their lower parts; the lower lobe of the left almost completely so. The remainder of the lungs emphysematous; no new growth discovered in any part.

Bronchi.—Larger branches contain some frothy coagulated blood mixed with mucus, not extending into the second divisions; no blood in smaller branches.

Heart.—Right cavities containing a small quantity of normal clot; left nearly empty; valves, &c., normal.

Peritoneum.—About 2½ pints of clear serous fluid; no sign of inflammation.

Spleen.—Weight 51 oz., of the normal shape, but greatly enlarged in every direction, measuring 10 inches vertically and 6 across, and about 3 inches in thickness. For the most part the organ was of a pretty uniform dull-red colour externally; but here and there were small patches of paler colour, with yellow spots, from the size of a mus-

tard seed, scattered over it. At these points there was also a rounded depression on the surface, resembling that produced by an infarct, these measuring from 1½ to 2 inches in diameter.

On section, the more superficial part of the organ was for the most part of a uniform dull brick-red colour, and extremely soft, whilst in the deeper part the structure was much altered. Running in from the hilus were four or five distinct rounded masses, measuring from 1 to 2 inches in diameter, which were infiltrated with new growth. These masses were harder than the remaining splenic tissue, standing up on the surface of the section and becoming denser towards their centres. The surface of these nodules on section appeared to consist of a great number of small yellowish or whitish nodules on a dark-red ground, the yellowish substance apparently ramifying in the splenic tissue, the appearance entirely corresponding to that of an infiltrating new growth arising from definite centres. In the more peripheral portions of these nodules the lighter portions were of a yellow colour, towards the centre becoming whiter and denser and of a more distinctly fibrous character, forming in some places distinct fibrous bands of white colour. The yellow portions of the new growth were somewhat soft, translucent, resembling melted butter, and could be readily separated from the surrounding red portions. Towards the centre of the masses the whole was firmly coherent. In the hilus of the spleen was a mass of white glandular nodules, which extended also along the course of the vessels towards the liver.

Liver.—Not enlarged; somewhat pale, otherwise normal; entirely free from new growth.

Kidneys.—Pale; cortex slightly thickened, otherwise normal.

Lymphatic glands.—All the glands along the spine were found to be greatly enlarged, in some places forming large masses. This was especially the case with those in the neighbourhood of the cœliac axis, around which was a mass of considerable size. Lying between the aorta and vena cava inferior, close to the origin of the right renal artery, was a greatly enlarged gland, measuring 2 inches in length by 1 inch in diameter; over this the vena cava was stretched somewhat tightly, although it did not appear to be completely obstructed. The glands along the course of the iliac arteries were also much enlarged, but this condition did not extend to the glands in the groin. For the most part the abdominal glands were extremely soft, and on section in some places almost diffluent, of dead-white colour, with yellow points here and there.

Stomach and intestines.—Normal throughout.

Supra-renal capsules.—Not examined.

Brain.—Not examined.

Larynx and trachea.—The trachea contained a coagulum of frothy blood mixed with mucus. The external incision was found to enter the air tube, dividing the lower part of the thyroid cartilage and the cricothyroid membrane, but not extending through the cricoid cartilage. The epiglottis was much thickened, and showed signs of chronic congestion. The aryepiglottidean folds were also greatly thickened, but free from ulceration. The interior of the larynx and trachea appeared normal, except at the point previously mentioned, where compression had occurred, at this point the cartilage rings were flattened, but there was no sign of congestion or inflammation.

CASE 2.—*Lymphadenoma commencing in the cervical glands, with secondary growths in the skin; affection of liver and spleen.*

Edward J—, æt. 9, admitted on March 24th, 1877, under the care of Dr. Peacock, and subsequently Dr. Ord, to whom I am indebted for the following clinical notes.

Father, æt. 43, healthy. Mother died of phthisis at 45 years of age. Of ten children, one died in infancy, one at 17 years of age, and one at 19 years of age of phthisis. One other suffers from chest affection. The others fairly healthy.

Patient has had measles and hooping-cough.

The swelling on the left side of the neck commenced six months ago, and soon afterwards another appeared under the left arm. The patient had had occasional chills and perspirations. About five weeks ago the face became puffy. Bowels have been regular.

There is a large tumour on the left side of the neck, extending almost from the middle line behind to the middle line in front. There is another in the left axilla, about the size of a duck's egg. Other glands in the neck and both groins are enlarged and indurated. There is no obstruction to respiration. Loud râles are heard over both lungs; there is no dulness. Heart normal. Spleen greatly enlarged, liver slightly so. Tongue covered with white fur; papillæ prominent and red.

After admission into the hospital the glandular swellings continued to increase, and became painful and tender, especially in the left axilla. The patient wasted and grew rapidly weaker, and died on May 26th.

Throughout the stay in the hospital the temperature was con-

tinually elevated, reaching often to 103°, and occasionally to 104° and 105°; very irregular in its course. The complete temperature sheet is given below. One day, May 11th, the following courses were noted: 1.30 a.m., 103·2°; 4.15 a.m., 103°; 10 a.m., 103·5°; 2.30 p.m., 103·3°; 8 p.m., 104·2°.

Date.	8—9 a.m.	Noon.	3—4 p.m.	8—9 p.m.
March 24	...	...	...	103·4°
25	102·5°	...	...	103·8
26	101·6	...	...	101·4
27	100·6	...	...	101·0
28	98·6	...	...	99·8
29	98·2	...	97·0°	98·0
30	97·4	...	97·6	97·3
31	97·2	...	97·6	97·4
April 1	97·6	...	97·1	98·0
2	97·6	...	98·0	98·0
3	98·0	...	...	...
4	97·0	...	98·8	99·2
5	97·8	...	98·8	100·8
6	99·1	...	97·2	101·2
7	99·1	...	101·4	100·5
8	100·6	...	103·2	101·6
9	102·0	...	102·2	104·0
10	103·4	101·6°	101·6	105·1
11	103·5	...	103·3	104·2
12	103·5	...	102·6	103·5
13	102·0	...	103·1	103·1
14	102·5	...	101·0	103·0
15	101·0	...	102·4	102·4
16	100·4	...	107·2	101·2
17	100·0	...	99·9	100·4
18	100·4	...	101·2	100·8
19	99·4	...	101·0	100·9
20	98·6	...	101·0	100·1
21	100·2	...	...	100·7
22	102·1	...	...	102·2
23	101·8	...	...	104·3
24	103·2	...	...	103·2
25	104·0	...	...	102·6
26	100·8	...	...	103·4
27	103·2	...	...	103·4
28	103·7	...	...	103·3
29	103·2	...	104·2	...
30	103·0	...	103·2	105·7
May 1	102·6	...	102·6	102·4

Date.	8—9 a.m.	Noon.	3—4 p.m.	8—9 p.m.
May 2	102·2	...	102·9	103·4
3	102·0°	...	103·5°	103·4°
4	103·0	...	...	103·1
5	100·2	...	100·9	101·5
6	101·5	...	...	101·9
7	102·7	...	...	102·6
8	101·1	...	...	103·5
9	104·0	...	...	103·2
10	103·6	...	...	103·3
11	104·8	...	102·5	104·8
12	103·7	...	104·0	103·6
13	104·2	...	...	104·0
14	104·5	...	...	103·6
15	104·1	...	...	103·0
16	102·7	...	...	103·9
17	103·1	...	...	102·2
18	102·5	...	...	102·3
19	102·1	...	...	102·2
20	102·0	...	...	102·1
21	100·8	...	...	101·2
22	101·1	...	...	100·3
23	100·6	...	...	101·1
24	99·7	...	...	101·0
25	99·8	...	...	102·0

Post-mortem examination by Dr. Greenfield.—Body generally emaciated; very slight anasarca of feet. A large irregular mass of glands extended down the left side of the neck, chiefly near the front. The mass very irregular in shape, hard, and nodular, with very numerous smaller outlying nodules. The largest mass situated in the lower half of the neck, but reaching up nearly to the jaw. At the anterior border of the left axilla was a mass the size of an orange, which was also very irregular and nodulated, and adherent to the skin, and was continuous with the mass in the neck by infiltration in the subcutaneous tissue extending over the clavicle. The glandular masses in the neck and axilla were both adherent at several points to the skin, and in the skin covering and around them were seen and felt a large number of nodules, the size of a small pea or larger, quite separate from the underlying growth. They resembled the nodular growths in the skin occasionally seen around cancer of the breast. Some of the nodules were flattened, but the majority were rounded and hard. They extended to below the left nipple. On removing the skin the masses in the neck and axilla were found to be made up of con-

fluent glands, between which hardly any separation could be traced, the glands and surrounding tissues presenting a continuous infiltration, exceedingly hard and in many parts quite fibrous in character. The enlarged glands were irregularly mottled with white and yellowish patches and numerous small, irregularly outlined points, which appeared to be caseous, but there was no sign of softening at any part; rather a tendency of sclerosis and fibroid change. The glandular enlargement in the neck was continuous with those in the axilla and the mediastinum.

Glands on right side of neck enlarged, but not nearly to the same degree as on the left.

A mass of growth occupied the situation of the thymus gland, apparently due to its infiltration; it extended downwards over the pericardium. A few glands in anterior mediastinum enlarged and vascular, some also in the posterior mediastinum enlarged, but no sign of pressure on bronchi.

Pleuræ and pericardium healthy, free from new growth. Left pleura contained a pint of thin fluid. A few small nodular points, resembling grey granulations, were found scattered through the lungs. Heart normal.

Liver appeared somewhat wasted. The gall-bladder contained quite colourless mucus, slightly turbid with whitish flakes, but entirely devoid of bile pigment. Substance of liver generally firm, pale, of somewhat yellowish colour. On its surface were seen a number of irregular, somewhat prominent patches, either single or made up of a number of clustered nodules of small size, with surrounding injection. On section these were found to be irregular infiltrating masses of new growth, which appeared to have become caseous. In addition to these nodules there were very marked thickening and infiltration of the tela conjunctiva of the portal vein and bile-ducts, extending into the liver; and here and there were seen small patches of irregularly ramified infiltration of translucent, waxy-yellowish colour, apparently starting at the periphery of the lobules, these, with the caseous masses before described, being the most evident morbid appearances.

The *spleen* was enlarged, being six inches in length. There was no adhesion to the surrounding organs. Its surface was somewhat irregular, apparently owing to small nodules in the substance just beneath the capsule. On section, the organ presented very typically, but not in a very advanced stage, the condition

usually found in Hodgkin's disease. There were several small patches of somewhat caseous appearance and yellow colour, somewhat irregular in shape, but mostly somewhat rounded, and constituting rather distinct tumours. In addition to these, throughout the whole organ were seen small masses, varying in size from half a line to a line in diameter, usually either rounded, oval, or somewhat ramified, and of very pale, translucent, yellowish colour, sharply defined, and lying in a uniform ground of deep red.

Kidneys very pale, but free from signs of new growth. *Stomach* and *intestines* very pale, but normal throughout. The glands just above the pancreas somewhat enlarged and very hard, adherent to but not infiltrating the pancreas. Glands along aorta slightly enlarged and very much injected. Very slight enlargement of glands along the left external iliac artery. *Supra-renals* normal. Larynx and trachea normal; thyroid quite healthy in appearance. Brain and membranes normal, except considerable œdema of the pia mater, and a general watery condition of the brain.

The microscopic examination of the organs will be described later.

Case 3.—W. R. M—, æt. 22, a carman, was admitted, under the care of Dr. Wilson Fox, to University College Hospital, on March 14th, 1872. (The case was an exceedingly typical one, and my then position as physician's assistant to Dr. Fox gave me the opportunity of careful study of the case, for the permission to use which I have to thank Dr. Fox.) The clinical history may be very briefly given. The man had had fair health till twelve months before his admission, when he noticed a "lump" on the left side of the neck, which, he said, appeared quite suddenly during one night, and persisted, varying in size, but gradually becoming larger. For about a month he had noticed swelling in the left axilla. The swellings were painful and tender, and had not caused much discomfort. An obscure history of diarrhœa at intervals for seven or eight months, and of sweating at night at the same time. He continued at work till seven weeks before admission, when weakness and loss of flesh compelled him to lay up. Always lived in London, well clothed and nourished; admitted considerable excess in drinking; history also of alcoholic dyspepsia; family history good. "Rheumatic gout" a year previous; no syphilis; no hæmoptysis; cough for

some little time; sputa white and frothy. No other points of importance in history.

On admission.—Short, strongly built; dark complexion; extreme anæmia, very marked on mucous membranes and finger-nails; face of dirty pale brownish-yellow waxy tint; brownish discoloration around heart and nipples and along spine; skin of trunk mostly very pale and waxy looking; conjunctivæ of pale bluish tint. Some emaciation, not very marked. Patient weak, restless, tremulous; skin frequently hot and moist; breathing rapid.

A large mass of glands occupying the whole of lower part of left posterior triangle, another mass in anterior triangle near angle of jaw, and other isolated enlarged glands, the size of filberts or horse-beans, and one nearly an inch in diameter, close to trachea. A gland size of walnut in left axilla. On right side of neck, only a few glands felt slightly enlarged, none larger than a bean; one size of a filbert in right axilla, none enlarged in groin. Physical signs of mediastinal tumour pressing on left trachea; great enlargement of spleen.

Blood.—"Red corpuscles very pale, forming rouleaux naturally. No increase whatever of white corpuscles—scarcely any seen in the field. The only abnormal appearance seen consists in small clusters of coloured bodies, apparently cells, not more than half the size of the red corpuscles; these form clusters, but not rouleaux; they are as dark coloured as the others. There are, however, but few groups seen in the field, though scattered ones are pretty numerously seen, and amongst them corpuscles can be found in variable size, from half the diameter of a red corpuscle to full dimensions; they become crenated like ordinary corpuscles, or send out processes; the white corpuscles also send out processes with great activity. Distinct umbilication cannot easily be detected in these smaller bodies."

The daily history of the patient need not be here detailed. The most striking features were, severe paroxysms of fever, during which the temperature rose to 103°, 104°, and on two or three occasions to 105·5°. In these attacks there was increased dyspnœa, sometimes distinct swelling of the glands, with some pain and tenderness, and they were accompanied by profuse sweating at intervals. During the three weeks the patient was under observation, viz. from March 14th to April 11th, two febrile periods were watched, the temperature being taken at frequent intervals during the day. One

of these periods lasted from admission, when the temperature was 104·8° (on the 15th) for eight days, gradually declining during the last four days; then an almost apyrexial period of six days; then a rapid rise, and a pyrexial period, lasting ten days, till death, the temperature on six of those days varying from 103° to 105·5°. Death occurred on April 11th, from asphyxia combined with exhaustion.

After death greatly enlarged glands were found in mediastinum, pressing on the bifurcation of trachea; other glands compressing trachea at root of neck. Great enlargement and typical infiltrating growths in spleen, resembling those described in Case 1, but more uniformly diffused through the organ. (Sections of the spleen and glands were shown.)

CASE 4.—*Lymphadenoma commencing in inguinal glands; great enlargement of the lumbar glands; growths extending through thoracic walls; infiltration of pleura; invasion of wall of vena cava inferior by new growth.*

James C—, æt. 64, bath proprietor, admitted to Edward Ward under Mr. Mac Cormac, on December 10th, 1875. (Died February 11th, 1876.)

Family history.—Father and mother very healthy: died, æt. 74 and 70 respectively, from senile decay; has two brothers and two sisters living and well; all the members of the family long-lived, and no history of tumour.

Previous history.—Remained at birthplace, near Reading, for twenty years; never out of this country; has been Turkish-bath proprietor for sixteen years, and has taken baths repeatedly for lumbago; always in good health, with the exception of an occasional attack of rheumatism; habits temperate.

Previous illness.—Commenced three or four months ago with lump in the left groin about the size of a marble; about three weeks after he noticed a swelling in the right axilla, and another in front of sternum.

These tumours were smooth, hard, and painless, not tender to the touch, and have been gradually increasing in size since their first appearance, and until the time of admission. No history of injury.

On admission.—A man of medium height, with somewhat shrunken appearance; he is said to have lost flesh lately; he has had occasional attacks of dyspnœa lately; no dysphagia; urine acid, free from albumen.

On the front of the chest and to the left of the middle of the sternum is a round hard tumour, the size of an orange, and another above this, and partly overlying the sternum, about the dimensions of a walnut; they are both smooth, and are not lobulated on the surface, nor infiltrating the skin. Some veins are seen ramifying over the swellings; they are not attended with any pulsation, and the breath sounds are fully heard over them. A tumour also exists in the right axilla, the size of a cricket ball, and also some small secondary pedunculated glands, freely movable. The large mass is lobulated, and the integument is freely movable over its surface. There are a few cord-like vessels proceeding from the border, and passing from the deeper surface of the enlarged glands in the axilla.

There is a diffused hard swelling in the right groin, firmly attached to and apparently extending deeply into the pelvis. As far as it is possible to judge, it corresponds in size to the clenched fist, is oval in shape, with its long diameter corresponding to Poupart's ligament; the skin cannot be pinched up over its centre.

Numerous enlarged glands on the side of the neck over the sterno-mastoid and in suboccipital region. Much atheroma and swelling of the whole of right lower extremity, probably caused by pressure on the femoral and iliac veins; also œdema of scrotum and penis, and lower part of back, extending to tenth dorsal vertebra.

Spleen much enlarged, extends three inches below ribs in left nipple line; liver apparently not enlarged; heart sounds normal. Lungs carefully examined; resonant anteriorly; faint breath sounds at lower part of both; incomplete expansion of chest walls; dulness in lower third of each, and no respiratory movements here.

Tongue moist, slightly coated; bowels generally confined; dyspnœa sweats occasionally:

Diagnosis.—Mr. Mac Cormac considered this to be a pure case of lymphadenoma, there being hyperplasia of glandular elements, as evinced by their increased size in the situation of normal gland structure. The disease was constitutional, but was not symmetrical on the opposite sides of the body.

December 27th.—Loss of flesh since admission; appetite bad; all the tumours have enlarged; prefers sitting up in bed, although breathing not distressed. Needles were attached to the galvanic battery, and the axillary tumours punctured by Mr. Mac Cormac;

great pain on puncture. This was not attended by any beneficial effect.

January 29th.—No improvement in local or constitutional condition; increasing emaciation; a full eruption of psoriasis on chest and abdomen, which has been increasing for the last three days; no increase of temperature; no sickness; has been taking Syr. Ferri Iod. ʒij, b. d. and quinine.

The temperature, taken daily, was hardly ever above 99°.

February 6th.—Much weaker; takes food badly; radial pulse weak; increased dyspnœa; dulness over greater part of left chest.

11th.—Died.

Post mortem fourteen hours after death, by Dr. Greenfield.—Body much emaciated; much swelling and œdema of both legs and scrotum; left lower limb more swollen than right.

Over the front of the chest were two rounded masses, which extended over the middle and upper parts of the sternum and the rib cartilages on the left side, the larger measuring 4 inches in width, the upper smaller one about 2½ inches, each projecting from the surface about 1½ inch. On removal of the skin these masses were found to be covered by the subcutaneous fat, but they invaded the pectoralis major muscle. The tumours were much as described during life, and did not appear to have undergone any degenerative change. The growth extended inwards between the rib cartilages, and formed a tumour on the inner surface of the anterior thoracic cell corresponding with that seen externally. It appeared to invade the sternum, and penetrate it, but on careful examination this did not prove really to be the case.

A mass of new growth, the size of an orange, was seen situated above the heart, crossing the right auricle, and compressing the vena cava superior so as to diminish its calibre; this also was close to, but did not appear to compress, the ascending aorta. It reached as high as the first rib, but did not enter the neck. All the glands in the anterior mediastinum were greatly enlarged and confluent into irregular masses, continuous here and there with the external tumours.

In the posterior mediastinum a small mass of the growth, but no general enlargement of the glands in that situation. The glands at the bifurcation of the trachea were not at all enlarged, and no pressure on the trachea or bronchi in either situation could be dis-

covered. Bronchial glands generally free from enlargement. On section they were of black colour, and small white dots in some scattered through their substance.

The right pleura contained six pints, the left seven pints, of blood-stained serum. In the left pleura was seen irregular infiltration continuous from the mass in the anterior mediastinum, apparently by the lymphatics. The growth closely resembled the gutterings of a tallow candle on the parietal pleura.

Right lung weighed 25 oz., left 13 oz.; both, but especially left, much collapsed from pressure of pleuritic fluid; no new growth.

Over the heads of some of the ribs were small masses of new growth, which appeared to involve the periosteum and the subpleural tissues.

A large mass of new growth occupied the left groin and Scarpa's triangle, and extended into the abdomen, forming a large, irregularly-rounded tumour, which partly filled the left iliac fossa, and nearly the whole of the pelvic cavity, the rectum being pushed against its right wall; the bladder much compressed. The glands along the left iliac vessels and the lumbar retro-peritoneal glands were enormously enlarged, forming a continuous mass, which projected on each side and in front of the spine, and was from two to three inches in thickness. The abdominal aorta was completely surrounded and compressed by the growth, and its wall indistinguishable from the mass; but its inner coat was free from infiltration.

The vena cava inferior was displaced and separated from the aorta for a considerable part of its course by a distance of nearly an inch, being stretched over a part of the mass; its walls appeared to be infiltrated, and at one or two points there was obvious infiltration extending nearly into the interior, the inner coat of the vessel being elevated and discoloured.

The glands in right groin almost free from enlargement.

Mesenteric glands entirely unaffected, and of normal size.

The masses of new growth presented for the most part similar appearances everywhere. Most of them were somewhat soft and elastic, though some in the groin were firmer and harder. On section, they were of pinkish colour, very vascular, resembling "medullary" cancer, and readily broken down. There were no blood cysts. In some parts the outline of enlarged glands could be recognised by a thin fibrous capsule, but for the most part they were completely confluent, and no intervening infiltration could be discovered.

Pericardium normal; heart weighed 8 oz., normal. The arch of aorta free from compression, but the left carotid artery passed through a mass of new growth.

Liver.—3 lb. 13 oz., firm; no change.

Spleen.—Weighed 25 oz., of very large size, measuring 8 by 4 by 2 in., firm, of dark colour. Malpighian corpuscles very prominent, but no other obvious morbid change.

Kidneys.—11 oz., slightly granular, otherwise normal; supra-renal capsules normal.

Brain.—Normal.

CASE 5.—*Lymphadenoma of cervical glands; infiltration of omentum and peritoneum.*

Edward P—, æt. 33, a gardener, living at Catford, was admitted into Arthur Ward, under Dr. Murchison's care, on April 26th, 1877.

Family history.—His father died æt. 43; mother alive, æt. 54, healthy; six brothers and sisters, all healthy.

Patient had had measles and hooping-cough, but not scarlet fever. Never had any illness since childhood. Always a moderate drinker. Has had a rupture for three years, for which he has worn a truss.

About twelve months ago he noticed a small hard lump under the left ear, which has gradually enlarged by similar lumps appearing along the jaw, these remaining separate until the beginning of his present illness (he says), when in the course of a few days they coalesced; since then the swelling has not increased much. They have never been painful, and never interfered with the movement of the jaw.

The present illness for which he sought admission was as follows:—About a month or six weeks ago he had been feeling unwell, being languid and tired, with lassitude and fatigue on exertion. He came up to town on March 20th to be fitted with a new truss, and apparently in consequence of the rupture coming down he had, after walking, great pain in the loins, going through to the stomach. He had had occasional twinges of this pain before, but now it gradually grew worse, and has persisted ever since. He has had some cough, with slight occasional expectoration; has had heartburn since the beginning of the illness; always felt worse at night; has never slept well since the commencement of the illness, and has been getting thinner.

He has, moreover, had a constant desire to pass water, but never passed much at a time. Bowels have been much confined, never any diarrhœa. He seems to have suffered much from flatulence, causing great pain and distension of the abdomen, which was, however, relieved by aperients.

On admission.—Patient a well-nourished and developed man; capillaries of throat are somewhat dilated. Lies on his back.

There is a large glandular mass on the left side of the inferior maxillary bone, also on that side of the neck extending from the ear to the median line of the chin below, the hinder swelling arising from behind the ear, and reaching to almost an inch above the clavicle. Both are lobular and elastic. The glands above the clavicle are slightly enlarged. Tongue clean, reddish at edges, indented at margin; appetite good; complains of heartburn and flatulence; bowels open twice yesterday, motion loose. Abdomen enlarged and tense, abdominal walls shining; the flanks do not markedly bulge, but abdomen is prominent in front. Percussion tympanitic in front, dull in flanks, becoming resonant on change of position; abdomen not tender; suffers no pain, except that referred to the truss. Liver and spleen somewhat enlarged; no enlargement of superficial abdominal veins. Micturition and defæcation normal.

No œdema of legs. Dulness and absence of breath and voice sounds, and vocal fremitus over lower half of left lung behind. Respirations 24, easy; slight cough; no expectoration. Heart sounds dull; no murmur. Slight headache. Pupils equal. Blood examined with microscope, no excess of white corpuscles. Urine turbid, 1034, acid, abundant lithates; a trace of albumen.

April 28th.—Ordered Pot. Iod. gr. v, Syr. Ferri Iod. ♏xx, Tr. Digit. ♏x, ex Aq., t. d. s., Lin. Hydrarg. ʒj, Ext. Bellad. ʒss, Glycerini ʒiiss, to be applied constantly to the abdomen.

The right pleura became affected and the patient became weaker and thinner, complaining at the last of pain in the abdomen and sickness. He died on May 8th, 1877.

				Degrees.		Degrees.
Temperature—	April	26,	p.m.,	100·8.		
„	„	27,	a.m.,	101·2.	p.m.	99·4.
„	„	28,	„	98·6.	„	100·0.
„	„	29,	„	99·2.	„	99·8.
„	„	30,	„	99·6.		
„	May	1,	...	...	„	100·8.
„	„	2,	„	98·0.	„	99·4.
„	„	4,	„	98·8.		
„	„	5,	„	99·8.	„	100·4.
„	„	6,	...	...	„	100·6.
„	„	7,	„	103·8.	„	100·2.
„	„	8,	„	100·2.		

Examination twenty-one hours after death.—Weather warm. Body somewhat emaciated. Rigor mortis marked in lower, absent in upper limbs. No anasarca.

Beneath left ramus of jaw a mass of enlarged glands, extending nearly to middle line, about the size of an orange, the glandular mass reaching back as far as the angle of the jaw, and also downwards in the neck, chiefly in posterior triangle, at its hinder part. Mass not adherent to skin. No discoloration.

This mass was found to be made up by three or four large glands the size of walnuts, and some other smaller ones. The enlarged glands were rounded, not coherent, capsules not thickened. They were firm, semi-elastic, one or two of the smaller ones very hard; on section they presented a somewhat vascular cerebriform appearance, were of pinkish-white colour mottled with patches of red, and a few scattered yellowish dots. No indication of any commencement in separate centres. The smaller glands more vascular. On scraping, a very scanty creamy juice from some of the softer parts.

Glands beneath sterno-mastoid and in posterior triangle of neck on left side, as low as clavicle, also considerably enlarged, forming a mass equal in size to that beneath ramus of jaw. Some of these glands almost coherent, but in no place actually so. No enlargement whatever of glands on right side of neck or in either axilla. Glands in mediastinum also entirely free from enlargement, and so also of those in groins.

Mouth, tongue, pharynx, larynx, trachea, and œsophagus carefully examined, and found to be entirely free from signs of disease.

Pleuræ.—Right pleura contained about one pint, left 1½ pint of fluid, turbid, slightly stained with blood. No sign of inflammation of serous membrane.

Studding the visceral and parietal pleuræ on both sides were very numerous small flattened flakes of new growth, mostly less than ¼ inch in width, closely resembling in appearance the corpora amylacea of the spinal meninges, in some places confluent. They could be scraped off, leaving the pleura, apparently normal, beneath them. They were something like small drops of wax which had fallen on the surface.

In addition to these, on the parietal, and especially the diaphragmatic surface, were very numerous minute nodules of new growth, somewhat resembling tubercular granulations.

Lungs.—Right, 1 lb. 3 oz.; left, 1 lb. 5 oz. Both, but especially left, somewhat compressed and collapsed in lower lobe, which on section appeared congested, but some of this probably due to decomposition. No new growth in lungs.

Pericardium.—A few minute points of new growth on diaphragmatic surface.

Heart.—8 oz.; normal size; valves normal; walls not wasted; those of left ventricle firmly contracted.

Peritoneum.—Contained nearly 12 pints of very turbid yellowish fluid. Throughout its entire extent the serous membrane studded with minute nodules of new growth. Omentum greatly thickened, forming an irregular mass, of purplish-white colour, which on section appears to be made up of an infinite number of minute rounded nodules closely packed together.

Over the diaphragm and liver and some parts of parietal layer the new growth formed a smooth uniform layer, about half a line in thickness. On the surface of the small intestine, except close to mesenteric border, the nodules very minute, translucent scattered pearly grains.

Mesenteric glands free from enlargement.

Glands in hilus of liver and neighbourhood of portal vein also free from enlargement, only one or two small soft glands being found. Portal vein free from obstruction.

Pancreas.—Normal.

Suprarenals.—Normal.

Liver.—4lb. 8oz., rather small and wasted, otherwise normal and free from new growth.

Spleen.—6 oz. Somewhat enlarged, but not considerably. On section of uniform colour, vascular, soft, and friable, but entirely free from signs of other change.

Kidneys.—11 oz., rather wasted, otherwise normal.

Stomach and intestines, including lower end of rectum, carefully examined and found to be healthy throughout.

Testes, &c.—Normal.

Brain, &c.—3 lbs. 5 oz., quite healthy in appearance throughout.

Microscopical examination of a fresh section from the infiltrated omentum, stained with logwood, showed it to be made up almost entirely of small round cells and spindle cells forming bands through the growth, which appeared in all respects to correspond to lymphosarcoma.

Microscopic examination of the different organs.—It will be well to group together the appearances in the several organs in different cases, and to describe not only those seen in these cases, but in some others to which reference will be made.

Lymphatic glands.—In all five cases the change in the glands was the same in kind, though it differed in degree, in different cases and in the various glands from the same case. It consisted essentially in a sort of chronic inflammation involving especially the fibrous stroma of the gland, which became thickened and gradually obliterated entirely the interstices, so that the gland became a mass of dense, tough, fibrous tissue, with little or no trace of adenoid structure. In the early stages (seen best in Case 3, and in the glands of E. K—, 'Path. Trans.,' vol. xxvii, p. 275) there was some general enlargement of the glands, the fibrous stroma appeared coarser, and there were a large number of multinucleated cells adherent to the trabeculæ, well seen on washing away the lymph cells. These multinucleated cells, containing from four to eight or twelve nuclei, were often collected in clusters in the parts of the gland especially where the fibrous change was progressing (see Pl. XIII, fig. 2.) In all the cases from which glands were examined the changes were of the same character—a progressive fibroid induration, with destruction of the proper glandular structure, this being the case even where the glands appeared to be swollen, vascular and elastic (as in Case 3); in some of these the various stages of the process could be traced in the same gland. In some cases all the glands examined had become completely fibrous, their microscopic appearance bearing a close resemblance to that of cicatricial tissue. This was so in Case 2, and another recorded in 'Trans. Clin. Soc.,' vol. x, p. 43; in the former, glands from different parts of the body bore this character.

DESCRIPTION OF PLATE XIII.

The figures in this plate illustrate Dr. Greenfield's Specimens of Lymphadenoma. (Page 272.) From drawings by himself.

FIG. 1.—Section from the spleen (Case 2), to show shape and relations of masses of new growth. Low power.

a. Masses of new growth. *b*. Unaffected splenic pulp. *c*. Artery.

FIG. 2.—Section from lymphatic gland. ($\frac{1}{4}$ in. obj).

FIG. 3.—Infiltrated omentum from Case 5 (Hartnack, 7 × 3, tube out.)

FIG. 4.—Section from the liver showing capillary network close to infiltrating new growth. *a*. Swollen protoplasmic masses in interior of capillaries. *b*. Liver cells undergoing fatty degeneration producing spurious vacuolation. (7 × 3, tube out).

Fig 1

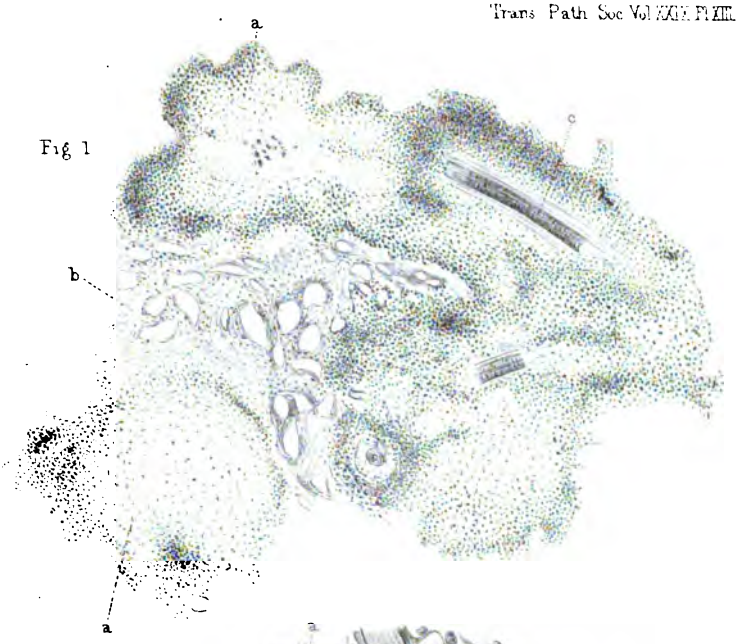

Fig 2.

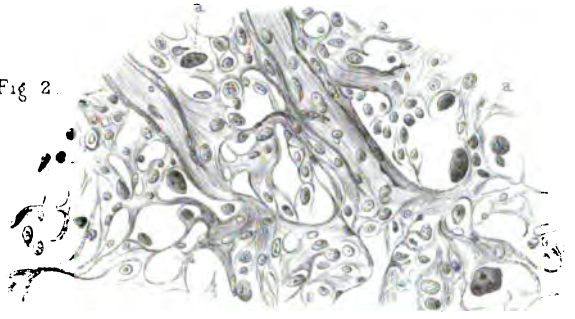

Fig 4

Fig. 3.

In one case only (Case 5) the glands were less fibrous, and had the appearance of actual exuberant overgrowth of all the glandular elements, but this was not seen everywhere.

Spleen.—In these five cases the naked-eye condition of the spleen varied considerably. In Case 1 there was the typical enlargement, with deposit of new growth, like lumps of suet, which have been so well described by Dr. Wilks. It is noteworthy that this growth occurred in a very regular manner, distinctly infiltrating the organ from certain definite centres near the hilus, from which it grew inwards in a branching, tree-like manner, becoming indurated and more fibrous in the older parts. The greater part of the organ showed great swelling and vascularity of the pulp, with here and there small translucent yellowish patches, which microscopic examination showed to be of the same structure as the other new growth in an earlier stage.

Case 2 also presented a rather typical form of the new growth, which seemed to invade it everywhere, and was seen as small rounded or branching masses of pale yellowish, waxy appearance on a dark red ground, together with small patches, which were more opaque-yellow, and resembled caseous masses.

Case 3 showed also typical affection of the spleen.

In Case 4 the organ was greatly enlarged, weighing 25 oz., was of very dark colour, firm, but without new growth.

In three other cases which have come under my observation the spleen was affected in one or other of these ways in all. In one case it was enlarged and contained nodular masses of lymphadenoma; in the second ('Path. Trans.,' vol. xxvii, p. 275) it was greatly enlarged, of deep-red colour, firm, but with no enlargement of the Malpighian corpuscles and no patches of infiltration; in the third ('Clin. Trans.,' vol. x) it contained some infiltration. So that out of eight cases which have fallen under my notice the spleen showed the typical infiltration in four, nodular growth in one, great enlargement and simple hypertrophy in two, and was unaffected in one.

Microscopic examination.—In advanced cases (Burgess, Macintosh), where the typical infiltration occurs, one is met by the same difficulty as in the lymphatic glands.

The normal structure of the organ in the affected parts appears to be entirely lost; it is everywhere traversed by irregular broad bands of fibrous tissue, which in many parts look as much like sections of tendon as anything. These bands are very irregular in thickness; near their edges they often present very marked pigmen-

tation—in the form of rows of clustered black granules. At their edges and in the small spaces left between them are seen cells of various sizes, massed together, a good many large multinucleated cells being amongst them. Here and there is a small patch of splenic pulp left intact.

By studying the earlier stages (Cases 2 and 3) one sees how this change comes about.

Under a low power.—The spleen tissue is seen to be occupied here and there either by rounded masses or elongated branching areas, which towards the centre consist of nearly amorphous fibrous tissue and at the margins of a new cellular growth, and towards the centre of each of these masses is seen an artery, which it surrounds (Pl. XIII, fig. 1).

With a higher power we find that the fibrous mass is formed by the rapid induration of a lymphatic tissue growing around the vessels, in fact, in the situation of the proper adenoid tissue of the spleen, that this extends into the so-called splenic pulp, leading to its destruction. The mode of induration is seen in the rough sketch shown which represents one of the bands at its edge.

Pigmentation does not seem to occur in quite the earliest stages; it appears to result later, when the vascular plexus is in large measure destroyed, and the red corpuscles entangled, and undergoing gradual changes into hæmatoidin.

The change in the spleen is then essentially an overgrowth or new growth of adenoid tissue commencing in the normal lymphatic tissue of the organs, manifesting the same tendency to fibrosis as elsewhere, and invading and destroying the vascular plexus.

The growths in the *liver* in Case 2 had a similar structure to those elsewhere, but they had some special relations to the tissues. In all the nodular growths in this case and that of E. Smith, there was a marked tendency to caseation, especially in those towards the surface of the organ. The lymphatic new growth appeared to start in the portal canals, as small masses which extended around and into the lobules, the liver cells becoming degenerated and shrivelling. Two points were especially observed in the growth in the liver. One was the apparent extension along the walls of the capillaries into the lobules. In the neighbourhood of the nodules of new growth the nuclei of the capillaries were observed to be swollen to a remarkable degree (see Plate XIII., fig. 4), forming masses of protoplasm *a* which nearly filled their channels, these containing sometimes two or three

nuclei. Another point observed was that the liver cells presented marked degeneration, and when prepared in the usual way showed all the characters which have been described as vacuolation, but no evidence could be gained of their transformation into the new growth.

In the infiltration in the *omentum* in Case 5 some characters were observed which differed considerably from those seen elsewhere. Under a low power the mass of infiltration was seen to be made up of more or less rounded nodules, about 1 millimètre in diameter, closely packed together, indeed, in many respects resembling tubercular infiltration of the peritoneum, for in some of the nodules the centres were distinctly caseous. With a higher power the most remarkable point was the large size of many of the cells occupying the meshes of the stroma, as seen in the drawing (Plate XIII., fig. 3), many of them being masses of protoplasm, with several nuclei, undergoing a process of division. The growth, however, had a distinctly adenoid character, though approaching the sarcomatous type, and was very similar to that seen in the lungs in one case (E. K—, 'Clin. Trans.,' vol. x). It is possible that the situation of the growth and the ready reaction of the peritoneum to the morbid influence may account for this exuberant character. The case is perhaps less typically one of lymphadenoma than the others, and establishes a transition to lympho-sarcoma.

The blood.—In all the five cases of typical lymphadenoma here shown, the blood was examined, and no increase whatever of leucocytes observed. This is in accordance with my experience in nearly all the typical cases which I have examined. In five other cases, four under my own care, in which I have had opportunities of examining the blood carefully, in four there was no increase whatever above the normal, in one there was a slight increase ('Clin. Trans.,' vol. x, p. 51), which at the time I thought important, but I have since repeatedly seen a far greater number in febrile disorders, so that, so far as my own experience in ten cases is concerned, I have no ground for believing in the presence of leucocyæthmia in typical cases of Hodgkin's disease.

The characters of the red and white corpuscles have generally been natural, except that in some there have been the usual features of anæmic blood. Some of the white corpuscles in two cases had peculiar characters; either some were smaller than natural and had a sort of ring in the centre, as if they were vacuolated, or some were very translucent, not granular, as usual, and had a nucleus at one side.

But these characters may be observed in other conditions of the blood, possibly even of healthy persons, and are not in any way special to the disease.

In three cases microcytes were seen, but only at the periods of high fever.

I bring these facts before the Society simply as a contribution to the statistics of the pathology of lymphadenoma, and not by any means as attempting to ground any absolute dicta upon them. I am quite aware that well-authenticated cases of so-called leukæmia lymphatica are on record, and that there are cases which seem to establish a transition between lymphadenoma and leucocythæmia. But many of the cases are open to criticism, and I do not think that we ought so readily to give up the view that the diseases are clinically and to a great extent pathologically distinct. One criticism (to which also many observations in lymphadenoma are open) is that the blood has only been examined on one or two occasions, and at different stages of the disease, and until we have more complete continuous observation at various stages we cannot be sure that there is not from time to time a great increase of white corpuscles, which yet imprints no clinical character upon the disease.

When speaking of leucocythæmia, I shall endeavour to show that there is no sufficient evidence that the change in the lymphatic glands when they are enlarged in leucocythæmia is of the nature as that in Hodgkin's disease; and that the so called leucocythæmic *growths* in organs are essentially different.

Varieties of lymphadenoma.—It is I think essential to state my belief that the term "lymphadenoma" ought to be limited to the description of the nature of the growth, and not used as a clinical term. For there appear to be such great differences both in the essential nature and in the clinical course of cases, which have as their common factor the presence of growths of glandular type, that we must recognise a distinction in their real character. All the cases which I here relate (possibly with the exception of Case 5) come into the class to which I should limit the term "Hodgkin's disease," using it as a clinical designation. Local lymphatic tumours, not infective except locally; cancerous lymphatic tumours, growing like cancer and running its clinical course, and tumours of organs of lymphatic type do not seem to me to be really at all the same disease as that seen in these cases. But the line of demarcation is, it must be allowed, a very difficult one to draw, and the essential

distinction seems to lie in the constitutional implication in the cases of "Hodgkin's disease" or adénie.

It is not necessary here to discuss these points further. I shall here only briefly state some conclusions as to the nature of lymphadenoma, derived from observation of these cases.

Morbid anatomy and histology.—That at first it is an essentially local disease, consisting in an irritative overgrowth of some normal lymphatic glandular tissue, which becomes infective, leading to similar implication of adjacent glands, and thence spreading to more distant ones, usually by contiguity. Clinically and anatomically, there is little distinction at this stage from cancer, and it may be regarded as lymphatic cancer, especially when, as later, it invades other structures, preferably serous membranes and the connective tissue of vascular organs.

The growth has an essential tendency to induration, converting the glands and the new growths into fibrous tissue; caseation is also of frequent occurrence, both in the glands and the new growth.

The process in the glands, though progressive when once well established, has periods of intermission. There is often considerable enlargement at repeated intervals, followed by rapid subsidence of the swelling, this enlargement being due to attacks of subacute inflammation. A part of the diminution may probably be ascribed to fibrous induration.

When the disease begins in the lymphatic glands of the neck the spleen is, in nearly all cases, sooner or later involved. The affection of the spleen in typical cases consists in a growth of lymphoid tissue around the vessels, often extending in a continuous manner along them; the growth probably starts in the adenoid tissue normally found in that situation; it tends to undergo rapid fibroid induration, and leads to a great obstruction to the circulation in the organ.

The affection of the spleen varies much in degree; in some cases a direct continuity from adjacen glands is traceable; in others no such continuity can be traced.

The character of the splenic affection is usually that described by Hodgkin and Wilks; but in some cases—and it is noteworthy that these were the two in which the disease began in the groin—there was only very great enlargement of the spleen, with no obvious increase of the adenoid tissue.

Clinically the disease, when well marked, exhibits an irregular febrile course, periods of latency and of progress; a marked and peculiar anæmia.

The fever is to be observed in nearly all cases if the temperature be carefully watched. In the earlier periods it is slight, occasional, and fluctuating; but in the cachectic stage it tends to be high and of irregular hectic type, sometimes with very definite intermissions.

In some cases (four seen) there are attacks of fever of agueish type, with rigor, hot and sweating stages; and these are sometimes distinctly associated with a peculiar change in the colour of the skin, and with swelling and tenderness of glands. I have brought before the Society charts of the temperature in four cases, which show well this febrile course.

The *blood* presents the characters of anæmic blood: deficiency of normal red corpuscles, defective power of coagulation. There are also present occasionally (in two cases) microcytes.

The white corpuscles are often in diminished number, the proportion to the red being maintained; in some cases they are increased in number relatively, but their proportion does not usually exceed that seen in many other febrile and wasting diseases, nor is it a constant phenomenon. Moreover, the white corpuscles present none of the altered characters which are seen in leucocythæmia, nor any changes other than those commonly seen in other fevers.

In none of the cases has any tendency to hæmorrhage been observed, nor have any extravasations of leucocytes been found in any of the cases, such as are found in leucocythæmia. The specimens from the following case are shown by way of contrast:—

Leucocythæmia with multiple hæmorrhages and infiltration of the liver and kidneys.—Rosa M. P—, æt. 4½, admitted on February 3rd, 1877, under the care of Dr. Bristowe (to whom I am indebted for the use of the case). The following notes were made by Dr. Sharkey, the resident assistant physician, on February 4th:—The child cut its first tooth at thirteen months old; before that was very languid and had continued diarrhœa. She was weaned at seven or eight months, and grew very thin afterwards. Had measles two years ago, and ten months ago had bronchitis and hooping-cough; the latter she has only lately lost, but had been well and at school till twelve days before admission. Ten days ago her mother made her some new aprons, and found that they would not go round her, and she observed some enlargement of the abdomen. The child had been perfectly well, but for low spirits, during the previous week. This week has been very restless and weak, and had large bruise-like spots appearing on the limbs, some of which are

still present. She has complained of pains in the ankles and fingers; has become very much paler, and the face has swelled. Yesterday morning the motions were slightly blood-streaked. Bowels regular lately, but she has not passed much water.

The mother is twenty-five years old, quite healthy; has three children, and has not had any miscarriages. One child died of "inflammation" at three months. Father thirty, suffers from "indigestion."

The child is large and big bellied, no œdema, very pale; there are purpuric spots on the limbs, some the size of a sixpence. Tongue clean, pale; nose flattened at bridge, hair dark. Slight cough; urine gives a copious precipitate of lithates, no albumen. Blood contains an excess of white cells of moderate size; the number varies greatly in different parts of the field, sometimes not markedly increased, in others more than 100 in the field of No. 7 objective Hartnack, with No. 3 eye-piece.

Liver and spleen both very large; edge of liver hard, irregular; surface smooth. The notch both in liver and spleen distinctly felt. No anæmic murmur.

February 7th.—There are still large purpuric spots, ill-defined, of blueish colour, over the legs and arms.

14th.—Is very drowsy; excessively pale, like wax; irritable and feverish; skin puffy; coughs a good deal.

17th.—Vomiting, rapid breathing, drowsy, face more puffy. Patient died of gradual asthenia at 8.5 p.m.

It was elicited from the father by Dr. Leeson, the house surgeon, that he had had syphilis, that the mother had suffered from sore throat before the child was born, her hair came out, and she had spots all over the body. The child had snuffles soon after its birth, and there were many spots about the buttocks and body, which lasted three weeks.

From the time of admission till February 12th the temperature was either normal or subnormal; it was not taken subsequently.

Post-mortem forty-eight hours after death.—Weather cold; body of well-developed and apparently fairly nourished child.

On both lower limbs and on lower part of abdomen were some irregular dark purplish-red blotches, of the size of a fourpenny-piece or less, apparently due to deeply seated ecchymosis. Some smaller scattered petechiæ, especially marked about vulva. No other sign of skin eruption or ulceration to be detected. On cutting into these

patches the subcutaneous fat presented a mottled staining, as from hæmorrhage, in its deeper part, the condition extending through its whole depth, and not affecting solely the superficial parts especially.

Abdomen.—No fluid in peritoneal cavity; liver greatly enlarged, extending downwards below the umbilicus.

Pleuræ.—Normal, with the exception of one loose fibrous band between the right middle lobe and costal wall.

The *pericardium* contained about 1 oz. of turbid serum; no distinct blood nor lymph exudation. Parietal layer normal; visceral with intense mottled injection and ecchymosis, especially over anterior surface (which resembled the shell of a boiled lobster). No roughening of serous layer, though some loss of glistening.

Lungs.—Right 8 oz., left 7 oz. Both with numerous superficial patches of collapse and some of ecchymosis. On section both very œdematous, with a mingling of mottled patches of collapse, slight congestion and œdema, with here and there some ecchymosis, and a few larger patches of hæmorrhage into the air cells, and slight surrounding pneumonic infiltration.

The *larynx*, *trachea*, and *mediastinal glands* normal.

Heart.—2 oz. Vivid injection and some ecchymosis of superficial layer of heart wall, especially of left ventricle, to a depth of about a line. Scattered ecchymoses throughout walls, one or two of minute size beneath endocardium. Coagula in heart somewhat pale, but otherwise normal; valves, &c., healthy.

Liver.—2 lb. 5 oz., somewhat but not greatly enlarged; the enlargement uniform. Surface smooth, with entire absence of puckered cicatrices or of local swellings; capsule not thickened; generally translucent. Tissue generally firm.

On section the characters uniform throughout, consisting in an irregular veining of pearly white colour, forming small branching bands, apparently corresponding precisely with the interlobular divisions of the portal canals, small spots of slightly greenish-yellow colour, forming apparently the centres of the lobules, and an intermediate zone of pale brownish colour; the whole very anæmic. No thickening of tissue in hilus. Gall-bladder normal. Glands in neighbourhood of hilus normal.

Spleen.—6½ oz., enlarged, of elongated ovoid shape, flattened Notch not perceptible. The organ measured 5½ inches in maximum length, 2 inches in width, and about 1 in thickness; it was firm, of

rather light red colour. On the outer surface towards its lower half was a large irregular patch of thickening of the capsule, of yellow colour and translucent waxy appearance. It measured about 1½ inches in diameter, but was irregular and branching, and of uneven thickness, the thickest part about 2½ millimètres. On cutting into the organ delicate white fibrous striæ were seen running inwards from it in a radial manner into the splenic tissue, penetrating to about one third of an inch.

The substance of the organ generally firm, somewhat fleshy, uniform in colour and consistence, of reddish-pink colour (resembling anæmic muscle). No Malpighian corpuscles visible. The pulp could not be squeezed out. No staining whatever with iodine solution.

Stomach.—Mucous membrane with some signs of catarrh, extending also into duodenum. A few scattered ecchymoses in submucous tissue.

Intestines.—Normal throughout. Entirely free from signs of any hæmorrhage. Contents normal pale fæces.

Kidneys.—Right 5¾ oz., left 5½ oz. Both considerably enlarged, of somewhat irregular shape, extending to a much greater length along sides of spine than usual. Before separating the capsules they appeared to be pale, covered with large purple blotches. Capsule readily stripped off, a thin layer of coagulated blood separating it in some parts from subjacent cortex where infiltrated with blood. Surface of cortex smooth, covered with large irregular blotches of deep-red colour, some half an inch in diameter, others smaller; the intervening tissue of pale dead-white colour. Some of these hæmorrhagic blotches very slightly raised, but the majority not so.

On cutting through the organ, similar patches of intense congestion and hæmorrhage were found scattered throughout the cortical substance. Those appearing on the surface of the organ were seen to be the bases of more or less conical tracts of the cortex, penetrating through half, and in some places through the entire, cortex In addition to these, around the bases of the pyramids were grouped radiating tracts or bands of hæmorrhage which ran in lines from the bases of the pyramids into the cortex for a variable distance, and thus formed a sort of aureole to the pyramids, giving a very peculiar and striking appearance. No hæmorrhage into the medullary portion itself. In addition to these were some scattered ecchymoses of varying size. No hæmorrhage into pelvis or calyces.

Bladder somewhat distended, containing 6 oz. of clear pale urine. Bladder and ureters normal. Vessels of kidney apparently normal.

Supra-renal capsules rather small; normal.

Pancreas appeared normal.

Brain.—2 lbs. 8½ oz. Membranes normal, but remarkably anæmic. Substance of brain extremely anæmic, rather soft, but otherwise normal.

Microscopic examination of liver, kidneys, spleen, and heart.—Liver.—On examining sections stained in logwood under a low power (2 inch), a uniform deeply-stained network was seen, formed by infiltration around the lobules, and more or less invading their structure, the central half of each lobule remaining unaffected and the central vein clear. With higher powers this condition was found to be due to an infiltration of the portal spaces and fissures with leucocytes, which formed great masses around the branches of the portal vein and penetrated into the fissures, and to a certain extent into the substance of the lobules, the liver cells being either pushed aside or atrophied and destroyed. The infiltration was everywhere most abundant around the vessels, and along some of the capillaries: running towards the centre of the lobules, were seen here and there aggregations of leucocytes. These cells when examined with the highest powers appeared nearly uniform in shape and character, when unstained they exactly resembled outwandered leucocytes, and no distinct stroma, except a small quantity of finely filamentous unorganized substance, apparently coagulated fibrin, could be found in it (see Plate XIV, fig. 3.) There was no trace of an adenoid structure in the infiltration. The liver cells preserved in other respects their normal character.

Kidneys.—Sections from the cortical substance of the kidneys presented similar appearances to those of the liver (Plate XIV, figs. 1 and 2.) Nearly everywhere the convoluted tubes were separated by masses of leucocytes either in distended capillaries or outside their walls; in some parts the tubes were quite isolated, like islands, in a sea of leucocytes. The exudation was most abundant in the neighbourhood of the glomeruli in many parts, but did not occur within the capsules. The renal tubules were apparently healthy in nearly every part. Along the vessels in the medullary portion a similar impaction and outwandering of leucocytes was visible. No sign of stroma or of adenoid structure.

Heart.—Sections of the heart stained with logwood showed very

DESCRIPTION OF PLATE XIV.

PLATE XIV further illustrates Dr. Greenfield's Specimens of Lymphadenoma. (Page 272.)

FIG. 1.—Kidney; section of cortex parallel to the surface. (1 in. obj.) Drawn by Mr. F. T. Blight.

aa. Tracts around vessels and glomeruli infiltrated with leucocytes.

FIG. 2.—Section of kidney from case of leucocythemia. Section of cortex parallel to surface, showing infiltration with leucocytes which separate the tubules. ($\frac{1}{4}$ in. obj.)

FIG. 3.—Sections of liver from case of leucocythemia, showing infiltrations with leucocytes and delicate network of coagulated fibrin.

FIG. 4.—Heart from case of leucocythemia shows masses of leucocytes separating fibres. (1 inch.) Drawn by Mr. F. T. Blight.

Fig 1



Fig 2



Fig 3

Fig 4



beautifully the small capillary impactions and exudation of leucocytes. The muscular fibres were somewhat readily torn apart, the nuclei of the sarcolemma unusually distinct. At intervals were seen small vessels filled with leucocytes and a cluster of leucocytes around them, forming something like a miliary abscess (see Plate XIV, fig. 4.)

Spleen.—The microscopic examination of the spleen showed no special characters differing at all from the normal.

I should add that the very beautiful microscopic specimens of the heart and spleen in this case exhibited to the Society, and from which the drawings were made, were kindly prepared for me by my friend Mr. T. D. Acland.

It thus appears that all the morbid changes observed in this case were due simply to accumulation of leucocytes within and around the vessels, the latter either due to rupture of vessels or simple emigration.

A comparison of the liver in this case with that of Case 2, of lymphadenoma, showed the very striking difference between the new adenoid growth in the latter and the simple exudation of leucocytes in the former.

I shall briefly summarise the distinctions which are found between lymphadenoma and leucocythæmia.

The changes in the organs are essentially distinct.

In leucocythæmia there is excessive and abnormal production of white blood-corpuscles, which tend to form impaction in the capillaries, to wander out amongst the components especially of the vascular organs, as the liver and kidneys, and to give rise in this way to hæmorrhages.

The so-called "growths" in leucocythæmia are probably nothing more than such collections of outwandered leucocytes, having no organization, and such "stroma" as they show is only coagulated fibrin and the normal connective tissue of the part.

In lymphadenoma the growth is from the outset markedly adenoid, the stroma tends to be coarse, the cells well formed, large, and in many parts multinucleated.

The association of leucocythæmia with glandular enlargement may probably take place, though in rare cases, in two ways; the one by the enlargement of the gland through impaction with leucocytes, the other a true lymphatic leucocythæmia, in which there is excessive production of cells in the lymphatic glands, but this is a dis-

tinct process from that in lymphadenoma, and runs a different course.

The affection of the spleen in leucocythæmia varies a good deal. In the cases which I have examined there has been little change beyond one of a truly hypertrophic nature; in none anything at all like lymphadenoma.

The clinical course is quite different—the etiology, symptoms, duration, prognosis, and the occurrence of hæmorrhages.

Hence, though not denying the existence of a "lymphatic leucocythæmia," I believe that many cases are cases of malobservation and incorrect inference; that there is no ground for regarding lymphadenoma and leucocythæmia as identical, or as any more closely related than is necessitated by the fact that they both involve the lymphatic and blood system. There are closer relations of lymphadenoma with tubercle on the one hand, and cancer and sarcoma on the other than with leucocythæmia.

March 19*th*, 1878.

---

3. *Observations on specimens illustrating lymphatic diseases.*

By W. R. Gowers, M.D.

I have brought forward two patients suffering from lymphadenoma, and also a series of sections illustrating some points in the pathology of the splenic, glandular, and visceral changes in splenic leucocythæmia and in Hodgkin's disease.

One of the patients is a man, aged 36, who is suffering from enlargement of the glands on both sides of the neck and both axillæ. From above the right clavicle a large mass descends in front of the clavicle. Until a year and a half ago he was well, and no circumstance in his past history can be regarded as, in any degree, the cause of the growth which now exists. A year and a half ago the glands above the right clavicle began to enlarge, and as they increased in size, the mass they formed descended in front of the clavicle. Six month ago the glands in the left side of the neck began to enlarge, and about the same time the glands in each axilla. He is, as you see, a stout well-built man, in the prime of life. In front of the right clavicle, the upper part of the sternum, and the adjacent rib cartilages, is a large lobulated tumour, about the size of a cocoa-nut. It feels as if

formed by a number of glands fused together. The whole mass is freely movable, the upper limit is in the root of the neck, and it appears to extend rather deeply above the sternum. Other glands, about the size of walnuts, lie in the posterior triangle, and others of somewhat smaller size are situated below the jaw on each side and in the left posterior triangle. Still smaller glands occupy each axilla. No evidence of intra-thoracic growth can be detected, and there is no enlargement to be found of spleen, liver, abdominal or inguinal glands. The man's blood contains a moderate excess of white corpuscles, about sixty in each field; they are as large as the normal white corpuscles of the blood, and present no degeneration. His red corpuscles have been repeatedly counted, and I show a chart of their variations. They were, when he first came to town six weeks ago, only 52 per cent. of the normal, and from that point they have steadily improved until now they are 80 per cent. of the normal. This improvement has coincided with the administration of phosphorus in doses of the 1-30th of a grain, at first three, then four, and now five times a day. The only inconvenience which it occasions to him is a general sense of heat. The man was sent up to Mr. Christopher Heath for an operation, but is unwilling to submit to one, and the removal of the growth seemed to Mr. Heath an operation which would be attended with so much danger as to deter him from urging the man to submit to it. It can scarcely be hoped that, if phosphorus is capable of exerting a beneficial influence in the smaller gland growths, it can arrest the increase of so large a tumour; and from the discoloration of the skin, there is much reason to fear that this growth will ulcerate and kill the man long before the more general gland disease would do so. It is to be noted that the steady increase in the number of the red corpuscles since he has been in the hospital has been unattended by any corresponding variation in the number of white cells.

The second patent is a girl, twenty-one years of age, who presents enlargement of glands in the same situation as the last patient, viz. in both sides of the neck, and both axillæ. The glands are moderate in size, none exceeding that of a small walnut. The submaxillary and suboccipital glands are also enlarged. There is no discoverable enlargement of the spleen or affection of the glands of the somatic cavities. The case is remarkable from its extreme chronicity. Ten years ago, when the girl was eleven years of age, the glands in the right axilla began slowly to enlarge. Four years ago, they had

attained such a size as to interfere considerably with the movements of the arm, and nine of the enlarged glands were removed by Mr. Heath. At this time, and for three years later, there were no glands enlarged elsewhere. The operation was followed by erysipelas and suppuration. One gland remained in the axilla, and this continued slowly to enlarge, but is still scarcely larger than a filbert. In March, 1877, the submaxillary glands in the right side began to enlarge, and in about six months their present size was reached. She now has a swelling the size of two walnuts below the angle of the jaw on the right side. Other smaller glands extend down the neck to the clavicle and up to the occiput. There are one or two small glands enlarged close to the zygoma. None are enlarged on the left side of the neck. The right tonsil is large, and there is obvious enlargement of the follicles on the base of the tongue. There have been at no time an excess of white corpuscles in the blood. There is moderate anæmia, the red corpuscles being about 60 per cent. of the normal. She has taken phosphorus, and, as in the other patient, there has been a coincident increase in the number of corpuscles in the blood from 55 to 62 per cent. I think that there has been also diminution in the size of the glands. Of this she herself is firmly convinced, and so struck was she one day with the difference that she thought she would get well rapidly, and took two doses of phosphorus instead of one each time. Had all the phosphorus been absorbed it would have amounted to one third of a grain daily. The extra dose, however, made her sick, and she discontinued it.[1] The sections placed under the microscopes illustrate several points in the pathology of these diseases, to some of which I will briefly refer.

1. *Sections of the spleen in lymphadenoma.*—The section is from a case in which the spleen showed the typical appearance of growths occupying the greater part of the organ. The growths are composed of lymphoid cells and large quantities of imperfect fibrous tissue, in part presenting the appearance of the broad vitreous bands which have been frequently described. I would, however, call attention to two characters which the section presents. The splenic pulp is compressed, and is easily distinguishable from the growths, not only by its structure, but also by the circumstance

[1] After the case was shown at the Society the diminution of the glands ceased. Arsenic was therefore substituted with the effect of causing pain in the glands and subsequently a considerable diminution in their size, by about a third, and this diminution has (six months later) persisted.

that it contains a large quantity of brownish-red pigment in granules. This pigment does not penetrate the growths, but in many instances is accumulated on the edge of the growths in a dense zone. The other characteristic is that in many of the growths a branch of an artery can be seen to occupy the centre. This relation can be traced in so many of the growths that it is reasonable to assume that it exists in all. Evidently if a vessel occupies the centre of each growth, in only a certain number would the section divide the nodule in such a way as to show the vessel. It is probable from this that the growths are all periarterial. This is very clearly seen in a section from another case in which change in the spleen is much less advanced, and in which there is great increase of all the periarterial tissue, both follicles and sheaths.

The accumulation of pigment on the borders of the growths is mentioned because Ponfick found that pigment circulating in the blood was arrested in the spleen, accumulated on the borders of the Malpighian follicles, but did not penetrate them.

These facts, then, appear to demonstrate that the growths originate in the Malpighian follicles and the periarterial sheaths of lymphoid tissue, of which the Malpighian follicles are but local collections. This opinion suggested itself to Dr. Hodgkin as probable, from the naked-eye appearances. The frequent association in disease of the lymphatic glands and the follicles of the spleen is certainly a very interesting pathological confirmation of the opinion entertained by Malpighi, that the follicles have a more intimate connection with the lymphatic system than the splenic pulp.

It has been pointed out by several writers that the disseminated growth in the spleen, described by Hodgkin, is not the only condition of the spleen which is associated with such general disease of the lymphatic glands as that to which he called special attention. The spleen has been found to be simply hypertrophied, without any visible growths, and it has also been found to present no abnormal appearance whatever. In order to ascertain the frequency with which the several changes are met with I have compared the details of a series of recorded cases of multiple lymphadenoma beginning in the glands. The details of 97 cases were analysed, and it was found that in 59 (or about 60 per cent.) the spleen presented distinct growths. In 19 (or 20 per cent.) the spleen presented simple hypertrophy without visible growths, and in 19 (or 20 per cent.) the spleen presented nothing abnormal in size or structure.

What is the nature of the change in the spleen which gives rise to the apparent hypertrophy of the organ in leucocythæmia, and in some forms of Hodgkin's disease? It is commonly said to be an hypertrophy of the splenic pulp. It is unquestionably dependent on a process of growth, for the consistence of the organ is increased, the connective-tissue trabeculæ are thickened, and the connective tissue cells, which compose or are connected with the finer stroma, are increased. It certainly occupies the position of the splenic pulp; the Malpighian bodies gradually cease to be recognisable. But it has been recently asserted by Biesiadecki that its nature is not that commonly supposed. He believes that there occurs an outgrowth from the Malpighian follicles, and that this growth invades and replaces the pulp, which atrophies before it. It is not easy to decide this question by an examination of the extreme condition. But I think some light is to be obtained by an examination of the spleen in those cases which are to be regarded as intermediate between splenic leucocythæmia and primary gland disease — the cases in which there is an extensive initial enlargement of the lymphatic glands and considerable enlargement of the spleen, due to the same condition as in splenic leucocythæmia, an apparent overgrowth of tissue in the position of the splenic pulp. In this condition the Malpighian follicles do not disappear as such; they remain with even undue distinctness, and may be increased in size. I have placed under the microscope a section of such a spleen. The tissue of the follicles and periarterial tissue is increased in quantity, and has undergone lardaceous degeneration. By Hoffmann's aniline this degenerated tissue is readily distinguished, and it is evident that this lymphatic tissue has not overgrown into the splenic pulp. The increase in the latter tissue is independent of the follicular change, and consists of a special overgrowth. It is then evident that the enlargement of the spleen in these cases depends mainly on this cause, and it seems to be reasonable to conclude that the enlargement of the spleen in leucocythæmia, in which there is no initial gland enlargement, and no associated isolated overgrowth of the splenic follicles, is due to the same cause.

I have said that in this case the splenic follicles had undergone lardaceous degeneration. They give all the characteristic reactions, both with amiline and with iodine and sulphuric acid. In the other spleen of which a section is shown, which is crammed with isolated growths, the larger growths presented no such degeneration; some

of the smaller growths, however, which are scarcely larger than the Malpighian follicles, do present the reaction in its characteristic form.

Another series of sections illustrate the changes in the glands in lymphadenoma, and I may pass over these briefly, since the changes shown are nearly those described several years ago by Dr. Burdon Sanderson, and since then by many others. In the smaller and soft glands there is evident the same abundance of lymphoid cells seen in the normal gland, with a slight increase in the interstitial reticulum. In glands of somewhat larger size, which are still soft, the same abundance of lymphoid cells is evident, and the reticulum is increased in quantity. In the largest and hard glands the increase in the fibrous tissue is very great, and the cells are separated by tracts of firm, imperfectly fibrillated tissue. In places this tissue has the same vitreous appearance which has been mentioned as conspicuous in the splenic growths. This appearance is, however, especially conspicuous in the neighbourhood of the arteries, many of which are surrounded by a series of vitreous layers, seen in longitudinal section as bands parallel to the vessel, and in transverse section as concentric layers. These laminæ are somewhat wavy, and in the intervals between them are small cells, isolated or grouped, for the most part angular or fusiform. The perivascular situation of these tracts of dense tissue suggests the analogous position of the new growths in the spleen. Thus, the glands are the seat of a growth which involves a change of structure, considerable in proportion to the increase in the consistence of the glands.

The nature of the glandular enlargement which occurs as a secondary change in point of time, in some cases of splenic leucocythæmia, has been the subject of some discussion. Virchow and Bennett maintained that the glands were the seat of a growth analogous to that which occupies the splenic pulp. It has been, asserted, however, that the enlargement of the glands is simply due to the accumulation in them of the cells which are circulating in the blood; that there is no actual process of growth. Now, if this were the case, there should be a relation traceable between the degree and duration of the leucocythæmia and the occurrence of this secondary affection of the glands. The greater the excess of leucocytes in the blood, the longer such excess lasts, the more constantly should the glands be affected. No such relation can be traced. In the large majority of the cases of extreme leucocythæmia, in which the white corpuscles are nearly as numerous as the

red, or are as numerous, or more numerous, there is no affection of the glands. On the contrary, the glands become affected secondarily in time to the spleen in many cases in which the excess of leucocytes in the blood is by no means extreme. The histological character of the change, when it occurs, is similar to that presented by the early stage of the glands enlarged in lymphadenoma and just described. There is thus reason for adhering to the older view which regards the change in the glands in splenic leucocythæmia as a growth, and not a mere accumulation of cells. There is nothing unusual in the occurrence of a growth in the glands in association with a growth of splenic pulp, since we see such an association very strikingly in those cases of intermediate character to which allusion has been already made, and in which a primary gland growth is associated with a simple hypertrophy of the spleen; the association is the same as in the condition just described, the order is only reversed.

Sections are also shown of growths in the liver in leucocythæmia and in lymphadenoma. They present nothing that is not already known. Their interlobular position is well seen. In the growth from splenic leucocythæmia, there is, however, a well-marked stroma, different from that of the liver itself, consisting of retiform tissue. In another section the growth is seen filling up a portal canal, and from it invading the substance of an acinus. These facts supply strong reason for believing these accumulations of lymphoid tissue to be actually growths, and not merely accumulations of leucocytes; and another reason in that such growths may occur, as in the well-known case described by Cohnheim, in which such growths occurred in association with hypertrophy of the splenic pulp, without there being any excess of leucocytes in the blood. It is of course conceivable that, commencing as growths, they may be reinforced by wandering corpuscles from the blood, but of such reinforcement there is at present no direct evidence.

A question which excites at present considerable attention, and will probably receive notice in this discussion, is that of the mutual relation of the affections which are grouped under the generic name of lymphatic diseases. The prevailing division into separate forms has been based partly on the change in the blood and partly on the position of the growths. The progress of pathological histology has led to exclusive attention being paid to the minute structure of the new formations and the correspondence of this to the union of

all diseases in which lymphatic overgrowth occurs into one disease—the *diathèse lymphogène* of Jaccoud. It is certain that there exist between all the members of the lymphatic series intermediate forms linking them together, so that from pernicious anæmia with marrow change, we pass by splenic anæmia and splenic leucocythæmia, with marrow or gland changes—by primary gland disease with marrow change, splenic hypertrophy, or growths—and by all those combined with visceral change, to the cases of isolated lymphatic growths in the spleen, other viscera, or skin. But nevertheless, the fact remains that between certain members of the series there are salient differences, and that the cases occur so frequently with certain characters, as to constitute special types of disease, recurring with some constancy, such, for example, as enlargement of the spleen with leucocythæmia, and enlargement of the gland, with anæmia, or with a slight excess of leucocytes in the blood. Taking these two types of lymphatic disease, separated on account of their obvious distinctions, and in order to ascertain what less obvious distinctions might exist between them in etiological conditions and the like, I have compared the details of 154 recorded cases of primary splenic leucocythæmia and 100 cases of primary disease of the lymphatic glands, and have found that the following among other differences are to be traced between them.

There is but little difference in the frequency with which the two sexes are affected. The preponderance of the male sex is, however, more marked in lymphadenoma than in splenic leucocythæmia. In the former three quarters of the cases, and in the latter two thirds of the cases, are of the male sex.

The period of life at which these two diseases are most frequent is, however, very different. On account of the difficulty of determining with accuracy their duration it is only practicable to compare the ages at which death occurs. The following table represents the percentage of deaths of the cases mentioned above in the several decades of life. For greater distinctness I have put it in the form of a chart, the continuous line indicating the percentage of deaths from primary splenic leucocythæmia, the dotted line those from lymphadenoma (see next page).

Another point of difference between the two diseases is their relation to intermittent fever, which, as might be expected, is much more marked in regard to the splenic than to the glandular disease. Statistics on the subject of the relation of splenic leucocythæmia to

malaria have assigned a very low frequency to the association of the two diseases. This is, however, largely due to the fact that in all such

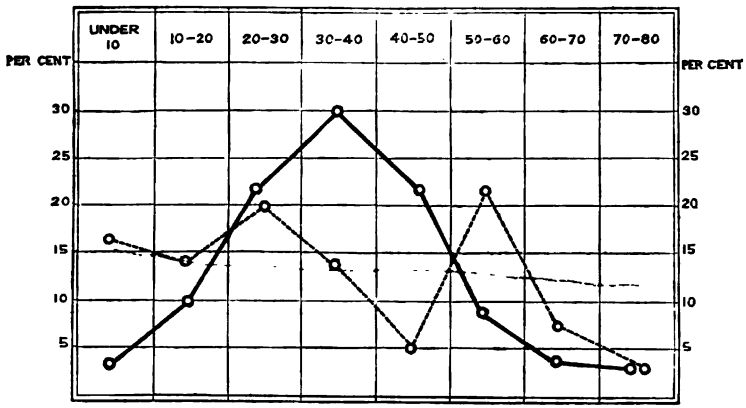

Chart showing the proportion (as the percentage) of deaths at different ages in 154 cases of primary splenic leucocythemia, and 100 cases of primary glandular (Hodgkin's) disease; the former are indicated by the continuous line, the latter by the dotted line.

statistics many cases of glandular disease have been included. All large collections of cases have been based on the statistics of Ehrlich, and at least a quarter of his cases are of a very doubtful character, many of them cases of Hodgkin's disease. When the two forms are carefully separated it is found that in only 4 per cent. of cases of primary gland disease can previous exposure to malarial influences be traced; whereas no less than 25 per cent. of the cases of splenic leucocythæmia (39 out of 150) had either suffered from intermittent fever at some period, or had lived in an ague district. In a large number of cases it does not appear that any inquiry as to residence in an ague district was made, and had this point been more uniformly investigated it is probable that the proportion in which such an antecedent was traced would have been still higher.

Among the minor points of contrast, one point of interest comes out with regard to the glandular affection. The glands which are found enlarged most frequently in primary splenic leucocythæmia are enlarged least frequently in primary gland diseases—the mesenteric.

In concluding, I would make one remark regarding the name of the primary gland disease. That of "Hodgkin's disease" is neutral, but it is not descriptive, and it does not appear likely to obtain

universal currency. On the Continent it is of very limited use, being for the most part superseded by "adénie," "lymphadenie," or "lymphadenoma," the term which here also seems most in favour. But the word lymphadenoma is also applied to the growth, and to a local growth which has all the characters of a local tumour. I would ask whether we might not with advantage slightly modify the term, and apply to the general constitutional disease the term "lymphadenosis," reserving the term lymphadenoma for the local growth, just as we use the terms "tubercle" and tuberculosis."

March 19*th*, 1878.

---

4. *Splenic leukæmia with carcinoma.*

By T. Whipham, M.B.

Joseph S—, æt. 23, a machinist, was admitted into St. George's Hospital, under the surgeons, on February 21st, 1877, and was transferred to my care on March 23rd following.

He came of a healthy family, and had himself previously enjoyed good health, with the exception of a tendency to costiveness and profuse perspiration. He had been brought up at a public-house, and had taken three or four pints of beer daily, with spirits occasionally.

He had lived at Wellingborough (Northamptonshire) till three years before admission, then at Horncastle, in Lincolnshire, for fifteen months, and finally at Reading.

From August, 1876, he had noticed a lump in the lower part of right side of the abdomen, which gradually increased in size, and from September had felt a lump in the left side also; he suffered no pain, though the swelling increased in size. The general health was in no way affected, and he was gaining weight up to his admission, a month, that is, before he was transferred. From that time he had fallen away, and had perspired more than usual. Had suffered from nausea and vomiting during the month, from frontal headache and cough for three weeks, from severer headache for three days, from palpitation for an indefinite period, from anorexia (with nausea) for a week continuously, from slight hæmatemesis for two days. The bowels had been fairly regular. Two or three days before his transfer to the medical wards I was asked to see the patient by my colleague, Mr. Rouse, and in consequence of evident symptoms of leukæmia had him placed under my own care.

His blood at this time contained an enormous number of leucocytes, which in many parts of the field were more numerous than the red corpuscles. On admission into the medical wards, his condition was briefly as follows:—great giddiness, face slightly flushed; the body generally in good condition; perspiration profuse; some patches of chloasma on the chest.

Lungs.—The apices were equally resonant; respiration at both accompanied by a few wheezing rhonchi and indefinite moist sounds. The back was not accessible owing to the giddiness. Respirations, 37 in the minute.

Heart.—The cardiac impulse was seen and felt over the whole organ; the apex was in the fifth space; an inch and a half to the left of the nipple line the sounds were loud, but no murmur was heard. Pulse 104, sharp.

Liver.—The liver dulness extended from the fifth rib one inch into the abdomen. The abdomen was distended; a rounded tumour, dull on percussion, occupied on the left side the hypochondriac, lumbar, umbilical, inguinal, and hypogastric regions; on the right the hypogastric and parts of the umbilical and inguinal regions; the left infra-mammary region of the chest was also dull, and a dulness continuous with that described as existing in the abdomen extended upwards to within an inch of the left nipple level. There was tenderness on pressure over the liver, not over the tumour.

The urine was acid and albuminous, and containing an abundant precipitate of orange-coloured urates, but hardly any phosphates.

On March 25th he became much agitated, complained of weakness, giddiness, and severe headache, with nausea. The breathing was much oppressed; the face and conjunctivæ were much suffused; the pulse full and strong. During the night dyspnœa became very urgent, the face more and more cyanosed, and he died early next morning.

Autopsy twenty-six hours after death.—The body was that of a well-proportioned man, with dark hair. The skin was universally congested; with fine red mottling; the head and neck were especially congested, and ecchymosis had occurred under the conjunctivæ.

Pleuræ.—The left pleura was in every part adherent.

Lungs.—Both were congested, though not of a very deep colour; the congestion was for the most part diffused, but here and there it was patchy. No part of either lung was sufficiently solid as to sink in water, and though fully expanded these organs contained but little air,

and exuded no fluid on pressure. The bronchi were highly congested. The large branches of the pulmonary vessels contained no clots, but in the smaller ones coagula had formed, to be described below.

Heart.—15 oz. It presented no structural changes evident to the naked eye; its substance was firm.

Vascular system.—The contents of the heart resembled in all respects those of the vessels of the body generally; they consisted of a solid part and of a fluid part; the latter of a pale red, leaning to brown; the solid part was of a white-yellow colour. The venæ cavæ were full of very large masses of this kind; the smaller vessels contained both solid and fluid constituents of the blood, and the coagula could be pushed along the vessels. The vessels of the meninges and of the brain itself presented a remarkable appearance, owing to distension of the vessels with white coagulum; occasionally a small mass of red clot was found occupying one side of the white clot, but such collections of red blood were very rarely met with.

Liver.—The liver weighed 128 oz., but beyond the fact that it was paler than natural, nothing abnormal was evident to the naked eye; its substance was firm.

Kidneys.—The left kidney weighed 11 oz., the left 10 oz. They had a red congested appearance, and their cut surface was coarse-looking.

Spleen.—The spleen weighed 78 oz. It was very hard, tough, and of a flesh-pink colour; it was, moreover, traversed by a white network, to the naked eye resembling fibrous tissue. Several depressions were visible on the surface, and these corresponded with masses, apparently fibrinous infarcts, with a certain amount of black pigmentation. Other and more recent infarcts occurred in different places.

Brain and spinal cord.—The meninges presented nothing abnormal beyond the white coagula in their vessels. The spinal arachnoid contained some gelatinised serum. The substance of the brain was normal in consistence, but much congested. No undue congestion was noticed in the spinal centres, which appeared normal.

Bones.—The skull was thin, and most of the bones examined were softer than natural.

Lymphatic system.—No enlarged glands were found.

Thyroid body.—This organ was enlarged slightly and very hard.

The *tonsils* presented no abnormality. All the true articulations were sound; the intestines appeared to be natural.

Microscopic examination.—*Liver.*—On section the tissue of the

liver was pale, but beyond this fact no abnormality was evident to the naked eye. However, after immersion in methylated spirit or chromic acid, in consequence of decolorisation probably of the affected parts especially, its substance was found to be studded with white nodules, most of which were of about the size of peas; many were rather larger. These nodules varied in shape, but were for the most part round, their outline was sharply defined, but no evidence of their presence was, in the recent state, manifested either from irregularity of the surface of the organ, or from difference in colour between them and the unaffected parts of the liver. The result of microscopic examination of the nodules and the adjacent parts was as follows: —

They were found to be composed of new growth, in which the following appearances were observed:—A somewhat dense fibrous stroma enclosed large cells which varied in shape; many were columnar in form, some round, some angular, and some pyriform. No intercellular substance could be detected. These cells contained but one nucleus, and with their enclosing fibrous stroma were disposed in many places in distinct tubes, somewhat after the fashion of tubercular epithelioma; but the growth differed from that disease in that the cells were not generally so columnar in shape, and that the fibrous stroma enclosing them was very much more dense. Those cells, moreover, which were columnar in shape had not the definite arrangement so well drawn and described by Dr. Greenfield in his case of primary tubular epithelioma of liver in 'Path. Soc. Trans.,' vol. xxv, p. 166, or in my own case in 'Path. Soc. Trans.,' vol. xxii, p. 164.

Transverse sections of these tubular growths were somewhat irregular in shape, but many of them were round. The irregular alveolar spaces thus formed by transverse sections of the tubes, with their contained cells, bore the strongest resemblance to true carcinoma, save only that the cells were perhaps more columnar in shape than those usually met with in this disease (Pl. XV, fig. 1). At the margins of the white nodules the hepatic tissues were compressed, which gave the liver tissue the appearance of a concentric arrangement around the new growth, and in such places division of the hepatic cells could be seen, and a gradual transition from normal hepatic tissue into that of the new growth.

In other places the following appearances were presented:—There was a matrix for the most part granular and structureless, in which were imbedded masses of cells resembling leucocytes, and with their liver cells, of a more or less yellow colour, degenerated, and altered

DESCRIPTION OF PLATE XV.

The figures in this plate illustrate Dr. Whipham's remarks on Lymphadenoma. (Page 313.) From drawings by himself.

FIG. 1.—Section from the liver, showing a somewhat tubular arrangement of the new growth. The alveolar walls are for the most part composed of dense fibrous tissue, and the enclosed cells are in many instances columnar in shape. (× 450.) Specimen preserved in chromic acid.

FIG. 2.—Section from the spleen, showing the results of extravasation of blood. On the right are seen bands of fibrous tissue, enclosing, in irregularly shaped meshes, masses of hæmaglobin of a brownish red colour. Towards the left the fibrous bands are more widely separated by structureless or delicately fibrillated matter, in which are embedded small masses of hæmoglobin. Two large vessels filled with leucocytes are represented in the centre of the drawing. (× 320.) Specimen preserved in chromic acid.

FIG. 3.—Section from the spleen, showing a coarse fibrous stroma, in the irregularly shaped meshes of which are leucocytes, and here and there cells of an epithelial type; found in the neighbourhood of the old infarcts (× 140.) Preserved in chromic acid.

FIG 4.—A portion of the same more highly magnified (× 320).

Fig 1

Fig 2

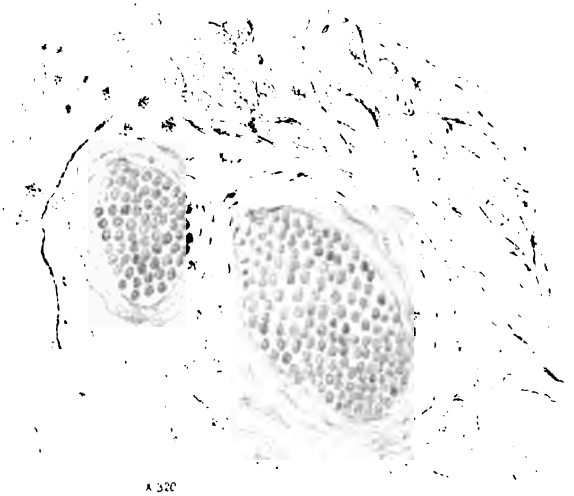

Fig 3.

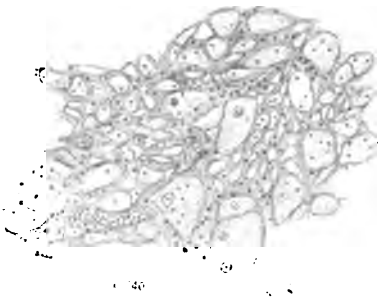

Fig 4.

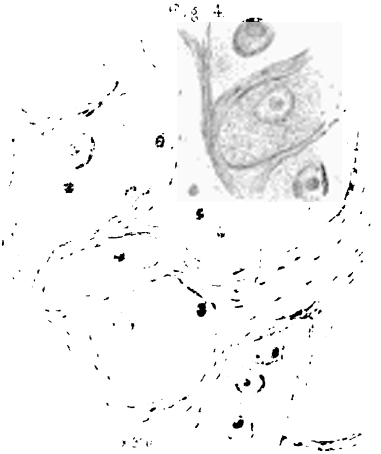

considerably in shape. In such parts large empty spaces were seen, more or less round in shape, in some of which a delicate fibrous wall could be made out, while in others all traces of such fibrous walls were absent, and the boundaries of the vacant spaces were formed by the structureless matrix. It would appear that these spaces are transverse sections of the original liver cylinders from which the cells have fallen during the preparation of the section.

In other parts, at some little distance from the margins of the new growth, the spaces between the liver cylinders contain large numbers of leucocytes at irregular intervals, but having an arrangement corresponding to the disposition of the capillaries.

In other places the hepatic tissue was normal in appearance, but the small vessels were all filled with leucocytes, while in some of the larger ones red blood was seen, but even in these the proportion of leucocytes to red globules was very great. Surrounding some of the blood-vessels, leucocytes were seen in great numbers, suggesting the notion that they had migrated from the vessels.

The bile ducts were normal in appearance.

Spleen.—To the naked eye the spleen was somewhat pale in colour, and it was universally dense and firm to the touch. After immersion in chromic acid or spirit the irregularly-shaped masses, of a dull white colour, became more manifest. These white portions were, in many instances, more or less triangular in shape, and some which were on the surface of the organ resembled infarcts of old standing.

Microscopic examination of such parts and of the tissue in their immediate neighbourhood showed that extravasation of blood had occurred into the splenic tissue, which had broken up the normal tissue, and that the remains of the reticulum of the glands, as isolated fibrous bands, ran in various directions through the blood clot. In these extravasations leucocytes were present in large numbers, but their proportion to the red corpuscles was much smaller than elsewhere, even in the large blood vessels in which red blood was occasionally found.

In other parts the following appearances were noticed as shown in Pl. XV, fig. 2. There was a coarse fibrous stroma, of which the fibrous tissue was for the most part arranged in parallel bands, which in their course diverged occasionally from one another, thus forming oval loculi, which were filled, or very nearly so, with orange-red semitransparent masses of hæmoglobin. Such appearances are

represented on the right of fig. 2. On the left of this sketch it will be seen that the fibrous bands are without any definite arrangement, and that they are separated more or less widely from one another by a structureless or perhaps somewhat delicately fibrillated matrix. In this matrix are seen roundish masses of hæmoglobin.

The appearances above described may be explained by the fact that the condition seen in fig. 2 is merely a later stage of the extravasation of blood. On the right of the figure perfect fibrous tissued has been formed partly from the pre-existing stroma of the spleen and partly probably from organization of the blood clot, while on the left of this sketch an intermediate stage between the two conditions exists.

In other places, however, the fibrous tissue was arranged so as to form a coarse reticulum with irregularly ovoid meshes (Pl. XV, fig. 3). Many leucocytes were scattered throughout this reticulum, and occasionally in the meshes large flat cells of an epithelial type were seen, but these cells were by no means frequently found. In other parts an indistinctly fibrous or granular stroma existed, in which were imbedded ovoid or reniform bodies of small size, probably the nuclei of pre-existing cells. The blood-vessels throughout the spleen were filled with leucocytes; occasionally in the larger ones red blood was sparingly intermingled with them.

Pancreas.—A portion of the pancreas, hardened in spirit, presented the following naked-eye appearances:—it was of a buff colour, was coarsely granular or somewhat lobulated on the surface, and on section was traversed in various directions by delicate white bands; in fact, it in many respects bore a resemblance to the atrophied ovary of an old person.

Microscopic examination showed that this specimen was the seat of a new growth precisely answering to the description of that found in the liver. The tubular arrangement of the growth was in many places remarkably evident, especially under a low power (Pl. XVI, fig. 5), and the tubes were in some few instances branched; of the contained cells some were pyriform, others angular, and many distinctly columnar in shape. Precisely as in the liver, the cells lacked the definite attachment to the walls of the tubes usually observed in specimens of columnar epithelioma, but were, with some few exceptions, disposed without any such definite arrangement. This may be in consequence of the cells having been displaced during the preparation of the sections, or (and I think with greater probability) because the

DESCRIPTION OF PLATE XVI.

Illustrations of Dr. Whipham's specimen of Leukæmia—(*continued*).

FIG. 5.—Section from the pancreas, showing an unbranched tubular arrangement of the new growth. The tubular-shaped masses are separated by broad bands of fibrous tissue. (× 140.) Specimen preserved in spirit.

FIG. 6.—Section from the pancreas—a transverse section of the tubular-shaped mass containing columnar cells. (× 450.) Specimen preserved in spirit.

FIG. 7.—Pancreas; longitudinal section of one of the tubular-shaped masses, having a branched form; many columnar-shaped cells are contained within the fibrous walls. (× 450.) Specimen preserved in spirit.

FIG. 8.—Section from the lung; alveoli containing transparent homogeneous matter (serum); alveolar walls thick in consequence of the distension of the blood-vessels by leucocytes. (× 140.) Specimen preserved in spirit.

FIG. 9.—White corpuscles from the clot in the heart, containing one, or two, or three nuclei. The corpuscles vary in size. *a*. Red blood-corpuscles. (× 650.) Specimen preserved in spirit.

Fig 5

x 140

Fig 6

x 450

Fig 7

x 450

Fig 8

x 11

Fig 9

x 50

disease more nearly resembles true carcinoma (longitudinal and transverse sections are seen in figs. 6 and 7).

In other parts of this specimen blood-vessels with thickened walls were seen lying in close proximity to one another, and surrounding them, in some places, a structureless granular matrix containing many small nuclear bodies, while in other places the vessels were imbedded in a more or less coarsely reticulated fibrous mesh-work; occasionally broad bands of fibrous tissue traversed the granular matrix.

In other places the following appearances were observed:—The fibrous stroma was arranged somewhat after the fashion of an acinous gland, but in place of the normal glandular elements an absolutely homogeneous semitransparent material occupied the acini. This material readily took the blue staining of the indigo carmine, and closely resembled that seen in the alveoli of the lung. It was found also, in some parts, lying among the bands of the fibrous stroma. It may be that these appearances are due to degeneration of the gland tissue. In this instance, however, the distinctive character of colloid degeneration as defined by Rindfleisch—that is to say, that the "transparent swollen jelly" contains a network made up of stellate anastomosing cells—is wanting; nor is there any trace of a fibrillated matrix indicating, according to the same pathologist, mucous softening of connective tissue.

This transparent substance bears a close resemblance to that described by Dr. W. H. Dickinson as occupying parts of the spinal cord in tetanus, and I have myself found it in cases of acute inflammation of the kidney.

It should have been observed that in this specimen, beyond the indistinct resemblance to the pancreas above mentioned, no traces of gland structure were found in the portion preserved for microscopic examination; and it is from the likeness which its external surface bore to that of the pancreas, together with the acinous appearances above mentioned, that it has been described as a portion of that gland; moreover, the naked-eye appearances combined with subsequent examination by the microscope of the other portions of the viscera, left no doubt as to identity in each case.

Lungs.—The alveolar walls were much thicker than natural, the increase in bulk being due to the distension of their capillaries by leucocytes. In the more solid parts, however, the alveoli were occupied by a semi-transparent homogeneous substance, somewhat resembling that already described as existing in the pancreas

(fig. 8), that is to say, it was entirely devoid of structure, and readily acquired the blue tint of indigo carmine. The mass in each alveolar space, in almost every case, presented, at different points of its margin, an appearance as of vacuolation; seeing that it is, however, doubtless an effusion of serum or an œdema of the lung, this appearance will be at once accounted for by the contraction induced by the action of the alcohol in which the portions of the lung were preserved. It is somewhat remarkable, however, that from the cut surfaces of such portions of the lung no frothy fluid exuded as in ordinary œdema, even on pressure; the semi-transparent contents of the alveoli must, therefore, have been more or less solid at the time of the *post-mortem* examination—a condition which may be referable to the diseased state of the blood.

Kidneys.—The uriniferous tubes of the kidneys were natural, but, as in the case of all other organs, the blood-vessels were distended with leucocytes, and it is to this fact that the coarse appearance of the cut surface was due, and which gave to these organs the naked-eye appearance of kidneys affected with tubular nephritis.

Heart.—The muscular tissue of the portion of the left ventricle reserved for examination had, in many places, a finely granular appearance, and the striæ were less clear and distinct than natural, the distension of the blood-vessels, and especially of the capillaries, had caused in many instances a wide separation between the fibres, producing the effect of a minute artificial injection of the organ. Various portions of the brain, spinal cord, small intestine, lymphatic gland, and superior cervical ganglion of the sympathetic were examined, but beyond the fact that the blood-vessels, with the exception of some of the larger ones, in which a small proportion of red blood was occasionally seen, were filled often to distension with leucocytes, no abnormal appearances other than those usually found as the result of *post-mortem* changes were observed.

Bone.—A section of a portion of the sternum showed the medullary spaces to be absolutely filled with leucocytes; traces of fat were extremely rare, and no giant cells were to be seen.

Blood-clot.—The white coagulum found with the heart was composed almost entirely of white corpuscles, which varied very much in size, some very large, others quite the reverse. The smaller cells contained, for the most part, one fairly distinct nucleus, while in others the nucleus was indistinct or invisible, and the cell contents granular. Many of the larger ones contained one, two, and rarely,

three and four nuclei, in all cases clearly defined, some of which are represented (drawn with the camera) in fig. 9.

The large size of the white corpuscles, and their boldly defined nuclei, is mentioned as especially characteristic of leukæmia in 'Path. Anat.,' Wilks and Moxon, ed. 1875, p. 477.

Remarks.—Is there any connection between the disease known as leukæmia, of which this case appears to be a marked example, and the carcinomatous growth found in the organs described? is a question which at once suggests itself. Leukæmia, according to modern authors, "approaches in many ways to the character of a truly malignant and infectious disease of the blood; that is, a cancer of the blood" ('Path. Anat.,' Wilks and Moxon, 2nd ed., p. 458), and it is therefore possible that in this case we have a local manifestation of the blood disease. But against this theory are arrayed a number of facts which tend materially to refute the idea. In the first place recorded cases of true leukæmia with cancer are rare.

2ndly. If the above theory were correct it would be difficult to explain the fact that so few organs were affected with the new growth, in the presence of such extensive disease of the blood.

3rdly. Dr. Moxon has lately confirmed Trousseau's observation, that in cancer the number of white corpuscles is greatly increased; a fact which is of great importance in the diagnosis of cancer affecting internal organs. In this case it is almost impossible to suppose that the leukæmia was secondary to the cancer, and for this reason:—the cancerous growth was quite in an early stage, as is shown both by the small size of the nodules, and by its having been undetected by the naked eye at the *post-mortem* examination. Supposing for the moment that this explanation (that the leukæmia was secondary to the cancer) were possible, a great difficulty would at once arise, viz., that in cases of advanced carcinoma, in cases, that is, where large masses of the growth are found in the body, leukæmia would always be a most prominent symptom.

One fact, however, in the present case, suggestive of a connection between the two diseases, is the presence of the polynucleated cells in the blood. In the present state of our knowledge, however, of leukæmia and cancer no definite conclusions can be drawn from a single instance, and for the present, at all events, one must be content to say that in this instance the two diseases were co-existent. The case is, I think, clinically, an example of leukæmia; but pathologically, of leukæmia and cancer combined. *April 2nd*, 1878.

5. *Cases illustrating diseases of the lymphatic system, and particularly lymphadenoma or leukæmia lymphatica, and leukæmia splenica.*

By James F. Goodhart, M.D.

Case 1.—*Caseous tubercle of the bronchial glands invading the lung. Tubercular meningitis and general tuberculosis.*

Amy S—, æt. 14 months. The child was admitted under Dr. Pavy with hooping-cough. It was always a spare child, and eventually, for it was in the hospital some months, it wasted still more, and ultimately died with acute thoracic and cerebral disease.

The *post-mortem* was made by Dr. Hilton Fagge. The brain showed tubercular meningitis of the usual characters. The lungs contained a little grey tubercle, scattered in clusters very sparingly in both lungs, except in those parts of the upper and lower lobes of the right lung which were in immediate proximity to the mass now to be described. The middle lobe of the right lung was in a remarkable condition, being unusually solid and enlarged, so that its borders were convex towards the other lobes; its posterior angle and root were uniformly caseous, forming a large mass as large as an apricot. The anterior edge of this was very definite, and festooned with convex edges. The part of the lung in front of it (about one third of the whole) was also consolidated and of a grey colour, and on examination proved to be infiltrated with tubercle similar to that in other parts of the lungs. The microscope confirmed its tubercular nature. Sections showed that besides mere catarrhal pneumonia there was a vast amount of lymphoid cell growth, in part developed round the smallest bronchial vessels, but much of it extra alveolar. The bronchial glands at the root of the left lung were not enlarged. Tubercles were also found on peritoneum, in liver, spleen, and mesenteric glands.

Case 2.—Fanny P—, æt. 3, was admitted under the care of Mr. Bryant, on November 20th, 1873. The child was a deserted infant, and the matron of the union whence it came states that, three months before its admission to Guy's Hospital, the nurse called her attention to a small lump, about the size of a marble, situated

on the left side of the neck. It enlarged gradually for two months, and then very rapidly. It was also noticed that the swelling got very dark when the child cried. The surgeon in attendance at first thought that it was an enlarged gland, but latterly there had been some doubt as to the correctness of this diagnosis.

On admission there was an oval swelling on the left side of the neck, extending from within an inch of the median line in front, to within an inch of the median line behind. It touched the clavicle below, and extended upwards half way to the under surface of the jaw. The skin had a slightly blueish tinge over the swelling, and the swelling could be reduced in size by pressure. There were some harder nodules, mostly superficial, and they ran up in the line of the glandulæ concatenatæ.

The swelling proved to be a mass of lymphatic glands, and was removed. The glands were all fleshy, none caseating. She left the hospital two months later perfectly well.

CASE 3.—*Caseous inflammation of bronchial gland at the root of the right lung. Infection of glands at apex of the lung; infiltration of surrounding tissues by a lymphomatous growth, which included the muscles, and extended into the spinal canal, producing paraplegia.*

Arthur T—, æt. 6, was admitted under Dr. Pavy, on November 17th, 1875. He was an orphan, at some government school, and very little was known of him, but he had somewhat suddenly become paraplegic about a fortnight before, and he was not known to have had any injury.

He was admitted with complete paraplegia and incontinence of urine. Sensation also was very deficient below the umbilicus. His arms were unaffected. He was in fair health except the paraplegia, and lay in bed with apparently nothing the matter with him except the paralysis. About three months after his admission symptoms of pneumonia developed, and he died in a day or two.

Autopsy.—The spine itself appeared normal externally, but the right intervertebral groove in the upper dorsal and lower cervical regions was rather filled out, and on dissecting off the skin the muscles of the back of the neck had an appearance of being infiltrated by a sémi-purulent material. They were pale, and had a greenish-yellow tint. This condition extended from the skin through the entire muscular substance, through the intercostals into

the chest. On removal of the lungs from the thorax a large mass of tough, reddish substance, with yellow mottlings, was adherent to the apex of the lung, and the corresponding part of the spine and the first rib. It was necessary to cut this away from the spine. It formed a hard nodular mass opposite the neck of the first rib, but thence spread away beneath the pleura in a plate-like layer, with circinate edges, as if it had spread by the marginal formation of fresh centres, which had ultimately coalesced with the parent mass. Not only had the growth changed the intercostal muscles, but it had extended through the intervertebral foramina at the upper dorsal region, and had lined the laminæ of the vertebræ from the axis to the eighth cervical vertebra, forming a mass the size of one's little finger at one part, which filled the canal, and below which the subarachnoid tissue was distended with fluid. The growth, dura-arachnoid and cord were adherent. Two other separate nodules existed beneath the pleura on the right side of the chest, one in the fifth intercostal space, the other in the seventh. They were flat button-shaped circular masses, adherent to the pleura, but not to the muscular structures.

The microscopical characters of all the growth was that of lymphoma. The spinal cord was injured by pressure, but not otherwise.

At the root of the right lung there was a caseous bronchial gland, well encysted by fibrous tissue. There was also one caseous patch in the same lung in the neighbourhood. No tubercle was present anywhere, and except some recent broncho-pneumonia the lungs were healthy. The glands at the bifurcation of the trachea were large and swollen. The blood was deficient in corpuscles and looked watery. The bones were healthy. The spleen was healthy.

I added to the *post-mortem* report this note: "The course of events that seems suggested by the morbid appearances is, first, some caseous change in a gland at the root of the right lung; next, a chronic irritative hyperplasia of the glands at the lower part of the neck; next, their tumourous growth and the invasion of neighbouring structures, and the growth into the spinal canal."

CASE 4.—*Progressive caseous disease of the lymphatic glands after disease of the knee-joint.*

A man, æt. 22, was admitted into Guy's Hospital, under the care

of Mr. Forster, in 1871. He had been quite well till two years before, when his right knee became stiff, and he was soon unable to bend it. He came under treatment for the knee affection, and the limb was amputated, and he died not long afterwards.

The medulla of the femur was in a state of caseation, and there were cheesy glands in the groin, right lumbar region, and in the right psoas region, as far as the portal fissure. The glands at the root of the lungs were extremely enlarged and caseous, and there was general tuberculosis of the lung. The axillary and cervical glands on each side were also enlarged and caseous. No more need be said of this case, as it has already been published in the 'Guy's Hospital Reports' for 1872-3, p. 401.

The fifth case was one of Hodgkin's disease associated with lymphadenoma of the brain, and has been described by Mr. Hutchinson.

CASE 6.—*Diffused carcinoma with the distribution of Hodgkin's disease.*—W. B—, æt. 53, was admitted on December 2nd, 1863, under Dr. Wilks' care, and he died on January 11th, 1864. He looked very ill when he came in. He said he had always been temperate. He had constant cough, and difficulty of breathing, but not much expectoration. It was thought he might have some chronic diffused inflammation of the lung. Nothing definite was determined. He got thinner, and died exhausted; his only symptoms being dyspnœa and cough.

There were some hard granular deposits in the lungs like those often met with in chronic inflammation, but nothing like cancer.

The bronchial glands were much enlarged and they formed a firm dense mass around the trachea and bronchi. Their section was white, not yellow, and firmer than is usual in scrofulous cases. Some of the glands were only partially affected. The whole of the peritoneum was covered by small tubercles of cancer, and the omentum and mesentery were infiltrated and much thickened. The surface of the liver and spleen was also covered. At the lesser curvature of the stomach the glands and pancreas were full of the same, and much hardened.

The external surface of the intestine was covered with larger growths, having the external appearances of ordinary cancer. These grew from the peritoneum, were round, white, and depressed in their centres; much about the size of peas, or larger. They

looked like cancer, but when cut through were firm like fibrous tumours, and they gave no juice on scraping.

The liver was covered with tubercles of the same nature, and its interior also contained several. The spleen contained a number of white firm deposits about the size of peas, and resembling the ordinary scrofulous matter. The kidneys contained small white deposits.

The material in all these organs when examined was found to consist of a low organisable deposit, fibrillated with nuclei. No large nuclei, and no cells.

Dr. Wilks remarks that "the deposit throughout the body consisted of a low organisable material of a fibro-nucleated character. Its mode of growth and development was like cancer as regarded the peritoneum; but as regarded the spleen and bronchial glands and some other parts, it resembled in position and appearance scrofulous deposit."

The seventh case has already been recorded by Dr. Frederick Taylor in the 'Transactions of the Pathological Society,' vol. xxv, p. 246. I think one may venture to describe it as one of malignant lymphadenoma. A very similar case, but occurring at a different period of life, came under my own care only a short time back. He was a man of 65, who came to my out-patients' in October of last year, complaining of pain in the back and irregularity of the bowels. The latter was chiefly due to constipation, and he had had no proper evacuation for three or four weeks; generally little more than flatus escaped. Nausea, too, had been present for some few weeks, and lumps had come in various parts of his body. Examining the abdomen, it was full of lumps, but there was no thrill, and it was resonant into the flank. A large hard mass was felt in the epigastric region, not quite dull on percussion and separable from the hepatic dulness by an interval; and probably therefore some new growth in the omentum or colon and adjacent part of the stomach. There was a deep mass in the splenic region, and the mucous membrane of the rectum was on examination found covered by large hard rugæ, as if infiltrated by new growth. Large masses of glands were present on both sides of his neck, in both axillæ and in both groins, but larger in the right groin than the left. There was no apparent increase of mediastinal dulness, and the thoracic viscera were normal. The blood contained a considerable excess of small white blood-cells, the exact proportion I have, in the hurry of out-patient work, omitted to note, but I should say

from memory 150 to 200 in each field. The large splenic corpuscles were in about their proper proportion. He came the following week, somewhat deeply jaundiced, and promised to come a day or two later for admission; but he never did, and I think it is certain that he became quickly worse and died. I called the case one of malignant lympho-sarcoma of the bowel, peritoneum, lymphatic glands, and spleen, with leucocythæmia, but it appears to differ very little from such cases as that of Dr. Taylor, already alluded to.

Now, taking these cases collectively, they form a series which may all be devoted to the purpose of showing that there is a definite chain of morbid appearances in diseases of the lymphatic glands, which, taken together, form the picture of a very complete, shall I not say orderly, pathological process. Links of this chain may, it is true, be isolated, and, when examined separately, show such marked distinctness that it must appear to some they must be separate diseases. Yet each and all are so often and so much commingled, and their commingling is so enlightened by other facts in general pathology, that for my part I cannot isolate and discuss one disease without reviewing the whole group. Now, if we take the series I have described, and fill in any gaps which may exist in it, we find the following conditions of the lymphatic glands all closely related to each other. First, there is a local chronic inflammation (the so-called scrofulous gland), next a local simple tumour, called by some hypertrophy, lastly, a local malignant tumour, some varieties of which are called by some lymphatic cancer. These are all *local*. But there is also a parallel series of generalised affections, a diffused chronic inflammation or scrofulous state, a diffused or general simple tumour, a generalised malignant tumour, and, with the exception of the scrofulous or caseous group, which, from the very nature of the necrotic change, can hardly be expected to exhibit active growth, and perhaps of the generalised malignant tumour of which I shall speak more particularly directly, these various conditions can be shown upon very good clinical if not pathological evidence to lead the one into the other. For instance, the chronic inflammation may become a local tumour, the local tumour may become malignant. The local tumour may become generalised still as a simple tumour, or as a general malignant tumour. Then compare these conditions with those in other tissues, and what do we find? Why, that local persistent stimulation will produce a local tumour, that the local tumour may remain as such or become malig-

nant, or become generalised. There is no exception to this rule in any tissue of such in which tumours commonly grow. It is true for epithelial structures, it is true for all the varieties of connective tissue. Or, to take another method of enumeration, it is true for various organs. For instance, take the lungs, and a chronic inflammation will lead to active growth. The growing tubercle may remain confined to the one organ or become generalised. Take the serous membranes, and over and over again one finds chronic inflammatory conditions giving rise to local and then to general tuberculosis. Then, with regard to general malignant disease of the lymphatic glands, which is in some sort special, in that it cannot always be traced to some pre-existing chronic condition of over action, yet even for this we find analogous states of the other tissues, when a general tuberculosis bursts out suddenly, or a general cancer of bone or connective tissue, so that it seems to me that we might, by the study of the morbid activity of the elements of other tissues, predicate the changes which are found in the lymphatic glands, without ever having made any previous study of those changes. They thus fit in and harmonise with other known and more recognised pathological conditions, and constitute other examples of that process which has of late years most aptly received the name of *infective*. It has been shown of late years by experiments on the lower animals, chiefly by Dr. Burdon Sanderson, that a single irritant, varied in intensity, will produce septicæmia, local abscesses (pyæmia), chronic indurations, and tuberculosis; and though there is a limit in this application of the results of experiments on the lower animals to man, still all the facts of lymphadenoma seem to point to some such single cause which may in its action evolve somewhat different results. Thus, if the subject is not too obscure for illustration, the local irritant to the lymphatic glands may be so intense as to produce an abscess; if less intense, still sufficiently so to induce the production of the cellular element of the glands in such abundance that they choke themselves and caseate, when the scrofulous state is produced, and this state may easily be propagated to neighbouring glands. If still less intense the stimulus excites merely to overgrowth or fleshy hypertrophy, and this infecting or not the neighbouring glands or the neighbouring tissues, becomes generalised, or remains local, is innocent, or malignant, according to circumstances.

There are few better illustrations of this close relation between

inflammatory growth and tumour growth than those occasionally afforded by syphilitic patients. There are in our museum some truly enormous growths about the mediastinum which have many of the appearances of gummatous tumours, have occured in syphilitic patients, and yet have grown as tumours, having their own life quite independent of any specific stimulus which called them into being. Such growths are no longer influenced by specific treatment, and the neighbouring tissues are no longer respected. Every one is familiar with the cases of chronic induration and suppuration of the glands all over the body in old syphilis. So that if a poison, acting under such definite limitations as this, seems occasionally to lose its specific intensity and act as a local irritant, much more then are the less severe forms of chronic stimulation likely so to do, and by their more continuous action to lead to hypertrophy and tumour.

I have said so much because I wished to clear the way for this view of leukæmia. If the various degrees of lymphoma are parallel to stages of growth in the cells of other tissues, then it would seem that to drag out one of these stages and consider it by itself because of a special symptom which it may possess, is to dislocate or disarrange the whole pathology of lymphoma. I hold that, assuming for the minute that leukæmia does sometimes occur in lymphadenoma, that it is a non-essential item in discussing its pathology; it is, in fact, a late symptom only, in no sense a cause. But the question has been raised by Dr. Wilks whether leukæmia does or does not exist in lymphadenoma. Now, it seems to me that the arguments on this point are two, an *à priori* one, and one founded on the observation of cases. It is, I believe, held by physiologists as well established that the lymphatic glands do discharge their corpuscular elements into the circulation, and if so, it is to be expected that a large overgrowth of gland tissue should lead to too large a supply, and thus to leukæmia; and there are cases on record to show that such a condition does occur.

On the other hand, there can be no question that the larger number of cases show no marked excess. My own experience quite coincides with that of Dr. Wilks, Dr. Greenfield, and others. I have for some years past made a point of examining the blood in all these cases, and the absence of any increase of the white blood-cell is so constant that I have ceased to take notes of the cases. But then, I think, there is an explanation of this: we should not

expect to find leukæmia when the glands are all caseous and work thus at a standstill. Nor should we expect to find any excess when the glands are fibrous. Now, if we take away from lymphadenoma the cases in which the glands are caseous and those in which the glands are fibrous, a large proportion are gone altogether from our calculation, and the smaller remainder, with fleshy succulent glands, will probably give an excess. I think the evidence of the occasional occurrence of such cases is sufficient, and additional support to this is derived from the occasional though rare occurrence of leukæmia in other states, such as acute suppuration and medullary sarcoma. The cases I have named as the smaller proportion have usually some moderate enlargement of the spleen, but just as the splenic disease seems to give rise to moderate swelling of the lymph glands, so conversely the spleen may be itself affected without much improbability. Moreover, another argument in favour of a lymphatic form of leukæmia is surely one originally advanced by Virchow, accepted I thought by most pathologists now, and to which as yet I have seen no exception in the excessive cases which have fallen under my own notice, viz. that the form of the cell is different in the two cases. There can be no doubt of the fact that in these cases the white cells are small, granular, and like those in the lymphatic glands; in splenic leukæmia they are more uniformly large. The case which I brought before the Clinical Society last year was one of this sort, and as the specimens have not been before exhibited, they are under the microscope in the other room for the inspection of the members tonight.

Having touched upon the occasional occurrence of leukæmia in conditions other than those of glandular enlargement, I may say, with reference to the remark of Dr. Wilks on this head, that in observations on the blood in pyæmia for other purposes, I have had occasion to examine into the state of the blood in acute suppuration somewhat carefully, and I have never yet seen any excess of corpuscles sufficient to satisfy Dr. Wilks' definition of leukæmia. I have seen perhaps twenty to thirty or forty corpuscles in a field, but never more.

Thus far lymphatic disease; I turn, for a minute only, to consider the bearing of these views on splenic leukæmia. This is a disease which, as it seems to me, is quite distinct from lymphadenoma, and yet it does in some measure support the view I have

adopted of the symptomatic relationship of the colourless blood cells to the glandular enlargement.

I may preface that consideration by the following case:—

A female child, ten months old, was brought to the out-patient room at the Evelina Hospital, on March 14th, 1877.

The father was a delicate-looking man, of spare habit, and he stated that he was subject to bronchitis and asthma. He had never expectorated blood and was not wasting. The mother looked healthy; her complexion rather dark. This was their first child. There had been no miscarriages, and no history of syphilis. The child was brought to me because no food agreed with it, and it had the thrush. It had been ailing ever since its birth with diarrhœa and vomiting. It had been both nursed and fed for some months.

Nothing much wrong was detected at first, and it was treated with Liq. Calcis and Oleum Ricini, with directions as to feeding. On April 4th it had got whooping-cough, and then began to waste rapidly; hitherto it had been rather pale but fairly plump. On the 25th it was noticed that it still wasted. Pallor not extreme. The spleen is now large and hard, coming forward nearly to the umbilicus. The liver also is large but not hard. The blood is watery, and there is a considerable variety in the size of the corpuscles, but there is no excess of white corpuscles, only five in one quarter inch field. The liquor sanguinis contains no granules, or very few. There is no evidence of rickets. It was ordered one drachm of the syrup of the lactophosphate of iron three times a day.

May 2nd.—The spleen is very large, much more so and harder than it was last week. It looks pallid, but takes its food well. Stomatitis better. The blood still watery. No excess of white corpuscles.

9th.—Spleen and liver much the same; still very pallid; takes food well.

16th.—Still as pallid as possible; spleen enlarging and very hard chest quite normal.

23rd.—The child has been very ill since the last appearance. Its legs began to swell two days ago, and the last few days the urine has been like blood; it has passed plenty. The cough has troubled her much. Bowels acting regularly. My notes state to-day that she is still very pale, and now has many purpuric spots all over her face, forehead, trunk, arms, and legs. The spleen is still very large,

and the liver also. There is much œdema of the feet. Examining the blood to-day there is a large excess of white corpuscles; they do not nearly equal the red ones, but there are 200 to 300 in each field; I counted 150, and then left off, with many more still visible. The prick in the finger bled so freely that it could only be arrested by matico and pressure. The blood is watery. Chest and heart normal. Bones appear normal. Tongue clean. Takes milk and beef tea, but vomits the latter. It was ordered one drachm of phosphorised cod-liver oil three times a day.

30th.—Still wasting. Much pallor. Purpura and splenic enlargement as before. Has now much cough, and there is much mucus in the tubes at the base of the lungs.

Became worse, with much dyspnœa, and died on June 2nd.

With very considerable difficulty permission was obtained to examine the body. The father stayed in the room all the time lest anything more should be done than was necessary, and to see that nothing was removed. The body was spare—emaciation not extreme. No rigor, still some petechial spots on the trunk and extremities, and on the left leg, below the knee, a large bruise-like stain of blue and yellow.

The head was not examined. No discharge from either ear.

On opening the abdomen, the walls of which were very thin, the spleen and liver were found greatly enlarged. The former of a dark purple colour and very firm, the latter of a paler tint and fatty, or something between the yellow tint of fat and the grey amyloid disease. Its surface was more like a fatty organ, but its thickness, firmness, and section were more like those of an amyloid liver. The vessels of neither organ contained any plugs, and the blood in them was of normal appearance. That in the main trunk of the splenic vein was grumous looking, but except in that spot no alteration in it was noticed, either in the heart cavities, great vessels, or elsewhere. The abdomen contained a little yellow serum.

The kidneys were large, and about twice their proper size for a child of this age, and of a dead white, with ecchymoses all over their surfaces. They looked from the surface as if affected by chronic tubal inflammation, but on section they were hardly yellow enough. They proved to be swollen, and anæmic and ecchymosed, with a small quantity of adenoid tissue between the tubes, and a small extent of tubal catarrh. But on the whole they were good organs.

The mesenteric glands were rather large, but nowhere caseous.

No other glands in the body were diseased. The supra renal capsules were healthy.

Stomach and intestines healthy. Mucous surfaces pale.

Both lungs were pneumonic at their bases, the right extensively so, with old adhesions of the pleura and œdema of the organised lymph. No tubercles. Apices healthy. Thymus still of good size. No mediastinal glandular enlargement.

The heart was rather large; the muscle looked so yellow that I thought it must have undergone some fatty change, but no fatty striations were visible, and under the microscope it was not so. However, the muscular fibre had certainly undergone a very peculiar change; it was very much broken up into small pieces, in many of which there was a central, rather large nucleus, so that the piece of tissue looked like a large cell. It seemed as if the muscle had broken up in relation to the nuclei of the sarcolemma. In addition to this change there was a quantity of amorphous material between the fibres of the muscle, and also nuclei scattered here and there rather plentifully. No true adenoid tissue was found. The valves of the heart were healthy.

Sternum, ribs, and substance of the vertebra healthy. The extremities could not be examined, but from an external inspection they showed no enlargement nor thickening.

Under the microscope the liver was in a very abnormal state, being crowded with small nuclei, which in very many places had displaced the liver cells, and made them form quite an open mesh, in which the new cells clustered in quantity. The disease was so extensive that the parenchyma was in quite as advanced a condition as the tissue in the immediate neighbourhood of the portal channels.

This case would appear to show that enlargements of the spleen may be present for some time before the leukæmic state of blood becomes developed; and this is in harmony with what was stated at the last meeting by Dr. Gowers, that 25 per cent. of the cases of splenic leucocythæmia have had ague. It has been before suggested that ague might have something to do with leucocythæmia, but finding that a very large proportion of cases had never so suffered, that view has not as yet received very general acceptance. But if this range of view were still further enlarged the result, I believe, would be, to procure a wider recognition of its truth. I would take all chronic enlargements of whatever source and say that any such case may at some

time, though by no means necessarily, become leucocythæmic. That this is so is supported not only by the case I have given but by another which I am now watching, and which is I think on the way to leukæmia; and further, by many cases of enlargement of spleen, more particularly as they occur in children. I have for some time past always examined the blood of such cases, and taking seven such cases as they stand—and I have more such, being unable for the time to lay my hands upon them—they averaged from 40 to 60 white blood-cells in each field. Now, though I should certainly not call this excess leukæmia, and so far agree with Dr. Wilks as to the restriction of the term, if I am right in supposing that what we call leukæmia is an advanced symptom, a much slighter excess of white blood-cells may be an earlier one, and it may well be, I think, that some of the very chronic splenic enlargements that we see in childhood may really eventuate in adult life in the well developed leucocythæmia. There is other evidence too on this head. In one of my *post-mortems* there was an enlarged spleen weighing 83oz. It was in a man, aged 46, under Dr. Pye Smith. He had caseous bronchial glands, tubercular disease of the pleura, and tubercle of the liver. Now the concurrence of these conditions seems to prove that the case was one of like nature with the leukæmic cases, but the blood in this patient was normal both in colour and the relative proportion of the colourless corpuscles.

One word with regard to medullary leukæmia. In my own knowledge I have seen only two cases in which any such condition existed. I can readily conceive that the disease might as well start at times from the bones or from other lymphatic organs as from the spleen or glands; but the proof of such cases must come, not, I take it, from the side of mixed cases, such as most of those published by Neumann, Mosler and others, but from the side of those diffused cancers, or rather, soft lymphomas of bone which spread throughout the whole osseous system. But those cases are hard of recognition, and we must wait. At present all I have seen in the bone has been quite consistent with a mere collection of the pus-like blood, so well shown in the heart of the case exhibited to-night, in the bone medulla as a concomitant of the collections in other viscera.

Lastly, if one may trench on treatment from a strictly pathological standpoint, I would add that if lymphadenoma is an infective disease and local at its onset, why not remove it rather than let it go on infecting? The previous failure of such operations does not

necessarily militate against their repetition on suitable occasions, because non-success only shows that in removing a symptom the cause is not touched. But at present in many cases too numerous unfortunately to need mention, while searching for the cause we must treat symptoms. *April 2nd*, 1878.

---

6. *Two cases of Hodgkin's disease of the glands; leucocythæmia; lymphadenosis.*

By Surgeon-Major J. H. Porter, of Netley.
(Communicated by the Hon Secretary.)

Driver J. H—, Royal Artillery, æt. 35, was admitted into Netley Hospital on the 2nd of February, 1876. He had been in the artillery as a driver for nearly six years, and prior to enlistment was a bricklayer.

All his family are alive except his father and sister; the father died in an apoplectic fit and his sister from consumption. All those alive are healthy. He is unmarried.

Past history.—In youth he had measles, but never scarlet fever or rheumatic fever. Soon after enlistment he contracted a chancre near the frænum preputii, which lasted about a month, and was treated locally by "black wash;" he had no constitutional treatment. The chancre was followed by a scaly eruption which has lasted to the present time, being worse while serving in hot climates; with the eruption he had a sore throat which continued for three or four months.

Two years ago, while at Kirkee, Bengal Presidency, he had another venereal sore, this was on the foreskin, and was what he calls a "hard chancre;" this was also treated locally by black wash. The skin eruption became worse and the throat was again sore. He had a suppurating bubo on the left side. About a month after the sore had healed, he noticed the left supra-clavicular group of glands were swelling, but were neither painful nor tender; this was followed soon after by a similar enlargement of the right side. About six weeks after noticing the first swelling, the right axillary glands enlarged, which were soon followed by the left, and then the glandulæ concat-

anatæ of both sides enlarged, a little later on those situated over the rami of lower jaw and the occipital and right submaxillary groups became affected. The sore throat disappeared as the glands enlarged, but there has always remained a hot, dry state, giving rise to a harsh, rasping cough, which is spasmodic. He was a hard drinking man after enlistment in England, but had to discontinue it in India as it increased the cough. He smokes but little and this does not affect the throat.

Present state.—Patient is a well-built man, of fair complexion, lymphatic temperament, of fair nutrition, with but small amount of muscular development, and rather debilitated. The hair on his head is thin and there is none on his face. His skin is pale and sallow, but the conjunctivæ are fairly well injected. There is a scaly syphilide scattered over his trunk and limbs. On the left side of the neck are two swellings, one situated over the angle and ramus of the jaw and a little below it, is about the size and shape of a common hen's egg, the other, lying just above the clavicle, is oval in shape, being concave towards the neck, convex above, and externally, and somewhat overhangs the clavicle; its length is 6 inches and width 3, and it has the appearance of two clenched fists together. It is posterior to the sternomastoid. On the right side of the neck are two similar groups, but with these exceptions that the upper swelling is joined to the lower by an enlargement over the sternomastoid, and this makes a much more extensive enlargement, measuring from above downwards and forwards in its longest diameter 5 inches, horizontally from before backwards 5 inches, and has a depth of about 2 inches. There is also continuous with this an uniform enlargement of the tissues beneath the right lower jaw. The right axilla contains a tumour as large as the head of a newborn child, measuring horizontally from before backwards 9½ inches, and perpendicularly 8 inches; this is rather more uniform in outline than the cervical enlargements. It pushes out the scapular muscles behind and pectoralis in front. The glands below the clavicle and beneath the pectoralis major have also become enlarged, being separated from the cervical group by a groove corresponding to the clavicle, but below are joined to the axillary group.

There are similar tumours on the left side and of the same dimensions. His condition is remarkably well shown in Plate XVII.

The occipital glands are slightly enlarged. The measurement of

DESCRIPTION OF PLATE XVII.

This plate is from a photograph taken by Surgeon G. Dobson, A.M.D., of a soldier with Lymphadenoma affecting chiefly the glands of the axillæ and neck. Case related by Surgeon-Major Porter at page 335.

Hodgkin disease

100 – 1 This is Leukemia!

R. Mintern lith.

Mintern Bros imp

the base of the neck gives a circumference of $28\frac{5}{10}$th inches, while the greatest circumference of the chest gives $43\frac{5}{10}$th inches. The swellings are hard and nodular on the surface, with the skin somewhat tense over them but movable; there are large blue veins crossing in all directions over them; with the exception of the right cervical group, they are free from pain or tenderness.

The axillary swellings sometimes give rise to numbness in the upper limbs. The inguinal and femoral glands are easily perceptible to touch but are not visibly enlarged.

The whole of the front of the chest is œdematous, as is also the scrotum, and the right foot and lower half of leg.

He is obliged to assume a sitting position for repose, and sometimes spends the night in a chair, because the pressure from the cervical tumours causes a harsh, rasping dry cough, which comes on in violent spasms, and causes his breathing to be rapid and shallow.

The liver apparently is normal. He complains of a heavy, dragging pain in his left side in the region of the spleen, which prevents him from lying on that side, but examination does not reveal any splenic enlargement.

His stomach troubles him a good deal from large accumulations of flatus.

On examining the blood, there is no lack in the number of red corpuscles, nor is there any diminution of their colouring matter, but there is a large increase of white corpuscles of varying sizes, to eighty in a square hundredth of an inch.

There are here and there small collections of granules, having the appearance of a ruptured white corpuscle.

The organs of special sense are healthy. The urine is loaded with amorphous urates, but is otherwise healthy.

His temperature is normal; great thirst and copious perspiration are persistent. His thirst is so intense that he is unable to move about without being accompanied by a vessel containing some kind of fluid to relieve it. The illustration would therefore be incomplete were the jug at his feet not represented.

The treatment at first consisted of a pill containing one twelfth of a grain of muriate of baryta daily, and the tumours were smeared with glycerine and iodide of potassium. This treatment gave way to vapour baths of calomel, 20 grains daily, but after two or three they had to be discontinued, as the œdema became worse. After a lapse of about a week without treat-

ment, he had $\frac{1}{12}$th of a grain of the perchloride of mercury twice a day, but as this soon salivated him it was discontinued for a time, although he was improving under its influence; it was afterwards given once a day, but constitutional treatment seemed to be of no avail, for the disease progressed steadily though slowly. He had to be given hypodermic injections of morphia daily, varying from $\frac{1}{4}$ to $2\frac{1}{2}$ grains. Occasional applications of poultices to tumours had a marked effect in relieving pain. This patient died of erysipelas of the face and neck. A *post-mortem* examination was not made.

Case 2.—Corporal D. Hill, 2nd Bat., 12th Regt. This man was admitted into the Royal Victoria Hospital on the 8th February, 1878. He was born at Linton, in Cambridgeshire, of healthy parents. Mother died in child-birth when he was only three years of age. Father is a labourer and is healthy; he is fifty-five years of age.

He states that he never had any illness previous to enlistment, with the exception of hooping-cough. His first admission into hospital was in May, 1874, when at the Curragh; he was admitted for "inflammation of glands." He states that the glands in the left groin were those affected. He was twenty-one days in hospital, and when he was discharged all swelling had subsided. He states that during this time he had a small wart on his penis, which he pulled off. In October, 1874, when at Ferozepore, he was thirty-nine days in hospital with gonorrhœa. In December, 1876, when at Calcutta, he was admitted into hospital with "rupia," which disease was changed on the 5th of May, 1877, to "psoriasis" (lepra), and again on the 18th September, 1877, to "elephantiasis."

He states that when admitted into hospital with "rupia" his hair commenced to fall out; at that time he was treated with mercurial vapour baths, &c., iodide of mercury internally, and subsequently with arsenic, cod-liver oil, tonics, &c.

He states that in March, 1877, he noticed for the first time a small lump under the lower jaw at the left side, and that soon afterwards the right side became similarly affected. These lumps gradually increased in size and spread round to the back of his neck, and also downwards to the clavicle soon afterwards, but how soon he cannot remember. The glands in the groins and in the axilla became enlarged, and gradually increased in size until they got to their present state, which is well represented in illustration (Plate XVIII). He does not think there has been any alteration in them for

DESCRIPTION OF PLATE XVIII.

This plate, also taken from a photograph, illustrates Surgeon-Major Porter's observations on a case of Lymphadenoma (page 338). The glands of the groin, axillæ and neck are much affected, the scalp is much thickened and wrinkled, and the hair over the body generally has in a great measure disappeared.

Hodgkin's disease

R. Mintern lith.

Mintern Bros imp

some time. His weight when he first went into hospital in December, 1876, was 10 stone 8 lbs., he now, February 23rd, 1878, weighs 8 stone 7 lbs. He is in a very emaciated condition; skin is of a dusky brown colour in all parts of his body and extremities. On his head it is also very much thickened, and is in large wrinkles, or rather furrows, which are most marked in the occipital region; the measurements of the head, taken on 23rd February, are, around the head just over the eyebrows, 21½ inches; over the mouth, 21 inches; just below chin, 19 inches; over cricoid cartilage, 16 inches; round base of neck, 18 inches.

These figures do not convey the impression that the glands are much enlarged, unless his emaciated condition is taken into account. The glands in both the occipital and cervical regions are much enlarged, and the cellular tissue of the neck seems to be much thickened. The glands in the axilla are formed into one large tumour on either side, and when the arms are held above the head, measure from above downwards, on the right side, 6 inches, and on the left, 5 inches; and laterally 4 inches on the right, and 3 inches on the left side. They are about 2 inches in thickness on the right, and 1½ inches on the left side. They have a nodulated appearance, and are soft to the touch, and are not adherent to the skin or to subjacent tissues.

The glands in the groins are formed into similar tumours, and are of the same size in both groins, measuring from above downwards 6½ inches, and laterally 5 inches, and are about 2½ inches in thickness. They fill the whole of Scarpa's triangle, *but do not extend above Poupart's ligament.*

There is also an enlarged gland just above the inner side of the left elbow on the anterior aspect of the arm; this gland is circular in form, and about 1 inch in diameter. He has not any pain in any of these glands, even on pressure. All the other glands of the body are normal. He has lost all the hair that was on his body, and has very little on his head, and scarcely any on his face.

The spleen and liver do not seem to be enlarged. The testicles appear to be normal.

The tonsils are slightly enlarged, and the whole of the soft palate and pharynx are œdematous. There is a rather large fissure on the middle of the tongue on its upper surface.

He states that he feels in fairly good health; his appetite is good, and his bowels regular; urine sp. gr. 1023, strongly alkaline, very ammoniacal, copious deposits of phosphate, a trace of albumen.

On the 20th of March, 1878, the positions, as before mentioned, were again measured. Over the mouth, 22 inches; just below chin, 21 inches; over cricoid cartilage, 17½ inches; round base of neck, 18½ inches.

He has been suffering from great thirst and spasmodic cough, both due to local causes, the former from the diminution in space between the tonsils, causing dryness of the tongue, and the latter from pressure on the recurrent laryngeal nerve.

Since admission he has had large doses of iodide of potassium, iron, iodide of iron, and cod-liver oil, but without any benefit.

Added Note.—In May, 1878, phosphorised cod-liver oil was administered to this soldier, at the suggestion of Dr. Douglas Powell. Since then, now five months, he has taken upwards of 12 lbs. of it with marked benefit.

The glands, especially those in the neck and axilla, have become greatly reduced, thirst less, not so drowsy, and more active in his habits. His skin has a peculiar Indian-red appearance, but this was coming on before the administration of the phosphorus. He now measures over the mouth 20½ inches; just below the chin 17½ inches; over cricoid cartilage 15½ inches; round base of neck 16¼ inches; weight 9 st. 5 lbs.

There is considerable improvement in these measurements since March 20th, 1878. He has had an attack of jaundice, which disappeared on the oil being omitted.

The phosphorised cod-liver oil was obtained from Savory and Moore, and contains one fifth of a grain of phosphorus to the ounce.

Netley, Sept. 21*st*, 1878. J. H. P.

Report on the appearance of the blood in Case No. 2, *by Surgeon-Major Boileau, Assistant Professor of Pathology, Army Medical School.*—With regard to the microscopic appearances presented by the blood of Corporal D. H—, I have examined on four different occasions some drops taken from the tips of his fingers, about two hours after his breakfast.

In a field of view measuring 1-100″ in diameter, I have counted varying numbers of white corpuscles, such as 4, 9, 10, 15, 21, 26, 32, 36, 43, 49.

I may safely say that the proportion of red to white corpuscles in his blood is *over* 100 to 1.

On comparing his blood with that of other men, under similar

circumstances as to time, &c., but free from the suspicion of any leukæmic disease, I find in his blood a decided excess of white corpuscles. *Netley, April 4th*, 1878.

Short abstract of the case of Private D. M—, who died on the 3rd May, 1873, *aged* 26. *Vide No.* 75, *volume* xii, '*Netley Pathological Reports.*'—The patient, having served for eight years in the army, was invalided from India, where he had had ague. Whilst in Netley Hospital he suffered from dysenteric diarrhœa. He died very suddenly after eating his dinner.

There was no history of hereditary disease or syphilis.

Autopsy.—Opaque patches, size of peas, universally dispersed in the calvarium, apparently of the same nature as the growths elsewhere.

Dense thickening of tissues over lumbar vertebræ in connection with enlarged lumbar glands.

Considerable effusions distend pleural cavities.

Enlargement and induration of mediastinal glands; "enormous numbers" of them. Size, that of a small marble.

A large mass of glands embrace the root of the right lung, which centrally presents an aggregation of growths from the size of a pin's head to that of a walnut. Such growths cause pleural projections also. Apex free from such. Similar nodules in left lung.

Over the internal surface of the pericardium are widely dispersed growths; small, firm and translucent. In the pericardium externally there are similar formations.

Lumleian glands enlarged, forming two elongated masses.

Mesenteric, iliac, and pelvic glands enlarged.

Abdominal main blood channels compressed and constricted by these glandular growths.

Surface erosion of mucous membrane of ascending colon.

Liver enlarged; sections present small nodules from the size of a pin's head to that of a pea.

Spleen enlarged; its substance permeated by very numerous growths, from the size of a pin's head to that of a walnut.

Condyles of femur contain growths of the same character as elsewhere.

7. *Drawings of organs, with microscopical sections, from cases of Hodgkin's diseases and allied conditions.*

By F. C. Turner, M.D., for Dr. Sutton. (From the Pathological Department of the London Hospital.)

The first drawing showed the appearance of the enlarged soft glands in the early stage, from a case of Hodgkin's disease. (Case 2 amongst those described below.) The glands are seen in section, and the drawing shows the white new material in areas surrounded and mapped out by tracts of hyperæmic tissue, spotted with ecchymoses.

Drawings 2 and 3 showed the two forms of enlargement of the spleen met with in the cases under discussion. No. 2 represents the spleen of a patient who suffered from the lymphatic form of the disease. (Case 3, Warren.) In this case there were considerable and extensive glandular enlargements, and great enlargements of the spleen, from the development in it of the opaque white masses shown. In the report of the autopsy their appearance is compared to that of porcelain. The drawing gives a very faithful representation of the appearance of the organ; it weighed 22½ oz. (See Plate XIX.)

Drawing No. 3 represented the enormously enlarged spleen taken from the body of a boy, L—, aged 16. In this case (Case 8), the clinical aspect was that of splenic disease. There was little glandular enlargement, and no pallor, but the peculiar yellow complexion of "splenic cachexia." The spleen weighed 4½ lbs., and had somewhat at first sight the appearance of the "sago spleen," but there was no reaction with iodine. There was a history of ague. There was no important degree of leucocytosis.

Drawings 4 and 5 showed the size and very remarkable appearance of the kidney found in these cases. Drawing 4 was taken from the kidney of a typical case of Hodgkin's disease, or anæmia lymphatica, occurring in a boy aged 10 (K—, Case 1, below). He had general enlargement of the lymphatic glands, the spleen being somewhat enlarged but normal in appearance (it weighed 6 oz.). The kidneys weighed 19 oz. and 19½ oz. respectively. The cortical tissue, as shown in the drawing, was greatly swelled, and had a

DESCRIPTION OF PLATE XIX.

The drawing in this Plate is of an enlarged spleen, from a case of Hodgkin's disease, and illustrates Dr. Sutton's observations. (See page 342.)

E. Burgess ch. lith.

W. West & Co. imp.

yellowish-white colour, mottled with points and patches of ecchymosis. There were hæmorrhagic extravasations in various parts of the body.

Drawing 5 was taken from the kidney of the boy L—, whose greatly enlarged spleen was shown in drawing 8. The appearances correspond with those seen in drawing 4, excepting that there had been no hæmorrhagic extravasations. To this case the names neither of Hodgkin's disease, nor of anæmia lymphatica can be properly applied.

Under the microscope were exhibited sections from various organs from the last-named patient, and from four other patients who have died from this form of disease in the London Hospital during the last few years, showing very distinctly the histological characters of the lymphadenoid growth invading them.

In the hope of obtaining facts which might throw some light on the subject under discussion, Dr. Sutton and Dr. Turner had looked through the post-mortem records at the London Hospital for the last eleven years. From them they had collected particulars of nine cases, well-marked instances of the diseases illustrated by the drawings and specimens exhibited.

There are (1) seven cases in which there were extensive enlargement of the lymphatic glands of the kind found in Hodgkin's disease, with comparatively little enlargement of the spleen, or more marked splenic enlargement, due to the presence of defined nodular masses disseminated through its substance; and (2) two cases in which there was an enormous enlargement of the spleen of an apparently simple or merely fibroid nature, without any very noticeable affection of the glands.

Abstracts of these cases are here given.

Case 1.—*Anæmia lymphatica, Hodgkin's disease; general enlargement of glands, hard and soft; kidneys enlarged and infiltrated; purpuric eruption.*

John K—, æt. 10. Admitted into the London Hospital, February 5th, 1867, under the care of Dr. Andrew Clark; died April 5th.

Autopsy.—Great glandular swelling under the jaw on both sides. Axillary and inguinal glands considerably enlarged. Purpuric spots over the body; œdema of legs and thighs; body emaciated. Ecchymoses in pleuræ and pericardium. A large lobulated mass occupied the anterior and middle mediastina, apparently composed of a mass of

enlarged glands amalgamated together. The section yielded a creamy juice when scraped, and the tissue was in parts deeply injected with blood. The glands in the neck were some of them of a similar soft consistence, and some of them firm and indurated. The apex of the left lung was puckered, and contained a cheesy, partly cretaceous nodule, of the size of a bean. At the apex of the right lung, also, was a cheesy-looking mass, of the size of a small marble, and a nodule of extravasated blood, the centre of which had begun to undergo cheesy metamorphosis. The lungs were greatly congested, and studded with points of ecchymosis.

The liver weighed 3 lbs., it was of a normal appearance, and no deposit was found anywhere in it. The spleen weighed 6½ oz. and appeared healthy. The kidneys weighed 19½ oz. and 19 oz. respectively. The cortical substance was greatly swelled, and had a yellowish-white colour, mottled with points and patches of red. The mesenteric and lumbar glands were universally enlarged; the smaller ones pale and firm; the larger ones (some exceeding the size of a walnut) were lobulated and intensely injected, studded with patches of extravasated blood, and containing whitish, semi-transparent masses, which exuded a milky fluid.

CASE 2.—*Hodgkin's disease; fatty degeneration of the heart; thrombosis of the iliac veins; embolism of the middle cerebral artery; old disease in the lungs, caseous and fibroid changes; a mass of glands compressing the right bronchus; spleen enlarged.*

William S—, æt. 36, was admitted April 4th, 1871, and died June 6th, under the care of Dr. Ramskill; a large, well-made man; a hard drinker, with a history of syphilis. His illness dated from nine months before admission. Then he complained of "feeling sick after his tea," and swelling of foot, subsequently also shortness of breath, increasing nausea, and loss of flesh. When admitted the whole left leg was œdematous; he had nausea after any food, shortness of breath, sweating at night, and occasional vertigo. The glands in the groins, axillæ, and neck were enlarged, some hard and some soft. The number of colourless corpuscles in the blood was found to be increased. There were also signs of pressure on the right bronchus. Spleen enlarged; skin remarkably white; a systolic bruit at the base of the heart, "probably anæmic." There were also retinal hæmorrhages in right eye. Two days before his death he became delirious, with left hemiplegia. His temperature, at first normal, was

found persistently raised during the last ten days of his life, but without any regularity. It varied from 101° to 104°.

Autopsy—The mesenteric glands were enlarged and very conspicuous; they were firm, and grey on section. There was a mass of enlarged glands along the lumbar spine, encircling the aorta and vena cava; some of these were as large as an egg, many as large as a good-sized walnut. They were moderately firm, and on section showed grey portions fading imperceptibly into deep red tissues, giving the whole a mottled appearance. Some of these glands were very soft, deep red, with very little grey material. The section yielded a milky juice when scraped. The enlarged cervical glands were much firmer than those in the abdomen. The left iliac vein, and the right bronchus were compressed by masses of glands. The spleen was larger than normal; it contained several ill-defined masses of firmer consistence than the rest, of the size of a shilling. There was fibroid induration in the puckering at the apices of both lungs; a cheesy-looking mass of the size of a hen's egg in the apex of the right lung, surrounded by pigmented tissue. There was fatty degeneration with dilatation of the left ventricle of the heart. No other important changes were observed in this or other organs.

CASE 3.—*Lymphadenoma; enlargement of the lymphatic glands of the lower limbs and abdomen, and of the neck; enlargement of the spleen, with white nodules in its substance.*

Mary Ann W—, æt. 38, admitted on account of pains across the back and down the right leg, which came on suddenly three months before. It extended down to the toes, and lasted at first about a quarter of an hour, but it had continued in less degree up to the time of admission. The leg had been swelled for a fortnight with some diminution of the pain. She had been confined five months before admission. It was a difficult labour, version being necessary. Her right leg had been numb before her other confinements. The swelling had commenced in the thigh and extended down to the foot. The swelling subsequently appeared in the left leg.

Autopsy.—Body greatly emaciated. The lower extremities and trunk œdematous. The lymphatic glands in the abdomen and groins were greatly enlarged, and formed a continuous mass. On section they were soft and like normal glands. No hæmorrhagic extravasations, and no retrogressive changes observable. The

cervical glands were similarly enlarged to a less degree. The spleen was considerably enlarged, and rounded in outline. On section groups of dead white nodules, like porcelain, of the size of hempseed, were seen at various points. The organ weighed 22½ oz. No important changes were observed in the other organs. The appearance of the spleen was shown in one of the drawings exhibited.

CASE 4.—*Hodgkin's disease; masses of growth in spleen, liver, kidneys, right lung, pleura and pericardium; enlargement of cervical, bronchial, and lumbar glands; dysentery; pericarditis and pleurisy (old).*

Charlotte H—, æt. 24, was admitted September 16th, 1873, and died October 3rd., 1874. Under the care of Dr. Ramskill. She had been ailing two years before death. Her first symptom was faintness after food about 18 months before death; then morning retching, with shortness of breath and stabbing pains under left mamma and between shoulders, and loss of flesh. At the time of her admission the spleen was found to be enlarged. Subsequently some pleuritic friction was heard on the left side of the chest. Pains in the legs and ankles were complained of, and some œdema appeared. Latterly diarrhœa came on, with straining, and ulceration of the mouth.

Autopsy.—Body exceedingly wasted. Cervical glands enlarged; some firm, others had softened down and contained a greenish yellow, opaque fluid. The bronchial, mesenteric, and lumbar glands were also enlarged. The spleen was very much enlarged and firm; it contained a number of greyish yellow, semi-gelatinous nodules disseminated through it. Similar grey bodies were scattered throughout the substance of the liver; a few also in the kidneys. The pericardium and both pleuræ were much thickened and firmly adherent. Imbedded in the tissue between the layers were a number of greyish nodules of the size of a pin's head. Similar bodies were disseminated throughout the right lung. There was extensive dysenteric ulceration of the colon.

CASE 5.—*Hodgkin's disease; general enlargement of the lymphatic glands; spleen also enlarged.*

Thomas C—, æt. 58, was admitted under the care of Dr. Ramskill, on February 25th, 1875, and died April 16th. He had been subject to enlargement of the cervical glands from a child. He had had typhus or typhoid fever, and four years before admission he had had acute rheumatism. The fatal illness dated from between two and

three years back, and commenced with swelling of the cervical glands, attended with anæmia and loss of flesh. The appearance of the glandular swellings in the axillæ and groins dated from ten months back, and during this time the loss of flesh and pallor had become more marked. When admitted there were masses of enlarged and hard glands in the neck, axillæ, and groins; the glands could be moved upon one another. The spleen and liver were enlarged and firm. There were periosteal nodes on the tibia; the legs and feet were œdematous. The arteries were very degenerate. The urine had a low specific part, but contained no albumen. The temperature was found to be slightly raised (99° to 101°). There was shortness of breath, and signs of effusions at the base of the left chest.

At the autopsy, enlargement with induration of the cervical, axillary, inguinal, mediastinal, and mesenteric glands, and also of the spleen was found. The root of the left lung had been compressed by the enlarged mediastinal glands, and there was effusion of fluid into the pleural cavity. The liver was large and firm, and the kidneys normal in appearance.

In this case sections from the one of glands, spleen, liver, kidney, lung, and brain were examined under the microscope. The sections from the spleen and from one of the enlarged lymphatic glands, showed a marked degree of coarseness in the fibres of the reticulum of the structures. In the liver and kidney the adenoid growth was distinctly seen; in the former organ it followed the portal tract; in the latter it could be distinguished in a few places only. In both these organs the vessels were seen mapped out with rows or masses of colourless corpuscles. In the brain many vessels were seen similarly mapped out, but no distinct adenoid growth could be detected. In the lung a similar condition of the vessels was conspicuous, and masses of leucocytes were moreover seen filling many alveoli. These were seen to be infiltrating masses of blood-clot which occupied the air-cells. Many air-cells were filled with simple blood-clot.

Case 6.—*Hodgkin's disease; enlargement of the spleen, with nodules disseminated through it; similar nodules scattered through liver and over right pleura; enlargement of lymphatic glands.*

George B—, æt. 32, was admitted under the care of Mr. Hutchinson January 22nd, 1876, and died March 14th. He had suffered from venereal disease seven years previously. Five months before

admission he had been laid up with pleurisy, and afterwards with inflammation of the lung. He had returned to work between the illnesses, and subsequently to the latter. A fortnight before coming to the hospital, and two days after an eruption of "nettle-rash," both his eyes became inflamed. He was taken in on this account. There was found to be inflammation of all the coats of the eyes, with much pain. One eye was removed on February 14th. On February 17th great pain was complained of in the lower part of the back, which disturbed his sleep. On March 8th there was also a sensation of constriction round the abdomen, and anxiety of countenance. The liver was then observed to be enlarged, but not tender. Subsequently the patient became jaundiced. He became greatly prostrated, and died on March 14th. He had become much emaciated while in the hospital.

The autopsy showed enlargement of the lumbar and bronchial glands, and slight enlargement of some of the cervical and axillary glands. A mass of enlarged glands was found in the portal fissure, which had compressed the common bile duct and produced the jaundice. The spleen was enlarged and contained nodules of a greyish-yellow colour and firm consistence, resembling parsnip, scattered through it. These nodules were irregular in shape, and varied in size from that of an ordinary tubercle to that of a pea. The liver was also enlarged, and contained nodules of similar appearance scattered throughout it. In the centre of the right lobe was a large mass of the same material. None of the nodules were at the surface. The diaphragm was invaded and thickened by a similar deposit, and adherent to the lung and liver. The right pleura was studded with nodules of the same kind. There was pleuritic effusion into the right pleural cavity. No deposit in the lungs. The other organs appeared normal.

In this case fine sections from one of the enlarged glands, from the spleen, liver, kidney, lung, brain, and spinal cord, were obtained.

In the lymphatic gland those parts which still retained their normal characters were exceedingly coarse in the fibrils of the reticular meshwork; large portions of the section were converted into a fibrous tissue, with only a few cells or nuclear bodies. Other parts were in an intermediate condition. Amongst the small round cells, normal to the tissue, were many large and very conspicuous cells of round or oval form, and having a considerable amount of protoplasm round the nuclei. The condition of the spleen was

found to be very similar; in parts a fine reticulum was seen occupied by leucocytes of normal appearance; in other parts, which seemed to correspond with the nodular masses seen by the naked eye, were very fibrous, with few nuclei; in other parts, again, a coarse and wide meshwork was seen, containing large cells, many of them polynucleated, similar to those seen in the lymphatic glands. This open meshwork was seen to be arranged continually round transverse sections of the arteries. In the liver numbers of lymphoid cells were seen around the ducts and vessels, surrounded by an unusual amount of fibroid tissue. This growth was seen to be in very circumscribed masses corresponding with its nodular arrangement exhibited at the autopsy. In the lung also small areas of similar fibro-nucleated tissue were seen here and there. The sections from the kidney, brain, and cord showed no marked morbid changes. In none of the sections from this case was a filling of the vessels by leucocytes noticeable.

CASE 7.—*General glandular and splenic enlargement; a mass of growth in the anterior mediastinum (? thymus); great enlargement of the kidneys through invasion by lymphoid growth; ecchymoses in pericardium, peritoneum, dura mater, pia mater, kidneys, and retinæ; hæmorrhage from mouth, nose, and stomach; leucocytosis* ($\frac{1}{12}$).

Frederick C—, æt. 15, was admitted April 2nd, 1877, and died May 12th. Under the care of Dr. Woodman.

The patient had been dull and apathetic during eighteen months, since an injury to his head. The fatal illness dated from three months before his admission. He had pains in left leg (rheumatic), extending to left arm; also some deafness, with ringing in his ears. After admission some frontal headache and defective sight were complained of, and about a fortnight before death amaurosis, deafness, vertigo, and constant vomiting; also hæmorrhage from nose and mouth, and hæmatemesis occurred. No swelling of joints. The glandular enlargement in neck, axillæ, and groins were observed after admission, with enlargement of spleen, and double optic neuritis, with hæmorrhages. There was marked anæmia, with a great increase in number of colourless blood-corpuscles (1 to 12). A trace of albumen was observed in the urine a fortnight after admission, with pus-like cells, but not subsequently. The temperature varied from 98° to 100°, rising to 102°, but without any regularity. Shortly before death the glandular swellings almost entirely disappeared.

Autopsy.—The spleen weighed 12 oz.; it was soft and fleshy. The lymphatic glands in the groins and the lumbar glands were enlarged, some dark and hæmorrhagic, others pale, and mottled by congestion. A large mass of growth occupied the anterior mediastinum, pushing down between the sternum and pericardium, the structure resembling a parsnip on section. The kidneys weighed 19 oz.; the cortical substance was with difficulty distinguishable from the medullary part; it was an inch in thickness, and presented an appearance in section similar to that of the mediastinal mass of growth, except in being mottled by patches and points of hæmorrhagic extravasation. In the liver were some nodules of a semigelatinous consistence. In the lungs were a few hard pigmented nodules, of the size of peas. Ecchymoses were found over the pericardium, peritoneum, dura mater, optic discs, and retina, and one small patch in the pia mater, over the cerebellum. In this case microscopical sections from one of the lymphatic glands, the spleen, liver, kidneys, lung, brain, and spinal cord, were examined.

In the kidneys the morbid changes were extremely advanced, and the appearances seen were very characteristic. The tubules were readily distinguished by their epithelium differing in appearance from the growth. The only noticeable alteration of it was the granular appearance of the internuclear substance, and a confused appearance, such as is commonly seen in congested and other kidneys. The basement membrane was distinct, the morbid growth being intertubular. Where there was but little growth a number of lymphoid corpuscles, one or two rows in breadth lay between the tubules. The capillary walls could be made out, and some of these bodies were evidently within the capillaries, others lying along their walls. It is a striking feature that the lymphoid corpuscles were arranged in single rows, in a very orderly manner, forming borders round the basement membranes of the tubercles. The regular arrangement of the border round many tubercles attracted attention. Where the growth was extensive there were many rows, and they appeared less regularly arranged. The intertubular tracts were here very broad, but they seemed merely to have separated the tubercles, these appearing normal, not compressed at all. The lymphoid growth was aggregated in large quantities round many of the Malpighian capsules, and seemed to have invaded them along the vessels.

In the liver continuous tracts of a similar growth were seen running

along the portal tracts and separating the lobules; leucocytes were to be seen scattered through the lobules. Owing to the haziness of the sections from defective preservation of the structure the fibrous stroma of the lymphoid growth could not be distinctly seen.

In the spleen and lymphatic glands swelling of the stroma was seen, with great increase of the cellular elements, changes much resembling those which may be found in inflamed lympatic glands.

In the lung the alveolar walls were seen thickened by infiltration of leucocytes, but no lymphoid growth could be distinguished.

In the brain masses of leucocytes were seen clustered on the coats of some of the arterioles, and filling the interior of others.

In the cord no marked morbid changes were observed.

CASE 8.—*Great enlargement of the spleen; kidneys greatly enlarged from invasion by lymphoid growth; some enlargement of the lymphatic glands.*

George L—, æt. 16, was admitted under the care of Dr. Ramskill, September 5th, 1873, and died December 12th. He had lived in a low marshy district in Essex all his life, and had had an attack of ague at the age of four. He had lived five years after this in a workhouse. When thirteen years old he went to work on a farm. At that time he suffered from headache and pains in his left side, just below the ribs, which prevented him from sleeping, and ultimately compelled him to leave off work. Two years before coming to the hospital he had been squeezed between a horse and a beam. He was laid up two days, and it was soon after this that he noticed a "lump in his belly," which has been gradually increasing.

When admitted he was badly nourished, and his skin had the peculiar yellowish-brown colour seen in cases of splenic diseases. The conjunctivæ were not yellow nor anæmic. The lips and tongue were red. On the left side of the abdomen the very greatly enlarged spleen was found, coming down from under the ribs, and extending across the abdomen to the right iliac fossa. The axillary and inguinal glands were somewhat enlarged. The temperature was raised, varying from 99° to 100°, without regularity or periodicity. About a month before his death his feet began to swell, the swelling gradually extending upwards. The day before he died symptoms of peritonitis suddenly appeared. In the blood there appeared to be some increase of colourless corpuscles. It was examined several times.

Autopsy.—There was no œdema. There was a quantity of morbid serum in the peritoneal cavity, with a congested appearance of the intestines. There were two or three enlarged glands in the anterior mediastinum. The bronchial glands were also large. There was a little pleuritic exudation under the lower lobe of the left lung. The heart weighed 11 oz., the left ventricle being hypertrophied. The spleen weighed 4½ lbs.; it was firm, and on section it looked compact, at the first glance somewhat like a lardaceous spleen, but it did not stain by iodine like a lardaceous organ. The liver weighed 6 lbs. 14 oz.; its appearance otherwise was normal. The kidneys were very large, weighing 17 oz. and 18 oz. respectively. Their surfaces were uneven and very pale. On section they had the characteristic yellowish-white, parsnip-like appearance, their structure being indistinguishable owing to the new material having invaded and obliterated much of the medullary and cortical demarcations. There were no hæmorrhages nor ecchymoses. The brain weighed 65 oz.; it was remarkably firm, and looked as if it had been infiltrated and stiffened by some solid material, its outlines being exceedingly well defined. The convolutions were flattened, denoting that the brain substance had been compressed, while its great weight indicated an increase in its material. On section it looked as if infiltrated with some waxy-looking substance.

Microscopical examination.—In the kidney the appearances are similar to those seen in the last case. The lymphoid corpuscles appear more orderly, and seem to be arranged more in cylindrical spaces three, four, or more rows deep, between tubule and tubule.

In the spleen there is a very great increase of the fibrous stroma. The nuclear bodies are large and well defined. There are broad strands of very fibrous structure, with parallel elongated meshes, occupied by leucocytes. Venous channels are seen plugged by leucocytes. In the lymphatic glands the reticulum is also seen to be coarse, and the same condition of the vessel is very conspicuous in parts of the section. (See Plate XIXA, fig. 2.)

In the brain this plugging of the vessel by leucocytes is a most striking phenomenon. Trunk vessels and capillaries are seen charged with these bodies, dividing and subdividing and intersecting the convolutions in every direction. This appearance is seen in the cortex especially. It is difficult to determine to what extent there is lymphoid growth around the capillaries. In some parts it would seem that this is present, lymphoid corpuscles being scattered along

DESCRIPTION OF PLATE XIXA.

Fig. 1 illustrates Dr. Ridge Jones' case of Hyperplasia of Axillary Glands with Leukæmia. (Page 368.) From drawing by Dr. Whipham.

The figure is drawn from a section of axillary gland showing proliferation of epithelial cells with fibrous tissue in excess.

Fig. 2 shows the microscopical characters of the lymphatic glands in Case 8 of Dr. Sutton's (page 352). The reticulum is seen to be coarse, and a vein is represented partially blocked by leucocytes.

Fig. 1

× 300

Fig. 2

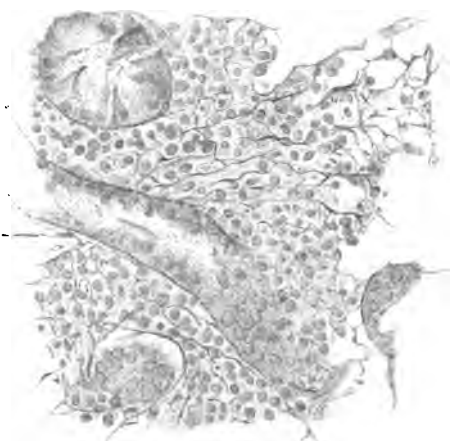

× 290

Mintern Bros. Lith.

the perivascular canals. It is noticeable that there are no heaps of extravasated leucocytes such as are commonly seen, and there are no colloid bodies (albuminous exudation). The matrix network looks granular and confused.

In the intestine also extensive tracts of the same lymphoid growth are seen, widely separating the follicles, without disturbing their contour by compression.

CASE 9.—*Great enlargement of the spleen; liver and kidneys enlarged; cirrhosis of the left lung, with dilatation of bronchi; right ventricle of heart dilated.*

Arthur H—, æt. 17, was admitted under the care of Dr. Sansom, April 7th, 1876, and died November 1st. A wasted, anæmic youth, with anchylosis of the right shoulder and contraction of the left chest, and an enormous splenic tumour.

When a child he had attended as an out-patient at the Great Ormond Street Hospital, with an abscess about the right shoulder and pleurisy. Six years before admission he had been ill thirteen weeks with scarlatina, followed by dropsy. He had been always subject to cough, which was worse in winter. Between three and four months before admission he had been noticed to be getting stout, and he then observed a lump in his left side. Of late he had had pain in his left side, shooting up into his chest. He had lost flesh, and had had night sweating. About the time the tumour was observed he began to find his mouth filled with blood on awaking in the morning; he began also to be troubled with dyspepsia, with general languor. Through the winter he had experienced some difficulty in controlling his urine, and during the previous summer he had had fainting fits from time to time. A week before admission he had considerable epistaxis, and since then his nose had bled whenever he had blown it.

When admitted the splenic tumour extended to within 2½ inches of the pubis, and 2 inches to the right of the umbilicus; its edge firm and rounded. The hepatic dulness extended 1½ inch below the ribs; there was no ascites, and no œdema of the legs. There was a systolic bruit at the apex of the heart, regarded as anæmic, and moist sounds over the contracted lung. The urine was free from albumen.

In September some localised peritonitis over the spleen was found, but no other prominent symptoms appeared until about a

fortnight before his death. Hæmatemesis then occurred with hæmaturia at the same time, from the effects of which apparently the patient sank. The temperature, which was observed from time to time, was found to vary between 98° and 100°. The tumour was not noticed to increase in size materially after admission, but during the last week of his life it was observed to become appreciably diminished in size and softer (probably from a diminished fulness of its vessels). Examination of the blood indicated an increase in the relative proportion of the colourless to the coloured corpuscles.

Autopsy.—The body was much emaciated. The spleen weighed 6 lbs. ½ oz.; its edge was thick and rounded; its substance compact and fleshy looking, not discoloured by iodine; there were some grey masses in it, apparently due to blocks in branches of the splenic artery, but no nodules like lymphadenoma or lardaceous material. There was some lymph on the surface of the organ. The liver and kidneys were much larger than normal. In the liver the lobular structure was abnormally distinct. The kidneys appeared simply anæmic. The left lung was shrunk up and firmly adherent to the wall of the chest; its substance was red, very tough, non-crepitant, seemingly fibroid.

Microscopical sections were obtained from the spleen, liver, kidney, and lung. In the spleen the appearances seen were the same as in the last case. Adenoid growth, with distinct reticulum, was seen in the sections both from the liver and kidney. In both organs, as also in sections of the contracted lung, the vessels were seen mapped out by leucocytes; as in other cases, it was difficult to determine whether these leucocytes were within the vessels or along side of them in some parts. In the sections from the lung no distinct lymphoid growth could be made out.

The nosological distinctions which may be drawn between cases presenting anatomical and clinical features similar to the above are, (1) the separation of cases in which the condition of leukæmia is present from cases in which there is no leukæmia; (2) the division of these into the two forms, hard and soft malignant lymphoma, according to the condition of the glandular and visceral enlargements; (3) the subdivision of each of these hard and soft forms again into the lymphatic, splenic, and mixed or lienal-lymphatic forms of disease.

As regards the first point (leukæmia), in only one of our cases was

there a condition found at all approaching that to which it is considered that the term leucocythæmia should be properly restricted, though in others a marked degree of leucocytosis was observed.

As regards the second point, the distinction between the hard and soft forms of the disease, our facts go to show that this difference is one depending upon the rapidity of progress and recent development of the morbid changes, rather than upon the nature of the growth itself. For in two of our cases it is especially noted that while some of the enlarged glands were much congested, ecchymosed, soft, pulpy, and yielding a milky or creamy juice when scraped; others in the same subject were found firm, tough, and indurated (see Cases 1 and 2).

As regards the third point above mentioned, the distinction between the lymphatic and splenic forms of disease, our facts and observations go to show that there are in both forms, however much differing in their clinical features, distinct invasion of the kidney, liver, and other viscera by lymphadenoid growth, in a manner which appears to be characteristic and specific, and this general characteristic invasion seems to indicate a very close connection between both these forms of disease.

In five out of the nine cases here collected the autopsy showed gross lymphadenomatous changes in one or more of the organs, either in the form of nodular masses of growth, or as the characteristic condition of the kidney resulting from extensive invasion. But microscopic examination revealed more wide-spread lymphadenomatous changes of an equally characteristic nature in many organs which seemed to the naked eye unaffected, or simply enlarged, and it was found that in every one of the five cases thus examined, such changes in the viscera were present to a greater or less extent. There are, in fact, only two of our cases (both included in the first and larger group) in which no evidence of invasion of kidney, liver, or other parts was revealed by the autopsy, and in these no opportunity for microscopical examination of the organs was afforded.

The facts recorded in the accounts of the cases given above which bear upon this point may be thus arranged:

1. Of the seven cases included in the first group (glandular form) evidence of this invasion of the viscera was afforded, (α) in one case (Case 1) by enlargement of the kidneys only, as shown in one of the drawings exhibited (β) in two cases by the presence of nodular growth more or less widely disseminated; (Cases 4 and 6) (γ) in

two cases (Cases 5 and 7) by the microscopical examination of several organs. In both these cases the liver and kidneys were found affected (in Case 7 there was great enlargement of the kidneys, with the characteristic appearance, and there were some ill-defined nodules in the liver: in Case 5 these organs presented a normal appearance. In the lungs the alveolar septa were thickened by infiltration by leucocytes, but no distinct reticular structure could be distinguished and in sections from the brain also no such structure could be distinctly made out.

2. In Case 8 sections obtained from the enlarged kidney and the intestine both showed extensive invasion by adenoid growth; similar growth was seen in less degree in the liver, kidney, and lung in Case 9. In the brain of Case 8 no adenoid structure could be distinguished. No portion of the liver in this case was preserved, and its condition therefore is not known.

[As regards the distinctive characters of the adenoid growth found invading the liver and kidneys and other organs in these cases, although it might be admitted that there is nothing distinctive in its histological elements, similar reticulated growth being found at the seat of inflammatory processes of an indefinite character, yet it would appear to be characteristic and highly distinctive, when regarded in connection with the locality in which it occurs in this class of case. In no other condition, as far as our observations go, is such microscopic growth met with either in liver or kidneys. The lymphadenoid growth seen in these organs bears little or no resemblance either to tubercular or to intertubular inflammatory growth affecting them, being distinguished by its orderly arrangement, and by the freedom of the glandular tissue from disorder. From these it is moreover separated on the one hand by the absence of caseous metamorphosis, even in the most extensive masses of the growth, and on the other by the wide distribution and broad anatomical features of the disease.

Another noticeable feature, very conspicuous in many of the sections of organs from our cases, is the remarkable condition of the vessels, numbers of which are seen mapped out, and many tightly packed with masses of colourless corpuscles. In only one of the cases examined was this condition absent; in all the other cases it is more or less conspicuous in all the organs examined. This condition of the vessels is seen in an extreme degree in sections from the brain of Case 8. Although some such appearance is found

under other conditions, we have not in any other instance seen a condition at all comparable in degree with that presented in these cases. The only case in which the plugging of the vessels with leucocytes was not observed is Case 6. In this case alone also the kidney was found free from invasion by the adenoid growth, which seemed to be restricted to the nodules visible at the autopsy, and the growth as compared with that seen in the other cases was remarkably fibrous in its nature.]

In none of the above cases were there prominent enlargements of the glands and a large splenic tumour concurrently present, although in every one of the glandular cases some splenic enlargement was observed, and in only one of the splenic cases was no glandular enlargement noticed. Case 7 might be regarded as an example of the mixed form of the disease of an acute kind, the glandular and splenic enlargements being there concurrently developed and appearing equally prominent.

As a well-marked instance of this mixed form of the disease the case of a boy aged 12, under Dr. Frederick Taylor in Guy's Hospital, in June, 1873, may be referred to in connection with the above. In this case, which is recorded by Dr. Taylor in vol. xxv of the 'Transactions,' there was an immense splenic tumour, the organ weighing 51 oz., with great and general glandular swellings. Sections made from various organs by Dr. Taylor showed infiltration of them all by adenoid structure. In this case also there was a degree of leucocotosis deserving the name of leucocythæmia, the proportion of colour less and coloured corpuscles being found to be as high as 1 to 10.

The occurrence of such combined "lienal-lymphatic" form of the disease, similarly attended with invasion of various organs by lymphatic growth, afford still further evidence of the very close connection between the two groups of cases; and seeing, moreover, that in these instances such varying degrees of leucocytosis were met with, from an apparently normal condition of the blood to one of true leucocythæmia, it may be questioned whether the presence of this condition in the last-mentioned case can be properly held to outweigh what appears to be so well defined and intimate an anatomical connection; at least until its primary importance amongst the morbid phenomena with which it is found associated has been determined.

The observations by Dr. Goodhart of the gradual development of a condition of leukæmia in certain cases of splenic enlargement in

children seem to indicate that this may be a phenomenon of secondary importance in some cases; and the fact that a more or less marked degree of leucocytosis is found to occur under many different conditions, suggests the possibility that the rare appearance of leukæmia may be merely the result of the concurrence of several such conditions tending to produce an increase in the number of colourless corpuscles in the blood.

To sum up the experience of the preceding cases, they show that the condition leukæmia is not the rule in lymphadenoma; and in its extreme form, even where the spleen is very much affected, it may be absent; and however convenient it may be to divide the cases into hard and soft forms, according to the consistence of the morbid material, or according to the organs affected, whether spleen or glands, or according as both glands and spleen are affected in the mixed form of disease (lienal-lymphatic), yet there are in every one of these forms similar histological changes in the liver, kidneys, or other organs, linking the cases together as varieties of a morbid state. The kidney changes are noteworthy as differing most strikingly from any other form of kidney disease.

April 16th, 1878.

---

8. *Case of rapidly fatal lymphadenoma.*

By George Garlick, M.D.

Joseph H—, æt. 7 years, admitted January 5th, 1878, into the Hospital for Children, Great Ormond Street, under Mr. Smith.

There is a history of phthisis on the father's side, and two of the children died of strumous affections. The child was never considered strong; was operated on a year previously for talipes, when no enlargement of the glands was observed. For the last two months a swelling has been forming on the left side of the neck and gradually enlarging, the child falling away in health and strength, often keeping his bed for two or three days together, sweating at night profusely. There is no history of bleeding. The bowels are natural. On admission the child is wasted and anæmic, so weak he can barely sit up in bed. His temperature varies from 101° to 103·5°. On the left side of the neck, and projecting to about the level of

the ear, is a large mass of lymphatic glands, filling up both triangles on this side, dipping below to the supra-sternal notch and clavicle; the trachea and larynx are pushed considerably to the right, the former entering the chest behind the right sterno-clavicular articulation.

The mass described is of an elastic, firmish feel, and is largely lobulated. The skin is not adherent; the external jugular vein is enlarged. Other external lymphatic glands are not enlarged. The spleen is, however, below the margin of the ribs. The blood looks pale; in a full field of red there are about fifteen leucocytes, that is, no marked excess. After admission the symptoms were rapidly increasing asthenia, with dysphagia and occasional attacks of dyspnœa. Continuous high fever, the temperature ranging between 102° and 104°; it being slightly higher in the morning. Diarrhœa, the motions being brown. The blood, examined ten days after admission—that is, on the day preceding death—showed a marked diminution in number of both the white and red cells. The child sank on the morning of the 16th of asthenia.

On examining the body *post-mortem* there are found on the left side of the neck about twenty-five enlarged lymphatic glands, from the size of a hazel to a Brazil nut, and extending deeply beneath the clavicle and behind the supra-sternal notch. The glands on section are vascular, especially peripherally, and present a very few caseous points. Weight of the mass 7 oz.

Tracheal and bronchial glands much enlarged, some the size of a walnut; that seated in the bifurcation of the trachea is extensively caseous, but there are a few points of this change in most. A small patch of consolidation is seated in the right lung, about the size of a pea; this is pale grey, and looks like a catarrhal pneumonic mass. The liver contains many lymphoid growths, the largest being the size of a hemp seed, starting at small points at the periphery of the lobules, and especially at their angles.

Spleen measures from above down 5½ inches, and 3½ inches across; weighs 11 oz.

The lymphoid patches in it are numerous, from the size of a pin's head to that of a hemp seed, the larger being branched and whiter. There is also pale mottling of the splenic tissue. Seated in the hilus of the kidney is a large vascular lymphatic gland, of the same character as those in the neck. There is no other lymphatic growth. The different organs were examined microscopically by Dr. Barlow,

who found the following changes:—In the spleen considerable enlargement of the Malpighian bodies from new cell growth in the sheaths of the vessels. In some of the arteries hyaline swelling of the intima. The middle portion of the Malpighian bodies are granular and degenerated, whilst the central and peripheral parts are still in active growth. The enormous swelling of the blood channels has destroyed a great portion of the splenic pulp.

The masses seated in the liver present enormous development of the reticulum, with many giant cells; the adjacent liver cells are in a state of fatty degeneration.

The lymphatic glands differed from the normal structure in the coarseness of the reticulum and large size of the cells; many parts of the glands show extreme degeneration of the cellular elements.

The chief points of interest in the case appear to be its extremely rapid course, only two months and a half elapsing between the time the swelling was noticed and death, and the marked degenerative changes in the new growth in the glands and spleen, both to the naked eye and microscopically. *April* 16*th*, 1878.

---

9. *Lymphadenoma.*

By C. Macnamara.

This patient had been under the care of Mr. Goldie, Superintendent of the Stepney Sick Asylum, for about a year. He was a fair-haired, blue-eyed, intelligent lad, and although suffering from enlargement of the cervical glands, his general health had been good until June last, when the lymphatic glands on the right side of his neck commenced increasing in size very rapidly. His family history pointed to the fact of his having inherited a tuberculous diathesis. On his admission into the hospital, five months after the commencement of the rapid growth of the cervical glands, our patient was extremely pale; the whole of the right side of his neck was occupied by a large tumour, which felt like a firm sarcomatous growth, with here and there soft patches scattered throughout its substance. The skin covering the tumour was healthy, and freely movable over the morbid growth.

The lymphatic glands on the left side of the neck were greatly enlarged, as were the glands in the patient's axilla, as well as those in front of the elbows, the groins, and popliteal spaces. There was no enlargement of the liver or spleen, no albumen in the urine, nothing abnormal in the choroid or retina; the heart and lung sounds were natural. There was no anascarca or dropsy. The patient's blood was very carefully examined, and there was found to be no increase in the number of white corpuscles which it contained.

Soon after admission into hospital the patient was seized with pleurisy. His breathing and digestion had previously been much impeded by the pressure of the tumour on the trachea and œsophagus, and he speedily sank under the increased difficulty of respiration caused by the effusion into the pleura.

On making a *post-mortem* examination we found that not only were the glands above-mentioned greatly enlarged, but the œsophageal, bronchial, mesenteric, and in fact all the lymphatic glands in the body, were hypertrophied.

The tumour occupying the right cervical region was composed of a mass of enlarged glands; in places, however, it was soft and almost gelatinous.

The liver and spleen were of normal size and colour, with the exception of a number of yellowish-grey nodules scattered over their surface; from these nodules processes passed into the parenchymatous structure of the organs. Over the base of both lungs similar growths were observed.

The kidneys and supra-renal capsules were healthy.

I injected the vessels of this patient's right tibia through the femoral artery, and I now show you the specimens thus obtained. You observe that the vermilion injection has filled the vessels of the periosteum, the nutrient arteries, and vessels contained in the Haversian canals of the compact tissue of the bone, but it has failed to penetrate into the blood sinuses contained in the medulla of the cancellated tissue. On examining sections of the bone we find that its cancellated structure is choked by a dense fibro-cellular tissue, which is precisely similar in appearance to that seen in the gelatinous portion of the tumour in the neck. I believe it is through the pressure exercised by this cellular growth (confined by the unyielding bone) on the vascular sinuses which has prevented the injection entering these channels, and if so, it is probable the circula-

tion of blood through these sinuses must have been impeded during life, so that we have a precisely analogous morbid condition in the medulla here to that which I have described as existing in cases of tuberculous disease of the bones. With the naked eye we can see patches of this fibro-cellular formation, some of considerable size, in the medullary canal; they look very like what they have often been described as resembling in other parts of the body—small lumps of suet—being, in fact, indurated or hypertrophied portions of the normal elements contained in the cancellated tissues and medullary canal of a growing bone.

Holding as I do that the deep layers of the periosteum and the medulla of bone are derived from cells originally contained in the temporary cartilage, it is interesting to observe that in this specimen the periosteum in contact with the shaft of the bone is crowded, like the cancellated spaces, with round cells imbedded in adenoid tissue.

Although the hard portions of this tibia have not as yet suffered from the abnormal condition of the medulla which it contains, nevertheless, had the patient lived, it seems probable, in consequence of the defective supply of blood passing through the cancellated tissue, that it would ultimately have degenerated and broken down in precisely the same way as we have seen in cases of tuberculous disease of the bones. In truth it seems that the characteristic feature of lymphadenoma very much resembles those of scrofula, it may be, modified by syphilis, or some other constitutional taint; and, as I have said before, the condition of the medulla is identically the same in these affections, so far as the naked eye and the microscope enable us to observe them.

I may further remark that in leukæmia, accompanied with enlargement of the spleen, generally the effect of malaria, the patient often being anasarcous, and his blood always containing an excess of white corpuscles, that the condition of the medulla is totally different from that seen in this case of Hodgkin's disease; for in instances of advanced leukæmia from the above-mentioned cause, even in growing bones, we find the blood sinuses in the cancellated spaces crowded with rows of white corpuscles, injected, I might almost say, with them, and the round cells of the medulla are comparatively few in number, the space they occupy in healthy specimens of bones being filled with fatty matter.

April 16th, 1878.

10. *Intestines and abdominal lymphatic glands from a case of lymphadenoma.*

By SIDNEY COUPLAND, M.D.

THIS specimen—which shows well the extent to which an overgrowth of lymphatic tissue may take place in the coats of the intestines—was obtained from the body of a young married woman, 25 years of age, who was admitted into the Middlesex Hospital on April 17th, 1877, under the care of Dr. Cayley, to whom I am indebted for the privilege of exhibiting the specimen. There was no family history of lymphatic disease in her case, and she herself had enjoyed good health until three years ago, when her youngest child was born. Since then she had suffered from a constant leucorrhœal discharge. The illness for which she came into the hospital commenced eight months before with diarrhœa and frequent vomiting, so that she had lost much flesh. The diarrhœa had become very intractable, and it was the chief symptom present during her stay in the hospital. For a time it was kept in check by astringents and opiates, but it was never thoroughly controlled. Pain in the abdomen and vomiting were also frequent symptoms, whilst the leucorrhœal discharge continued almost unchecked. For a few weeks she seemed to rally, but she never gained flesh, and she died rather unexpectedly on June 3rd, being worn out by the prolonged diarrhœa. An interesting feature in the case was the pyrexia, which was especially marked towards the close, when there were marked evening exacerbations and morning remissions between 103° and 99°. Subjoined is the record—unfortunately imperfect—of the thermometric observations :—

April 17th	M. 102·8°	April 22nd	M. 98·4°
„ 18th	M. 102·2°	„ „	E. 102°
„ „	E. 103·4°	„ 23rd	M. 97°
„ 19th	M. 99°	„ „	E. 102°
„ „	E. 101·4°	„ 24th	M. 96°
„ 20th	M. 99·6°	„ 25th	M. 97°
„ „	E. 98·2°	„ 26th	M. 97·6°
„ 21st	M. 98·8°	May 9th	M. 98·6°
„ „	E. 99°	„ 10th	M. 99°

May	11th	M. 100°	May	26th	M. 102·8°
„	12th	M. 100·2°	„	„	E. 102·4°
„	19th	M. 101°	„	27th	M. 100°
„	„	E. 98·8°	„	„	E. 103°
„	20th	M. 102°	„	28th	M. 99·4°
„	21st	M. 101°	„	„	E. 103°
„	„	E. 101·4°	„	29th	M. 102·4°
„	22nd	M. 100°	„	„	E. 104°
„	„	E. 102°	„	30th	M. 100°
„	23rd	M. 103·7°	„	„	E. 103·6°
„	„	E. 103·2°	„	31st	E. 103°
„	24th	M. 99°	June	1st	M. 100·8°
„	„	E. 102·8°	„	„	E. 102°
„	25th	M. 99·5°	„	2nd	M. 102°
„	„	E. 103·6°	„	„	E. 103°

The *post-mortem* examination was made thirty-two hours after death. A few enlarged lymphatic glands were met with in the neck and in the inguinal regions.

The tonsils were natural.

The right lung was universally adherent to the chest wall; the left was free. Both organs contained much blood, and the surface of their lower lobes, particularly along the margins and posteriorly, were marked by numerous depressed areas of collapse. There was no pneumonic consolidation, nor any tubercular change, but the lungs were tough in texture and not very crepitant.

The mediastinal glands were natural.

The right cavities of the heart were full of fluid blood. The heart wall was flabby and friable, the valves being natural.

In the abdomen the coils of intestine, distended with flatus, presented vivid lines of vascularity along their points of contact. The peritoneum was natural. The mesenteric glands were all notably enlarged, and varied in size from a small pea to a walnut. They formed a curious conglomerate mass, in which each gland, distinctly encapsuled, was separated from the others. On section the glands appeared of a pure milky-white and greyish-white colour, very firm, not yielding any juice on scraping, quite free from vascularity, and equally free from any retrogressive changes in the way of caseation or softening. In many places the lacteal vessels could be distinctly seen coursing from the intestinal walls to these glands, these vessels appearing as opaque-white beaded and varicose tubes, which stood prominently above the smooth serous membrane. A row of similarly enlarged glands occurred along the lower border of

the pancreas; others were met with in front of the spine; others, again, occurred here and there in connection with the colon.

The stomach presented evidence of *post-mortem* softening at the fundus; but nearer to the pylorus the mucous membrane was thickened, opaque, and mammillated, some of the mammillations being marked by a central pit or depression. They were evidently due to enlargement and ulceration of the solitary follicles.

The duodenal mucous membrane presented a remarkable appearance. It was of a dead-white colour, and appeared to be infiltrated almost uniformly with opaque-white material, marked here and there by small erosions and superficial ulcers. This infiltration not only caused very manifest thickening of the mucous membrane, which was shown particularly in the valvulæ conniventes, and which gave a soft, cloth-like feel to the gut, but the bowel seemed to be actually enlarged in calibre by its presence. This was seen even better in the ileum, where the same "medullary infiltration" and thickening of wall, with dilatation, existed throughout its whole length. It was not uniformly and continuously affected, but was most extreme in Peyer's patches, which were unusually prominent, and here and there individual solitary follicles stood out by their greater prominence and opacity. The valvulæ conniventes were nearly all of them rounded and prominent, not lying folded over in contact with the wall of the gut. They were fully three times their normal thickness, and all presented the marked milky-white appearance. Here and there the smooth surface of the lining membrane was interrupted by a patch of ragged villous-looking ulceration; sometimes along the margin of a valvulæ conniventes, in other places in the site of a Peyer's gland.

The cœcum was in great measure free from this change, but throughout its whole extent the colon exhibited areas of this submucous infiltration, limited, however, in great part to the solitary follicles. Even in the lower part of the rectum a small opaque-white nodule was found beneath the mucous membrane. In fact, there was a more or less diffused growth of new material in the submucous tissue and mucosa, rendering these coats on section of a white medullary appearance and thickening them, so that they exceeded the rest of the coats together in diameter.

Beneath the pelvic peritoneum on the right side, opposite to the brim of the pelvis, was a white nodule the size of a haricot bean, and depending from the os uteri was a small polypoid excrescence,

smooth on the surface, white in colour, and soft in consistency; it was not larger than a pea in size. With this exception the uterus was natural. The bladder also was healthy.

The spleen and pancreas were natural.

The liver was enlarged and highly fatty.

The kidneys were granular on the surface, but not notably wasted.

Microscopical examination shows the change in the mesenteric glands to consist principally in an overgrowth of their cellular elements, numerous large nucleated cells occuring mingled with the smaller lymphoid cells. The stromal tissue is well marked, especially the main trabeculæ, whilst the capsules of the glands are much thickened. An abundant and highly vascular fibro-cellular and fatty tissue passes between the glands, binding them together, but everywhere the glands are distinct, and not confluent. Vertical sections through the coats of the intestines show everywhere an abundant growth of small celled tissue, evidently a hyperplasia of the normal submucous lymphatic tissue. By no means limited to the submucosa this new growth has extended towards the surface of the mucous membrane, passing between the Lieberkühnian glands, which are shrivelled and atrophied, and producing marked enlargement of the villi. The muscular coat is invaded by the same cellular infiltration. There is some lardaceous change both in the intestines and the mesenteric glands.

There is then here a condition of uniform hyperplasia of the submucous lymphatic tissue of the intestines, a change not limited to the solitary or agminate glands, as in some cases that are on record. One of these is to be found in 'Cruveilhier's Atlas' (Liv. 34, plates 2 and 3), in which the lymphatic glandular affection was more widespread, and where the growth in the intestines was limited to the solitary follicles, but where the gastric wall was thickened by a diffuse infiltration. It may be of interest to summarise here the chief features of this case, one of the earliest and most fully recorded of this type of abdominal lymphadenoma. The patient, a master mason, 43 years of age, who had enjoyed good health previously, dated his illness from painful swelling of the testicles, especially the right, and concomitant swelling of inguinal glands, which had commenced six months before he came into hospital. Then he was troubled by pain and distension of the abdomen and obstinate constipation, and two months later he was attacked with tonsillar angina, following which the submaxillary lymphatic glands became enlarged. Lastly, increasing

weakness, malaise, fever, and sweats, compelled him to abandon work and enter the hospital (in September, 1839) where he came under the care of M. Briquet, who records the case as one of "Chronic adenitis with special alteration of the mucous follicles of the digestive tract." Moderate wasting, coryza, injection of the buccal mucous membrane, enlargement of papillæ at base of tongue, of tonsils, of submaxillary, submental, and cervical glands were noted. There was no cough, and the thoracic organs appeared healthy. The abdomen was tense and large, not tender; and large masses could be felt in its centre. The appetite was bad and thirst excessive, and there was also occasional colic and obstinate constipation. There were enlarged glands in the axillæ, groins, and on the sides of thorax. The testicles appeared natural. He suffered from sweating, a sense of fatigue and weakness, frequent pulse, and general malaise. The patient died after two months' residence in hospital, the lymphatic glands having continued to enlarge, and diarrhœa and dropsy setting in towards the close of life. The morbid conditions found, in addition to those noticed during life, were great enlargement of the mesenteric and mesocolic glands, some of which were firm, others soft on section, and comparable to encephaloid cancer. The liver was large, the spleen voluminous and studded with lenticular granulations. The bronchial glands were enlarged. Cruveilhier figures the stomach and portion of the intestines. The gastric mucous membrane was three or four times its normal thickness, the thickening being due to an overgrowth of lymphatic tissue, precisely as in the specimen now before the Society. The mucous membrane of both small and large intestines was studded with nodules, some sessile, flat, and lenticular, others pedunculated; Peyer's patches were also swollen. Cruveilhier, in his comments on the case, differs from Briquet, who regarded it as an instance of chronic enteritis, with secondary inflammation of the mesenteric glands, and thinks that the gastro-intestinal condition was independent of the general lymphatic glandular affection which he thought partook of the characters of malignant disease.

Both these cases must, however, be considered rare, so far as the involvement of the gastro-intestinal tract goes; although there is no *à priori* reason why the lymphatic tissue in that tract should escape the general overgrowth which takes place in cases of lymphadenoma. In one of Dr. Murchison's cases ('Path. Trans.,' vol. xx, p. 143) a parallel condition, carried to an extreme degree, was met with in the duodenum.

In the case now before the Society it appears, however, that the lymphatic affection started from the intestinal tract, that, in fact, we have here an instance of what may be styled, to use Dr. Gowers' convenient term, primary "lymphadenosis" of the intestines.

April 2nd, 1878.

---

11. *Hyperplasia of axillary glands with leukæmia.*

By T. Ridge Jones, M.D.

A gentleman, æt. 50, consulted me on the 10th July, 1877, for enlarged axillary glands and extreme debility. He stated that one sister had died of consumption, after giving birth to three children; his family history was otherwise good.

He was considered delicate up to the age of five years, when he was supposed to be suffering from some abdominal disease; he, however, completely recovered, and grew up to be a strong, healthy man; he always worked hard, but lived a regular life, and enjoyed good health until the commencement of the present illness. He never suffered from syphilis. In the autumn of 1876 he noticed a lump in his right axilla, which gave him no pain or discomfort, and his health remained good. Towards the end of the year he began to ail, and in March, 1877, suffered from a severe attack of eczema, affecting the face and lower extremities, for which he consulted a physician, who prescribed a calomel and colocynth pill, to be taken twice or three times a week, and Fowler's solution, with bicarbonate of potash, three times a day. He persevered with this treatment till the first week in May. During all this time he remained at work, which was of a responsible and arduous nature. As he was not improving, he went for change of air to Leicestershire on May 12th, when he was seen by Mr. Edward Williams, of Billesdon, who found him then suffering from "severe pain over the hepatic region, extending through to the back; complete loss of appetite, with a glazed and irritable tongue; passing several highly offensive stools, the colour of dirty gruel; great prostration of strength; urine scanty and deeply coloured with bile and purpu-

rates, but without albumen or sugar; total loss of sleep; constant watery discharge from the nose. There was an enlarged gland in the right axilla; the skin over it was thick and brawny, and was of a dark plum colour. There was also a chain of enlarged glands, extending up to and above the clavicle, on the same side; the skin over the whole was so thickened that the clavicle could not be seen." While under the care of Mr. Williams he was treated with the mineral acids, nux vomica and taraxacum, podophyllin and colocynth, and afterwards hydr. c. creta and rhubarb; at the same time full doses of chloral and Battley's solution of opium were administered, which procured for him a few hours' sleep each night; and after the first two doses he completely and permanently lost the pain in the hepatic region. He, however, continued to lose strength till the beginning of June, when the secretions from the bowels and liver became healthier, and his appetite improved. He was now able to take a fair amount of nourishment, and began to gain strength and flesh, and to improve steadily. His secretions, although healthier, varied from day to day. This state of things continued till the beginning of July, when the opiates failed to procure sleep, and as he was again becoming worse, he came up to town.

I first saw him on the 10th of July, the day after his arrival in town, and found him extremely emaciated, with the appearance of one suffering from malignant disease. There was a slight eczematous eruption on the face and legs; the lips were dry and cracked. There was a swelling the size of a Seville orange in the right axilla, freely movable and firm, and without pain; the skin over it was of a dark colour and hard. There was some swelling and hardness of the tissue (as if from œdema) over the pectoral muscle of the same side, extending as far as the clavicle, but no enlarged glands could be felt in this region, and no enlarged glands could be felt in any other part of the body. His skin was dry, and the temperature was 100° Fahr. in the morning, and 102° in the evening. He complained of chilliness, scarcely amounting to a rigor. The tongue was red and glazed; almost complete anorexia; bowels generally acted twice, and sometimes three and four times, in the twenty-four hours; the motions were copious, dark, sometimes yeasty looking, and unusually offensive, but they contained no blood or mucus. The liver and spleen were not enlarged. Abdomen was flat and free from pain, and no enlarged gland could be felt in this

region. He had a sight hacking cough. Beyond a slight deficiency of breathing, with dulness over the right infra-clavicular region, which was accounted for by the swelling over the pectoral muscle, no abnormal sounds could be heard in the lungs.

Heart sounds normal. Pulse 120, weak and irritable. No hæmorrhage from the gums or other mucous surfaces. Urine loaded with lithates, free from albumen and sugar.

His only complaint was extreme prostration of strength and almost total loss of sleep.

On the 20th of July, ten days later, some blood was drawn from the finger and examined under the microscope, which presented the following appearances:—The fibrine seemed to coagulate unusually rapidly on the glass slide. *The white corpuscles, which were small and granular, were found to be greatly in excess; in one corner of the field as many as thirteen white to one red corpuscle were seen.* The axillary glands (on the right side) were smaller, and the induration and swelling over the pectoral muscle were diminished. He was, however, weaker, and the general symptoms remained the same—constant diarrhœa, and the temperature never below 100° in the mornings, nor below 102° in the evenings. He has slept more at nights after bromide of ammonium and henbane.

In the beginning of August, whilst in this almost dying state, a gland behind the *left* angle of the jaw became enlarged and tender without apparent cause, there being no sore throat. This swelling rapidly attained the size of a hen's egg, the skin over it became red, and in about a week fluctuation could be felt. The temperature now became higher, never below 101° in the morning and 103° in the evening. He died exhausted on the 25th of August, about a year from the commencement of the disease in the right axillary glands.

The treatment adopted consisted of bromide of ammonium and henbane at nights to procure sleep. Iodide of potassium, in ten-grain doses, with ammonia and gentian, afterwards with bark. Quinine to reduce the temperature, but without good effect. Mineral acids, astringent mixture, and subsequently lead and opium, to moderate the diarrhœa, but without good result.

Post-mortem examination, thirty-three hours after death, made by Dr. Whipham.

The weather was hot, and decomposition had commenced. The body was extremely emaciated.

Two swellings, each about the size of a Seville orange, were found; one below and behind the left ear, from which pus was exuding at the time of the examination; the other in the right axillary space. Both swellings were hard and unyielding to the touch, but the centre of the axillary swelling was soft, having the appearance and consistency of broken-down brain substance.

Thorax.—Lungs: old and very firm pleural adhesions existed between the two layers at the apex and base on the right side, and in the cavity of the pleura was about a pint and a half of clear serum. The left pleura was natural. The right lung was completely capped by a dense layer of thick pleura, about one eighth of an inch in thickness, and cartilage-like in consistence. In the upper lobe of the left lung were one or two old cicatrices. In other places small round masses of fibrous tissue, with black pigmented centres, were found in the lung substance (? healed vomicæ).

The lower lobe of the right lung was to a slight extent compressed by the effused fluid into the pleural cavity.

The bronchi generally were much thickened, but the glands were not enlarged.

Heart.—The pericardium was natural. The heart was slightly contracted, and on the right side were decolorized, partially decolorized, and recent coagula. The mitral valve was somewhat thickened, but not sufficiently so to impair its efficiency.

Abdomen.—There was total absence of fat in the omentum, otherwise the peritoneum was natural.

Liver.—The capsule of the liver was in places considerably thickened, otherwise the organ was apparently natural.

Spleen.—The spleen was slightly shrivelled, but in size and appearance was quite natural.

Kidneys.—The kidneys were slightly congested, but otherwise natural.

Pancreas.—The pancreas was natural.

Intestines.—The intestines were examined throughout. They contained fluid, yellow fæces, and were natural in appearance. The stomach was natural.

Microscopical examination of portions removed from the tumours above mentioned showed that the swellings were apparently due entirely to hyperplasia of the gland tissue. Thin sections under the microscope show the ordinary appearances of lymphatic gland, and scattered here and there among the lymphoid cells are seen

large, flat, irregularly-shaped cells, derived, in all probability, from proliferation of endothelial cells. These large flat cells are in many places seen in the field in considerable numbers, but they are especially abundant in the neighbourhood of the capsule of the gland.

In another section from the axillary glands, showing proliferation of the epithelial cells, the fibrous tissue is in excess. (See Pl. XIX A, fig. 1.)

It seems that lymphatic leukæmia is so rare a disease that even its existence is doubted by many good authorities. I have certainly failed to find a case recorded in the Society's 'Transactions' in which the disease was so entirely confined to the lymphatic glands. The liver and the spleen were not examined microscopically, but they presented no naked-eye evidence whatever of any patches, or even infiltration of adenoid growths.

Clinically, the case was different from Hodgkin's disease, with extensive growths in the lymphatic glands, liver, spleen, and other organs. Here the patient died rapidly of apparently malignant disease, and the only lesion that could be found was the comparatively slight enlargement of a few glands. It would have been difficult to explain the cause of death in this case if the blood had not been examined and found to be leukæmic, as the disease in the glands was so very limited. For it is now well known that growths of the same nature exist in lymphadenoma, affecting, not only the lymphatic glands, but also invading, to an enormous extent, important organs, and the patient surviving many years. In this case, however, as in lymphadenoma, during the active growth of the glands the most marked and persistent symptoms were the high temperature and the diarrhœa. The fact that the glandular growths were so very limited in this case tends to support the view that leukæmia is not so much due to these growths as to some want of power in the lymph and white corpuscles to form red corpuscles. Or it might be that, from some disease of the whole mass of blood, the white corpuscles might acquire some power of multiplying themselves in it.

In future, it would be important to examine, not only the corpuscles, but the other constituents of the blood, as the fibrine in this case appeared to coagulate with unusual rapidity.

April 2nd, 1878.

12. *Two cases in which tubercle was associated with, or simulative of, lymphadenoma.*

By W. Howship Dickinson, M.D.

The following cases may take their place in the chapter of pathology which now engages the attention of the Society, possibly as connecting links between lymphadenoma and tuberculosis, or possibly as indications that scrofulous swelling may have such close relations to lymphadenoma that, neither during life nor after death, is it possible to draw an absolute line of demarcation between them.

Case 1.—Henry S—, aged 18, an organ builder, came under my care in St. George's Hospital on the 21st of November, 1877. He had lost one sister from consumption; another was at the time of his admission supposed to be suffering from the same disease. At the age of nine he had suffered from "weak eyes," and from setons and blisters which were therefore applied. He was left with granular lids and a cicatrised cornea.

Seven months before his admission the glands in the neck, axillæ, and groins, began to swell; four months ago one under the chin began to discharge. For the last month he has had a cough, with pain in the left side of the chest; a week after its commencement he spat up half a teacupful of frothy blood.

There were large glandular swellings on both sides of the neck, such as to entirely alter the contour of the neck and face by the disproportionate breadth they gave to the lower maxillary level; the outline corresponded almost exactly with that taken from the patient M—, whose case is also related. The lobulated glandular masses were the more prominent on the left side. Under the chin was the mark of a recently discharging abscess. Smaller glandular swellings occupied both axillæ and both inguinal regions. Over both lungs, before and behind, were heard sibilant bronchitic sounds, together with crepitations sharp in tone, suggestive of tubercle. He was very prostrate and generally ill, with a temperature high at night and low in the morning, ranging, as the extremes of variation, from 98° to 102°. He had no difficulty of breathing. The prostration became extreme, so that the evacuations were passed uncon-

sciously, and on the last day of life he had several fits of an epileptic character.

On *post-mortem* examination, leaving out of view for the present the external glandular swellings which will be described subsequently, the brain showed the recent results of tubercular meningitis, which, however, in the shape of recent lymph and tubercles, were nearly confined to the left Sylvian fissure. The ventricles were normal, and the brain substance not noticeably congested.

Both lungs were uniformly pervaded with hard, grey, miliary tubercles, isolated or in small aggregations. These were typical grey tubercles. At the apex of the right lung was a small caseous nodule with a cicatrix. The right lung was universally adherent.

The heart was perfectly normal, the pericardium so also, but for a slight excess of fluid within it.

The liver was attached to the front abdominal wall by a small recent adhesion; its tissue was firm, as if from some degree of fibroid overgrowth, but no tubercular or lymphoid deposits were seen in it. In the thickness of the wall of the gall-bladder was a hard isolated growth, rather larger than a cherry-stone, which was regarded as of the nature of lymphadenoma.

Over the surface and in the cortical substance of both kidneys were scattered small white nodules, which to the naked eye resembled the usual renal tubercles, though some of the nodules were thought to be more prominent than tubercles commonly are.

The spleen, which was accurately represented to the Society by a drawing made by Dr. Westmacott, was not of unusual size; it weighed 8 ounces. Its surface was adherent, but not inseparably, to the neighbouring structures. It was largely nodulated, the cream-coloured nodules showing through the translucent capsule. On section these were seen as large, nearly circular masses, of a faint yellow or yellowish-white colour, which contrasted remarkably with the deep red of the splenic parenchyma. The average diameter of these masses was about a third of an inch; the largest were of about twice that diameter. These were close in texture, much more so than tubercles usually are, though in the centre of some was incipient softening. To the naked eye these masses were typical of what is now usually described as lymphadenoma.

The cervical and submaxillary swelling was found to depend upon a chain of greatly swollen absorbent glands, which passed

DESCRIPTION OF PLATE XIXB.

The figures in this Plate illustrate Dr. Dickinson's Observations on Cases of Lymphadenoma with Tubercle. (Page 373.) From drawings by Mr. G. H. Cowburn.

FIG. 1. Section of lymphatic gland, shewing excessive nuclear growth, the nuclei being collected into masses surrounding the blood-vessels; these masses having the vessels as a centre, become more and more scattered towards the circumference. (× 150.)

FIG. 2. Section of lymphatic gland, shewing proliferation of endothelium of blood-vessels, the vessels themselves being situated in a dense fibrous growth in which are also a few scattered nuclei. (× 300.)

FIG. 3. Section of kidney, shewing increased nuclear growth around position of Malpighian body, the tuft having fallen out in the preparation of the specimen. The number of nuclei is considerably increased throughout the section. In other sections were small caseous masses which had apparently commenced in the same nuclear growth. (× 400.)

FIG. 4. Section of spleen, shewing nuclear increase, caseating masses, and giant cells. (× 125.

Fig. 1

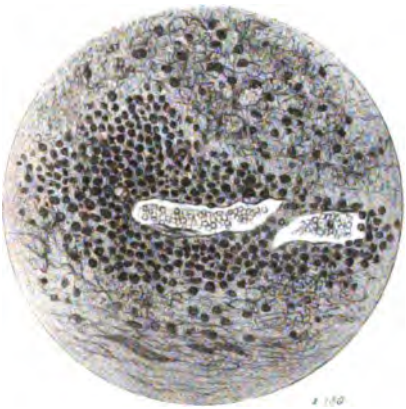

Fig 3.

Fig 2

Fig 4.

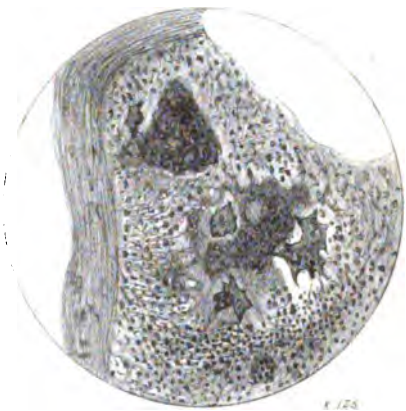

under the chin from ear to ear. One of those immediately under the chin was beginning to suppurate, and communicated with a sinus opening externally. The thyroid gland was not enlarged, but the cricoid cartilage was considerably thickened. The glands in both axillary and in both inguinal regions were evident superficially as amygdaloid swellings, but were much less enlarged than those about the neck. In the progress of the examination, other glandular enlargements were found, which may be mentioned together. The bronchial glands were enlarged, the mesenteric greatly so. A large mass of swollen glands occupied the cavity of the lesser omentum, and pressed upon the head of the pancreas. From this mass, which was equal in size to a small man's fist, a chain of swollen glands extended as far as the portal vein; another reached, in decreasing proportions, as far as the hilum of the spleen.

Proceeding to the microscopic examination of the organ I have been enabled to refer to an excellent series of sections prepared by Mr. Cowburn, to whom also I am indebted for the drawings from which the accompanying figures (see Pl. XIX B) were made. The results may be briefly stated. The miliary deposits in the lungs and in the kidneys each consisted of a central, nearly structureless core, which was surrounded by a rather extensive zone of a nuclear growth, consisting of small corpuscles, more or less round but not always accurately so, which were closely packed in a reticulum or matrix. The corpuscular growth in the kidney was sometimes collected around the Malpighian body (see fig. 3), as occurs with lymphadenoma, but there were numerous spots, comprising indeed the greater part of the morbid formation in both kidney and lung, where the growth, with its caseating centre, was precisely that of ordinary tubercle. The swollen glands, whether cervical or inguinal, displayed large tracts of a similar nuclear growth, often placed around blood-vessels (see fig. 1), which might be regarded as lymphadenomatous, but that, as in the lung and kidney, there were signs of caseation, such as might be looked upon as tubercular. The spleen presented growths which, in their large characters, were typical of lymphadenoma, but here also the minute structure was, to say the least, equivocal. The nuclear growth surrounded caseating or structureless centres, within which the outlines of giant cells were discernible in some of Mr. Cowburn's preparations (see fig. 4). The caseous centres were here extensive and the nuclear circumference comparatively narrow.

It is to be noted in the first place that the subject of this case

belonged to a highly tuberculous family. He himself had, in his childhood, suffered from ulceration of the cornea, such as occurs with scrofulous children, and later he had had an abscess in the neck connected with enlarged glands, and not differing in any ascertainable respect from the ordinary abscess of scrofula. The next step is the enlargement of the absorbent glands first and most with the cervical, but widely throughout the body externally and internally. The size and wide distribution of these swellings were such as connect the case with those to which the term lymphadenoma has been given, while, on the other hand, the suppuration in the neck marked a difference with such, and a resemblance to scrofulous or tubercular disease. In the last phase of the illness tuberculosis in its ordinary form became paramount in the miliary tuberculosis of the lung and the tubercular meningitis, which was the cause of death. The patient, in short, died of acute tuberculosis, which term was justified, not only by rough examination, but by the minute structure of the disseminated growths as displayed by the microscope. The smaller growths were such that I suppose there could be no hesitation in calling them tubercles, though perhaps the nuclear growth was more luxuriant and the caseating centre in smaller proportion than is usually the case. The larger growths were not different in kind but only in extent. It was easy to find in many organs spots and zones of nuclear growth which, taken alone, would commonly be called lymphadenoma, while in connection with them were caseous centres, which were not only indistinguishable from but were even characteristic of tubercle. It was indeed as impossible to separate after death the products of lymphadenoma from those of tubercle as it was during life to decide where the symptoms of the one condition ended and those of the other began.

Case 2.—Edwin M—, aged 8, came under my care in the Hospital for Sick Children, on December 20th, 1871. Eighteen months previously he had a swelling behind the left ear, which soon afterwards broke and began to discharge. A similar swelling then appeared under the right ear, and in time the two swellings became continuous under the chin. Two months before admission a swelling appeared under the left arm, and then another under the right. For the last three months he had had cough.

On admission he presented a striking appearance. On either side and below the lower jaw were large nodular, evidently glandular, swell-

ings, which were hard and not particularly tender. On the left side were the openings of several still discharging sinuses. Over both the superficial veins were full, and the skin injected in places to a slight blush. When the boy was undressed other swellings were seen of the same character, except that nowhere else was there evidence of suppuration. The glands were thus enlarged over each clavicle, in each axilla (most so in the left), and in each inguinal region. There was a troublesome cough, and a few dry râles were heard, generally over the chest. The liver projected slightly below the ribs. The spleen was not to be felt.

The next clinical point in the case was the occurrence of epistaxis, of which he had attacks for four consecutive days, leaving him much depressed, though the loss had not been large. His cough was now (November 20th) much worse, he was more pallid, the swellings were larger, the chest was generally œdematous, and a trace of albumen was found in the water. He continued to decline, but without any fresh symptom, until the 19th of December, when he suddenly became convulsed, and lapsed into a state of unconsciousness. On the following day he died.

During the course of the disease, the temperature had shown great fluctuations, ranging from 97° to 103°. There was generally a nocturnal rise, but not with any regularity.

On *post-mortem* examination it was found that the glands in the neck, axillæ, anterior and posterior mediastina, and some near the spine, close to the pancreas, were enormously enlarged, massed together, and of a pale yellow colour, different from that of healthy gland tissue. The lumbar, mesenteric, and inguinal glands, were but little enlarged, and not thus changed in colour.

The enlarged glands generally presented to the naked eye a close homogeneous texture; some about the bifurcation of the trachea were much pigmented, and one or two in the same situation were softened in their centres, so that a creamy fluid could be squeezed from them. Some of the glands underneath the ulcers in the neck were closely examined, but they were not different from the unsoftened glands elsewhere; the suppuration appeared to be mainly external to them.

Mr. Butlin, then Registrar to the Hospital for Sick Children, whose notes I have followed in the preceding report, examined some of the glands with the microscope, and thus reports on the appearances presented on section:

"Division into cortical and medullary portions was distinct. Cortical portion generally traversed by bands of coarse fibres running parallel to the surface of the gland, but opening out and leaving spaces or loculi between them. The medullary portion was in undue proportion to the cortex, and consisted of a meshwork enclosing large numbers of cells. Also, sometimes irregularly scattered throughout, sometimes collected into groups, were round lighter spots, apparently fat globules, and often were met with what appeared to be shrivelled vessels, of a very dark colour, and branching in various directions."

The glandular condition could, in short, be described as one of irregular hypertrophy, together with some products of degeneration.

The other organs may be more briefly dismissed. The lungs were sprinkled throughout, but more especially in their lower lobes, with miliary tubercles. At the base of the right was an old cicatrix, beneath which was a calcareous mass of the size of a nut.

The liver was of large size, as had been observed during life, reaching half way to the umbilicus. The acini were more than normally separate, and the substance generally pale and tough, but there was no isolated or distinct morbid deposit in it. The spleen was natural; it weighed 3 ounces. The kidneys were increased in size, weighing 4 ounces each; their cortical portions were swollen relatively to the cones, but no abnormality of texture or surface was detected. Some of the solitary glands near the ileo-cæcal valve were conspicuous, but the intestines were otherwise natural, as also were the organs which have not been especially mentioned.

The brain was not examined.

In this case, as in the other, the condition of the glands was that which is implied in the term lymphadenoma, while in the lungs tubercle, in its characteristic form, was as distinctly declared. The mode of death in this case suggests that there was also tubercle in the brain; but the *post-mortem* examination was incomplete in this respect. It is to be observed that in this case, as in the first, the affected glands became the seat of suppuration.

In former days the cases related would have passed as scrofulous enlargement of the glands, and the term would have been accurately descriptive of them. But the degree and distribution of the glandular hypertrophy were such as, according to modern usage, to call for the word lymphadenoma; and indeed when the coloured life-size draw-

ing of the spleen from Case 1 was shown to the Society, the President was fain to allow that it was characteristic of the disease so named. But if the growths within it had been regarded only with the microscope there might have been as little hesitation in calling them tubercular. And deposits elsewhere were tubercular in every sense. Thus, as regards both cases, we must either describe the whole series of lesions as tubercular—a stretch of language which would apply the term in a new sense to glandular hypertrophy, apart from, or altogether out of proportion to, caseation or isolated deposit —and allow that tubercular enlargement may so simulate that from lymphadenoma as to be indistinguishable from it, or else we must consider that lymphadenoma and tubercle may be associated as but two results of the same morbid bias, or even, if looked at in the light of minute structure and organic relation, as the same result modified by seat and circumstance. Both morbid formations may be described as hypertrophy of lymphoid tissue; leading in one case to caseation and decay, in the other to increasing enlargement. The extremes of each kind are sufficiently remote, but that no essential separation exists is shown by such cases as those related.

April 16*th*, 1878.

---

13. *Idiopathic anæmia.*

By W. Howship Dickinson, M.D.

The following case came under notice in circumstances which drew more than ordinary attention to it. The subject was a person whose social position made his ailment the topic of much inquiry and many conjectures, while he was enabled to obtain the services of as many eminent physicians as the variously placed confidence of his friends suggested.

Many opinions had accordingly been expressed as to the nature of his disease. It had been thought by some, as I was told, to be tubercular, by others to be cancerous, and the liver to be the seat of the growth; but my own knowledge of the case had reference only to its *post-mortem* period. I was asked by Sir William Gull to make an examination of the body, with an expression of his belief that the disease would prove to be of the sort which has been

described as "idiopathic anæmia," or, as he preferred to term it, simply "*bloodlessness*," and that we should find no organic disease except, possibly, some change in the supra-renal capsules.

To place the circumstances in order, I will here introduce a brief history of the illness of the patient, for which I am indebted to Sir William Gull, under whose superintendence he had chiefly been.

Charles Henry F—, was a tall, well-made, and strong man. Born September 28th, 1804; married, first, at the age of twenty-two; became a widower at the age of fifty-six, having no children. He married a second time at the age of fifty-eight, and had five children. He continued to be in good health until the beginning of 1872, the early part of his sixty-eighth year. He then began to get weak and bloodless (anæmic), and complained of feeble digestion and of languor. The anæmia and weakness gradually increased in intensity until his death, July 16th, 1872. The case was under rather close observation for many months. There was no cough nor dyspnœa. The heart's action was normal, but weak, the pulse varying from 75 to 80. The abdomen was soft, the liver not enlarged, though, during the illness, one physician who saw the case thought he could discover enlargement of the right lobe. The intestinal evacuations were normal and of normal colour, but rather infrequent. This fact, considering the feebleness of the patient, and his want of appetite, was often remarked upon. The urine was normal in colour and weight, and without urates. The temperature was not increased. The whole clinical history throughout was negative, the patient being very bloodless and strengthless, but without much emaciation. The patient gradually became less equal to muscular exertion, was first obliged to discontinue his drives and keep to the house, then to his room, and then to his bed, and died faint, with symptoms of cerebral oppression. Every change of food, and every form of so-called tonic was had recourse to, but without avail.

Post-mortem examination, made July 17th, 1872.—External appearance and general state of body.—There were no marked signs of putrefaction. The body was of remarkable pallor, as after death by hæmorrhage. There was a trace of œdema about the ankles. There was no emaciation. It was presently found that the fat in the abdominal wall was at least an inch thick, beside which there was a thick layer in the omentum, much in the mesentery, and a great mass embedding each kidney.

Thorax.—The lungs were slightly emphysematous; their lower

lobes were somewhat congested, and in the lowest lobe of one was a lump of cretaceous matter as large as a pea.

The heart was flabby; it had some fat upon its surface, and the muscular tissue was very soft, breaking before the finger with great readiness. Both ventricles were uncontracted. There was a little fibroid thickening upon all the valves except the pulmonary, but not such as to do them any obvious injury. The thickening was like that of old endocarditis. On the aortic valves it left the thin edge free, being accumulated along the junction of the thinner with the thicker part of the valve. The muscular fibres were generally dotted with oil, but not to obliteration of the striæ. A line of considerable oil spots often passed along the centre of the fibre, leaving its greater part unaffected.

Abdomen.—There was much fat, as already stated, about the abdominal wall, omentum, mesentery, and kidneys.

The liver was not enlarged nor generally unnatural; it contained a globular cyst about an inch in diameter, which lay near the front of the left lobe. The cavity contained a thin aqueous-looking fluid (it was not examined chemically), and was lined by a thin translucent membrane. The gall bladder contained four gall-stones, which ranged in size from a large pea to a small marble. The stomach and intestines were natural. The kidneys were somewhat roughened superficially, and contained one or two minute cysts, but they were of fair size and texture, and were probably effective organs.

The spleen was rather large; there were no means of weighing it, but its weight was probably not far removed from 10 ounces. It was extremely diffluent—looking like half-melted raspberry ice; it was more fitted for the use of a spoon than a knife. The results of a microscopic examination of the spleen pulp are shown in Woodcut 13.

The supra-renal bodies were of large size, but apparently natural in structure. The left weighed three drachms and measured three and a quarter inches in length, while its other dimensions were increased in normal proportions. The right weighed one drachm. Both presented on section the characteristic aspect of health.

Absorbent glands everywhere quite small and normal in appearance.

Blood.—The cavities of the heart contained a few very small and soft fibrinous coagula, not decolorized, and of the ordinary *post-mortem* type. These were mere shreds clinging to the valves, and might have been overlooked. But for them the heart appeared

empty, owing to the fluidity of the blood. The cavities of the heart were not, however, blood-stained, nor was there any such staining

WOODCUT 13.

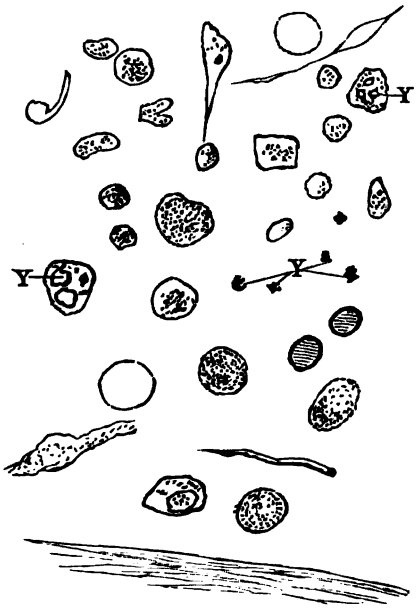

The above woodcut represents the spleen pulp containing very few red corpuscles (fully represented by the two dark outlined and transversely shaded cells). A number of large granular, faintly granular and hyaline cells are seen, some of which, Y Y, contain irregular masses of an intense yellow colour like hæmatine. (× 670 examined in water.)

of the vessels as generally accompanies fluidity of the blood. Some blood from one of the coronary veins was examined microscopically with results which are shown in Woodcut 14.

Observations by Sir William Gull.—This case was under continuous clinical observation for many months. The whole history was negative. The patient did not greatly emaciate, though there was loss of weight. The urinary and intestinal evacuations were normal, and it was often a matter of remark that the fæces were well coloured with bile. I know of no facts which would warrant the use of the designation "*pernicious*" to such a case if it be meant that this adjective implies anything special or any positive state. In cases like this I have examined the blood microscopically.

The only noticeable changes I observed were of as negative a

WOODCUT 14.

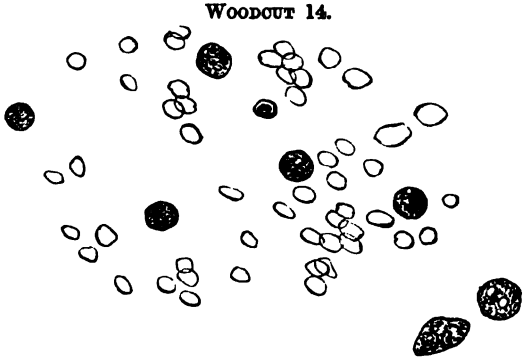

Woodcut 14 represents a drop of blood from the coronary vein of the heart, largely mixed with water, showing excess of white corpuscles, which are large, granular, and conspicuous. The red corpuscles are faint, and often elongated. (? action of water in which heart had been placed.) × 670.

character as were the bloodless face and hands of the patient. The red corpuscles were few; many were small and irregular in shape, and those of normal size crenated more or less regularly. The white corpuscles were not increased in proportion even to the diminished number of the red ones. One of the best bedside tests of these cases is to puncture the finger of the patient and receive the blood on to a piece of white linen or a lawn handkerchief, and put by the side of it a similar stain of blood from a healthy subject. The full colour of the latter contrasts strikingly with the stain of the former, which is hardly of a blood colour and translucent. In puncturing the finger there is with the bloodlessness of the patient a marked want of sensibility, corresponding to the lessened blood stimulus. I have not been able to see in this case, nor in those identical with it more than is noticeable in the anæmia of girls at an earlier age. The line of morbid action seems to be through the nervous system, interfering with the functions of digestion or more generally speaking of hæmapoiesis. Why the cases of anæmia at an earlier age are not fatal, and those of later age are so, may be due to age only. In all these remarks I speak only of the cases of simple anæmia, and I say this because I have noticed that many cases of pallor in the adult, associated with various forms of visceral disease, have been classed by some writers under idiopathic anæmia, to which, I believe, they have no relation. *April 2nd*, 1878.

14. *Cancer in its relations to the lymphatic system.*

By George Hoggan, M.B.

I feel considerable diffidence in bringing before the Society during the present discussion the results I have obtained relating to the effect of cancer on the lymphatic system, seeing that these results form only a small part of the general life history of cancer, and that to understand that part well a knowledge of the whole is almost a necessity. As that life history would, however, be foreign to the present discussion, I shall endeavour to keep clear of it, and if, in doing so, my data appear incomplete, I can only ask for the kind forbearance of the Society in the meantime, until another opportunity is afforded me of bringing my investigations before it.

The affections of the lymphatics I am about to describe occurred in the course of a cancer of the skin of a most malignant type, started originally by the ligature of a small mole about five inches below the left nipple, in June last, and ending in death, after great suffering, at the expiration of eight months. I use the word cancer in its general sense; histologically it presented the medullary type where the tumours grew in the sweat glands, becoming, by subsequent infiltration and alteration of the gelatinous tissue of the corium, a perfect type of scirrhous cancer, while those cells which developed immediately under the epidermis (in the pigment-forming zone of the skin, so to speak) were typically those of melanoid cancer. I dread, however, giving a more specific name than cancer to it, seeing that in the three last volumes of the 'Transactions' half a dozen different names have been given to what appears to me to be the same affection. To avoid being discursive I shall ask your permission to read the conclusions at which I have arrived after careful study of above a thousand preparations made from every possible point of view, the more typical of which have already been submitted to the Society as evidence in support of my conclusions.

Conclusions.

1. As soon as the lymphatic glands become affected, all the lymphatic vessels between them and the morbid part become filled with a plug formed of cancer cells. When, therefore, surgeons com-

pletely extirpate the tumour and all affected lymphatic glands, but leave the cancer-stuffed vessels between them behind, there is every pathological reason why, to use Sir James Paget's figures, 499 cases should recur out of 500 operations; and until this element of error is eliminated, we can form no correct estimate of the spontaneous recurrence of cancer after operations.

2. Contrary to expectation, the lymphatic vessels on the distal side of the tumours become also for a certain distance filled up with a plug of cancer cells. This is due apparently to the impaction and accumulation of lymph or wandering cells coming down with the lymph stream against the distal ends of the cancerous plugs in the already occluded lymphatics, and there they themselves become cancer cells by contiguous infection. The naked-eye appearances are fully confirmatory of the microscopical evidence of the first two conclusions.

3. Not only is there no development of special lymphatics in a cancerous tumour, as is held by Rindfleisch, Ranvier, Cornil, and other able pathologists, but, as already stated, all the existing lymphatics are plugged up with cancer cells.

4. Not only are there no lymphatics having mouths opening into cancerous tumours, as supposed by Thiersch and others, but on the contrary, the walls of the lymphatics remain intact as walls, even in the latter stages of the disease.

5. For some time after the lymphatics have been filled up with cancer cells, the endothelium forming their walls remains healthy, the cell outlines being well shown by the silver method, and the nuclei being shown by colour stainings to be quite normal.

6. I entirely fail to obtain the usual differentiation by the silver method in the case of cancerous cells, and this, too, in preparations where, as you have seen, the cells and tissues lying on the healthy side of the border of infection have been perfectly differentiated. This seems to be due to the incapacity of the substance of the cancer cell to resist the imbibition of silver solutions, and also to the absence of the ordinary cementum. At all events they behave like dead cells under the action of silver solutions.

7. By prolonged exposure to the contagion of the plug of cancer cells within the lymphatics, the endothelial cells which form their sole wall become cancerous, their nuclei begin to swell and become more pellucid, while, although the cells retain their shape and position, they seem to change their nature, becoming apparently softer,

staining more readily with coloured solutions, but refusing to differentiate under silver as already stated.

8. The one thing needful for the development of secondary cancers from the lymphatics is the presence of groups of wandering cells in close proximity to cancerous lymphatic walls. The formation of these secondary tumours only at certain points seems to be due to two circumstances. In the first place, contrary to the views expressed even in the latest text-books, there is no similarity in arrangement between the blood vessels and the lymphatics of the skin, the one system crossing or coming in contact with the other only at certain points. In the second place, while the lines of blood vessels are to be seen plentifully accompanied by branched or wandering cells, come possibly out of the vessels themselves, the lymphatic vessels, on the contrary, have none in their vicinity, except at the points where they are crossed by the blood vessels. The branched cells at these points being exposed to the influence of the cancerous walls, become themselves cancerous, and thus the nucleus of a secondary cancer tumour is formed, which increases rapidly from the accession of vast numbers of wandering cells from the vessels, attracted, no doubt, by the neighbourhood of the cancer, a reaction which probably existed at its first formation.

9. Although in such cancers all the fixed cells of the different tissues undergo the cancerous change, modified, however, as regards susceptibility, shape, and course, by far the greater number of the cancer cells are developed from wandering cells. This is wholly the case inside the lymphatics, and principally so in secondary tumours developed from them and external to them.

10. There is little probability that secondary tumours in turn affect the lymphatics, seeing that previous to the formation of the secondary tumour from the lymphatics, all the lymphatics in its immediate vicinity were already stuffed with cancer cells, and as it reached these it could only envelop them with its cells and thus include them within the tumour.

11. I can discover no evidence to support the doctrine that the lymphatics influence the *comparative* malignity of cancers. The lymphatics may give similar diffusion to all cancers, but it appears to me that it is the activity of each individual cancer cell which in the aggregate determines the comparative malignancy of different cancer tumours.

12. It is somewhat difficult to trace the changes effected by

cancer in the lymphatic glands, without a few preliminary words on the signification of their normal structure, as far as their delicate medullary stroma is concerned. That stroma was first described by Hewson, as consisting of the walls of the lymphatics cut across and still containing some of the lymph cells. This view of his was overthrown by the German histologists, who taught that the stroma was formed of delicate fibres with nuclei at the nodes or points of junction. Since then French histologists have pointed out that the fibres were covered with endothelium, thus returning towards Hewson's idea and making it perhaps permissible for me, when placing specimens under the microscope at the last meeting, to call attention to the fact that they could be seen to be really the endothelial walls of lymphatics, that Hewson's view was the correct one, and that, as in the sections both normal lymph and cancer cells easily fell out of the apparent meshes, we were thus enabled to study the changes wrought by cancer on lymphatic walls better here than in the tumours in the skin. These changes have been already partially described. The cancer cells coming down the lymph stream from the primary cancer, lodge themselves in the gland and there infect other lymph cells, in which a change into the cancerous condition can everywhere be traced; these in turn infect the endothelium of the wall, the nuclei of which gradually enlarge, become more pellucid, and finally proliferate as typical cancer-cell nuclei. As there is great irregularity, not only in the number of cells infected, but also in the period of infection and consequent expansion by growth of the lymph cells into cancer cells within the so-called meshes of the stroma of the gland, we find the size of the cancerous lymphatic cavities altering very much after infection, some of them becoming much larger, while others appear to collapse altogether. The tension thus exercised on the distended walls may possibly lead to rupture, as seen in the drawing, although it is quite as likely that these ruptures are due to the mechanical action of the cutting razor while the section is being made.

13. When a lymphatic or wandering cell becomes infected, it gradually increases in size in all its elements, and if originally irregular in form becomes egg-shaped. The cell substance proper (protoplasm?) becomes more pellucid and refuses to stain with colours, appearing to become vacuolar, which however, it does not, but rather reminds one of the external swelling undergone by a pellet of hard gelatine, when it is first steeped in water. This swelling goes on

until the cell has reached a comparatively enormous size, when the substance proper seems to melt away as a fluid, thus freeing its nucleus (or nuclei), which now becomes the actual cancer cell. This nucleus (or nuclei) has been increasing in size even faster than the cell substance, and within its area may be seen separate bodies growing not by fission but endogenously (probably from the nucleoli, although the large number of these bodies goes against the idea), and appearing now as the nuclei of the cancer or giant or mother-cell. In each of these nuclei (quondam nucleoli?) may be seen nucleolar (?) spots which stain intensely and grow to such a large size as to make it probable that separate spots exist within them in turn. The nucleus of the wandering (or lymph) cell, now itself become the cancer-cell, may increase in size to above 200 times the size of the original cell.

The subsequent changes in cancer-cells, as well as the change in the endothelium, and vacuolation, especially in the cells of the blood-vessels, will be considered at some future period, together with the changes in fixed cells. In the meantime, it may be remarked that the peripheral nuclei seen in some of the cells in the meshes of the lymphatic gland do not belong to the wandering or cancer-cell as apparently implied by Creighton, but to the endothelial cells which bound the cavity in which it lies.

Microscopical preparations and drawings illustrating all the foregoing conclusions have been submitted to your examination, and finally, I desire to express my sense of obligation to Mr. Milton, my colleague at St. John's Hospital for Diseases of the Skin, for having placed the present case under my care, as well as to the committee of that hospital for the facilities afforded me for its complete investigation. *April*, 1878.

---

15. *A case of chyluria.*

By Charles Henry Ralfe, M.D.

Mr. G. R C—, æt. 37, married, was first seen on the 31st October, 1877, on account of dyspeptic symptoms, consisting of pain

in the stomach, flatulence, frequent attacks of colicky pain followed by slight and transient jaundice. He gives the following account of himself. He was born in the Barbadoes, at the age of five years he had a severe fall which gave rise to a "rupture" on the right side. When twelve years of age he first contracted fever and ague and from which he suffered till he was twenty-one years of age. He left Barbadoes at that time, and went to reside at New York and remained there for six years, during which time he was perfectly free from fever and ague; towards the end of his sixth year of residence in that city he had his first attack of what he calls hæmorrhage of the kidneys, for which he was treated by Dr. Parker of New York, and obtained relief. He then returned to Barbadoes and the following autumn experienced another attack; two years then elapsed without a return of the complaint, but in the autumn of the second year it again recurred, and next year, after a long interval, he was again attacked with fever and ague, then a few months after the discharge from the kidneys recommenced, and continued for a period of two months. A few months after this last attack had ceased fever and ague again seized him and he had recurrent fits every three weeks till he became so exhausted as to be unfit for work, and on the 1st of October of the present year sailed for England. On the 13th of October he arrived in London and three days after his arrival he had an attack of hæmorrhage from the kidney which lasted two days, then stopped, and recurred again after an interval of seven days. His attacks of dyspepsia, which are asociated with his aguish feelings, he observes, are usually preceded two days before by a slight pain in calf of left leg, feeling of weight in pit of the stomach, with great inclination to stool, and great flatulence; then suddenly the bowels and stomach become cramped, producing the greatest agony, the pain going round to the back and producing a suffocating feeling in the chest; during the attack he frequently vomits four or five times and in the last vomit bile appears, and then relief ensues. The next day he notices that he is more sallow than usual and the urine is of dark colour.

The attacks of "hæmorrhage" from the kidney, which are quite independent apparently from these dyspeptic attacks, commence with a feeling of weariness and backache, pain in the testicles, with retraction of the left. The urine passed during this attack is milky, but if allowed to subside, becomes bloody at the bottom of the vessel with a coagulum at the top; in the West Indies coagulation

frequently occurred in the bladder to such an extent as to hinder the passage of water. The morning urine during the attacks is always clear, the milky condition being invariably noticed about noon.

I saw the patient for the first time on the 31st of October. He is of middle height, and weighs about 10¼ stone; is sallow in appearance, but appears fairly well nourished. Abdomen rather protuberant; extremities cold. Pulse feeble; tongue coated. Heart and lungs normal. Liver and spleen slightly enlarged. Urine, which was examined next day, clear, and free from any abnormal constituent. He was ordered to take bismuth and arsenic for the dyspeptic symptoms, and a pill containing two grains of Chian turpentine every night. This latter remedy was prescribed partly empirically and partly because he had experienced great benefit from a terebinthine mixture (probably eucalyptus globulus), prescribed for him in the West Indies when suffering from the discharge from the kidneys.

The patient was seen again on the evening of November 10th, when he brought some urine he had passed that day at noon, a portion of which is brought before the Society. He said that three days after his first visit he had an attack after a journey down to Dover. The urine he brought was milky in colour and perfectly free from urinous odour. After standing a few hours a delicate coagulum formed on the surface, whilst at the bottom of the beaker was a thin layer of blood. The fluid was slightly alkaline in reaction. Chemical analysis yielded the following results:—

Water . .	94·35
Solids . .	5·65
	100·00
Albuminous . .	1·45
Fat . . .	·78
Extractives . .	1·88
Salts . . .	1·02
	5·13

The albuminous constituents consisted of a small quantity of sero-albumen, a scanty precipitate only being yielded by the application of heat and nitric acid, fibrin, and a considerable quantity of an albumen non-coagulable by heat, but giving a curdy precipitate with acetic acid.

The fatty matters consisted of saponifiable fats, were of oily consistence at temperature below 60° F., and had a peculiar and penetrating animal odour. The extractives consisted mainly of urea. There was also a trace of glucose. Phosphate of lime and magnesia were present in considerable quantity in the orb. One point deserving of particular attention is the fact of the milky fluid passing very readily through the filter; indeed, far more so than is observable in ordinary albuminous urines.

Dr. Mitchell Bruce made a microscopical examination of the urine, which presented a dull grey semi-opaque appearance, and contained numerous red blood corpuscles; a few highly refracting protoplasmic particles; organisms, probably bacterial masses of corpuscles and epithelial matter, from the border of which large oil drops exuded; some clear casts, and several peculiar elongated or spear-shaped bodies, some stretching across the field of the microscope. They were almost the breadth of a red corpuscle, were strongly defined, highly refractile, and granular in their interior. Possibly they were altered filaria sanguinis hominis tumours.

November 20th, 1877.

---

16. *Chylous urine.*

By W. Howship Dickinson, M.D.

The urine exhibited was passed by a young woman in St. George's Hospital, named E. P—. As the details of the case are about to be published elsewhere, a brief notice will suffice here.

The case would not have been alluded to at present had not some others of the same sort been recently brought under the notice of the Society, and views elicited in connection with them which, though held by the older writers, are not those upon which the treatment of the patient in question was conducted, nor, as I would submit, are they altogether consistent with some of the circumstances of the disease.

The view which it is my purpose to controvert is that which dated from Prout, and attributes the chylous addition to the urine to a perversion of the renal secretion. Prout talked of *serous urine*, and *chylo-serous urine*, as if chyluria and albuminuria were nearly allied,

both being dependent on an alteration of renal function. And that the chyle was thus withdrawn by the kidney from the blood and discharged with the urine in the course of renal secretion, was advanced in explanation of a case before the Society, and probably represents the prevailing opinion upon the subject. Of late, however, it has been pointed out, more especially by Dr. Vandyke Carter, of Bombay, that chylous urine has exactly the characters which would be produced by a mechanical admixture of chyle with urine, and that there is probably in such cases a direct communication between the lacteals and the urinary channels. And I think that this view must be regarded as certainly correct, for not only does the urine contain the materials of chyle—fat, albumen, and fibrine—in the proportion in which they exist in chyle, but the fat is there in the actual molecular shape in which it occurs in chyle and nowhere else. The only doubts which can be entertained relate to the position and nature of the chylo-urinary communication. It may be presumed that the leak is not in the kidney itself, for chylous-urine never displays tube casts which it could not fail to do, containing as much fibrine as it does, were the exit by the renal tubes. And again, though our *post-mortem* evidence is scanty, yet it is enough to show that the disease is not accompanied with any constant renal change—of four cases the kidneys were described as normal in two, in one as fatty, as also were other organs, while in a fourth were seen certain fatty-looking channels alongside the uriniferous tubes which were possibly dilated lymphatics.

I am disposed to think it most probable, though in absence of further *post-mortem* evidence, the view can be but provisional, that the disease essentially consists in a regurgitation of chyle from the lower end of the thoracic duct to the bladder, and discharge by its mucous surface. What may be the nature of the obstruction which prevents the ascent of the chyle, or with what pathological conditions its regurgitation may be associated, it is not my present purpose to inquire; but it would not be right to pass without mention the remarkable observations of Dr. Lewis which associate the condition of chyluria with the presence of filaria in the blood, though the precise nature of the association has yet to be made out. The suggestion would obviously be that either by the presumably infantile filaria, or by a yet undiscovered parent worm, some obstruction in the thoracic duct is induced which hinders the upward current within it.

With regard to E. P—, I may say in brief that the urine was

frequently examined chemically with much the same results, but I will only subjoin the particulars of the first examination as sufficient to declare the nature of the disorder.

The urine passed in the twenty-four hours ending June 27th amounted to 1820 c.c. It had the appearance of rich milk, excepting that some shreddy colourless coagula, and some partially clotted blood, were seen at the bottom of the vessel. The twenty-four hours quantity yielded 16·926 grammes of hard yellow fat, like bees-wax, together with 24·388 grammes of albumen and fibrine together, the latter being in very small amount; and 15·47 grammes of urea.

Under the microscope the molecular base was less constantly obvious than in other cases I have seen. Sometimes it was perfectly distinct, sometimes too fine to be recognizable, even with high powers, as anything more definite than a cloudy loss of transparency. Blood globules were always present, together with rounded epithelial cells, such as might come from some parts of the vesical surface, but never casts, nor any certainly renal products.

The treatment of the patient was conducted upon the hypothesis of the mechanical regurgitation of chyle and the presumption that the surface of the bladder was the place of escape. Continuous pressure was directed by means of an abdominal tourniquet through the abdominal wall upon the lumbo-sacral promontory with the purpose of arresting at this point the regurgitating current in the lymphatics between the receptaculum chyli and the vesical region. The pad was adjusted by Mr. Pick at my request, so to diminish the pulsation in the femoral arteries, and no doubt to compress all the channels which pass in front of the lower lumbar vertebræ. The effect was immediate insomuch that the first urine, passed two hours after the application, was less chylous than any that had been previously seen, while the next, passed four hours later was to the great delight of the patient almost perfectly normal. It was of healthy colour and appearance which it had not been since the beginning of her illness, nearly two years back, and whereas the albuminous coagulum before the experiment generally amounted to one half, there was in this specimen scarcely appreciable cloudiness with heat and acid. The tourniquet was used at first by day only, afterwards for each alternate twenty-four hours, with the result that under each application the urine was less abundant and less milky than in the intervals.

I do not propose here to dwell upon the treatment excepting in

relation to pathology, but I may add that after about a month the good produced by each adaptation of the aneurysmal pad was not apparent, though the improvement in the general and local symptoms was sufficiently remarkable when the condition of the patient at the beginning of this treatment was compared with that at its close. Subsequently it was determined to attempt a further step by the use of astringent injections into the bladder, presuming that the chylous discharge made its way into the urinary channels ultimately by this surface. Perchloride of iron was injected and the product of the next micturition found to be notably less chylous. The injection was continued daily with further improvement and increased to the strength of 7 drs. of the tincture of the perchloride to 12 oz. of water. After a short recurrence to the tourniquet and another to the injection the urine ceased to be milky, then ceased to contain blood, then ceased to display albumen, and finally resumed its normal character in every respect save that it never ceased to display under the microscope scales of apparently vesical epithelium.

When the patient, a girl aged 22, left the hospital in April, she weighed 9 stone 6 lbs. 8 oz., having on her admission in the preceding June, weighed but 4 stone 13 lbs. 2 oz. She was plump, rosy, active and contented, and bore but a remote resemblance to the pale, emaciated and prostrate person, who on her admission could scarcely stand without help or speak without crying.

December 4th, 1877.

---

17. *A case of chylous urine, in which the fatty principles were in part crystallisable, and in which the presence of sugar was satisfactorily determined.*

By Alexander Morison, M.B. Edin.

The following instance of a disease, the causation and pathology of which is still wrapped in obscurity, but in our knowledge of which we have lately made considerable progress, derives especial interest from its being, so far as I can discover, the first well-marked case of chylous urine in which sugar has been satisfactorily determined; and from its likewise being the second recorded case of that kind of urine with crystallisable fatty principles. Dr. Roberts, in

the most recent edition (1876) of his 'Practical Treatise on Urinary and Renal Diseases, &c.,' adheres to a statement he makes in a former edition of the same work, viz., that the ethereal extract of chylous urine yields, on evaporation, uncrystallisable fat; and further states in the same place (p. 322), that sugar has never been found in such urine. The former of these statements he qualifies in a foot-note by alluding to Bramwell's case in the 'Edin. Med. Journal for 1858,' but seems to doubt the reliability of this solitary exception. In what follows I shall endeavour to give satisfactory evidence both of margaric crystallisation and of the presence of sugar.

Mrs. M—, æt. 56, a Jewess, and the descendant of a race of Jews settled for generations in Algeria, left Algiers in 1846, was a resident in Marseilles and Paris for eighteen years thereafter, and has lived in England for the last thirteen years; in other words she has lived in Europe for about thirty-one years.

She is a member of a healthy family, and has herself enjoyed robust health, having borne eight children, and performed all her functions normally, until about five years ago. Up to this date she had for a considerable time been unusually stout, and had always had a *penchant* for richly-cooked oily food. About four years ago she ceased to menstruate, and began to decline in health; but during the twelve months preceding her final menstruation, she states that her urine was milky at irregular intervals. Her health continued to fail, and her stoutness to diminish, but she affirms that for nearly a year after the cessation of the menses, her urine had a normal appearance, when it again resumed its milky character. After this event her health deteriorated still further, and her former obesity gave place to progressive emaciation. With the exception of the period stated, during which the urine is said to have returned to its normal condition, it has been constantly milky. Some time before the patient came under my observation the quantity of her urine is stated to have been increased, and she says that when such was the case her thirst was excessive. This condition, however, is said to have been transitory. When I first noted her condition, the patient was seen to be a tall gaunt woman, of an Asiatic type, with a sallow complexion, hollow cheeked from emaciation, and apparently in a very debilitated state. Her chief complaint was of a general sense of weakness and inability for exertion, together with severe lumbar pain, passing round the right flank, tenderness on pressure in the

right iliac and hypogastric regions, while the corresponding regions on the left side were free from discomfort; loss of appetite, constipation, and the passage of urine of a milky appearance, sometimes mixed with colourless clots, which block the urethra, interrupting micturition, and ultimately being voided in gelatinous masses, with considerable pain.

It appears that the patient was at one time under the care of Dr. Arthur Leared, who, in a memorandum furnished to the 'British Medical Journal' for December 1st., 1877, states that the vital signs of the case at that time were "much debility, pain in the lower back, extending along the outside of the thighs to the knees, absence of perspiration, troublesome heat of the hands and feet, and thirst; 'the legs,' he also states, were œdematous," and they are slightly so still, though much less so according to the patient than formerly. The left leg is decidedly more œdematous than the right, and a varicose condition of the veins is likewise most evident in the former. I shall summarise as succinctly as possible my notes of the case extending over a period of six months, during which I have examined the patient's urine on fourteen occasions, and her blood twice, and during which I have had repeated opportunities of noting her condition generally.

The urine.—The whole quantity of the urine which was at one time increased has been normal for the greater part of the time during which I have attended the patient, but on the 21st of November last she informed me that the excessive thirst she used to have before I saw her, had returned for a short time, compelling her to drink more frequently, and on measuring the urine passed during twenty-four hours, the quantity was ascertained to be three and a half pints. When I next saw her, however, she informed me that her excessive thirst had again disappeared.

The colour of the urine is variously noted as "opaline, dimly translucent, opalescent, opaquely-opalescent, of a rich cream colour, densely opaque and cream coloured, the colour of dirty milk," and so forth. The urine was opalescent on those occasions on which it was least opaque. As a rule the morning urine is less opaque than that passed at other times during the day, the opacity increasing as the day passes, and as meals are taken, until the evening urine is usually densely opaque and undoubtedly more milky than at any other time. The morning urine is sometimes, though rarely, quite as milky as at any other time. When the patient says her urine is

quite clear and natural, I have found that it is distinctly opalescent though not opaque, and has all the characters of chylous urine. For the four and twenty hours, from 6 p.m. on the 16th of September till 7 p.m. on the 17th, being the "Day of Atonement, or White Fast," she, as a Jewess, neither ate bread nor drank water. While thus fasting her urine was clearer than before fasting, and again became very milky, though free from coagula, on the morning of the 18th of September, she having partaken of some bread, milk, coffee, and broth, on the evening of the 17th, when the term of fasting had ended.

The highest *specific gravity* determined was 1040, the lowest 1017, and the average struck from twelve estimations about 1028.

On one occasion the fluid surrounding a large coagulum had a specific gravity of 1013, and on another occasion, after separation of the clot, the specific gravity of the fluid portion was 1035.

The *reaction* was generally distinctly acid, but on rare occasions blue litmus was only faintly reddened. The ordinary test for urates and phosphates was inadmissable on account of the opacity of the urine, and their presence was not otherwise chemically determined.

Spontaneous coagulation was noted on six occasions, overlooked or absent on four, represented by a slight flocculent deposit on one occasion, and positively stated to be absent on one.

When the urine was allowed to stand for a short time, the coagulum was usually deposited in a gelatinous mucoid mass, which after a time again broke up into shreddy material.

Mucoid coagula were also occasionally observed floating near the the surface of the urine. The following is the description of the most perfect spontaneous coagulum observed, transcribed from my note book, the urine on that occasion having been opalescent and translucent:—"on holding the bottle up to the light, a distinct coagulum of delicate structure is seen to occupy the whole column of the urine, being most consistent and dense at the bottom where it is impregnated with a granular deposit; from this base, which presents a slightly concave face to the bottom of the bottle, the coagulum rises somewhat cone shaped and of a beautifully delicate texture, which seen through the opaline fluid which surrounds it reminds one of the texture of some of the smaller medusæ, until it terminates in a more consistent apex. Surrounding the clot on

all sides is a layer of fluid the sp. gr. of which is 1013. The coagulum though so delicate and requiring careful observation to follow the continuity of its outline from base to apex, was so tenacious, that on pouring the urine out of the bottle, the neck of the latter was completely plugged and before the clot could be extracted the bottle had to be broken, when the trembling jelly escaped *en masse*." For a considerable period latterly, the patient says her urine has been quite free from clots.

Artificial coagulation.—On heating the urine a dense white flocculent coagulation, pervading the entire column of urine tested, always occurred. Nitric acid invariably produced coagulation. Dilute muriatic and sulphuric acids did not coagulate the urine, and the same acids undiluted, produced the merest trace of increased turbidity, so that one could not positively assert whether any coagulation had taken place or not. There was the most marked contrast possible between the effect of these and of nitric acid.

Sugar was unmistakably present on twelve occasions, not so distinctly on two, when the specific gravity of the urine was 1018 and 1017 respectively, but in the urine surrounding the coagulum already described, the specific gravity of which was 1013, the presence of sugar was quite apparent. Trommer's copper and potash test was the test employed, concerning the unreliable nature of which, much has of late been written. Four to six drops of a recently made solution of sulphate of copper containing four grains to the ounce, added to about two drachms of urine in a test tube, on the addition of about half a drachm of liq. potassæ (which is usually just sufficient to dissolve the precipitate which forms on its first addition), has always yielded in my hands the characteristic indications of the presence of sugar in cases of glycosuria and has failed to yield these signs where the absence of sugar was contra-indicated by other circumstances. If added to the urine unfiltered, the result was a dirty orange passing into a muddy chocolate colour. But if the urine was previously coagulated by heat and filtered with or without the addition of acetic acid, the usual pale orange gradually becoming darker was produced, until on continued boiling and shaking, the fluid became of a dark brown. Dr. Leared in the place already cited, says that indications of sugar were well marked with Trommer's test when he examined the infiltered urine, but that the same sample of urine when *filtered* did not yield these

indications. And here I may mention that on endeavouring to filter the urine on one occasion *without previously coagulating* it, preparatory to testing for sugar, I was struck by my failing altogether to clear the turbidity of the fluid; it quickly passed through the filtering paper unchanged, even when every precaution was taken to see that the latter was complete and also when two cones one within the other were employed. The filtrate obtained by coagulating and filtering is likewise faintly opaline, but this may be removed by adding an excess of alcohol (sp. gr. 1800) and refiltering. When the mucose clots are removed from the urine and carefully washed they continue for a length of time to impart a milky appearance to the water, but may ultimately be washed clean. A portion of clot shaken up in a test tube with water does not seem to disintegrate appreciably but when caustic potash is added it separates into minute flocculi. If to this alkaline solution a few drops of sulphate of copper be added and heat applied the sugar test remains negative. Alcohol by the withdrawal of water from the coagula, gives them a white shrunken appearance. If the milky urine be agitated with sulphuric ether, its opacity is removed, sometimes completely, at others in great measure, while its viscidity appears to be increased. If the test tube be now allowed to stand for a short time, the ether will disengage itself and float at the surface and separating the ether from the urine a narrow stratum of oil may be observed.

Microscopic examination of the urine.—The microscopic objects observed, taking several examinations collectively, were torulæ cerevisii, leucocytes, uninuclear corpuscles, a few red blood-cells, and epithelium from the genito-urinary passages, and also small rounded bodies with a bright refracting centre but not capable of further differentiation. The microscopic characters of the spontaneous coagula were those of the fibrin of blood; delicate granular or homogeneous bands traversing the field of the microscope and entangling a few blood and lymphoid cells.

Amorphous urates, and on one occasion peculiarly shaped crystals of uric acid, resembling those figured by Beale in his tables of urinary deposits, p. 14, pl. v, fig. 9 and 10, octahedral crystals of oxalate of lime, and crystals of triple phosphate were likewise observed. A drop of saccharine and chylous urine allowed to evaporate slowly on a slide, also showed crystals resembling those of grape sugar, which gave the dextral refraction to polarized

light. Test tubes in which urine has been cleared by sulphuric ether and allowed to stand till the latter has evaporated, show a ring of crystals above the level of the fluid, which may be stellate and indistinguishable from crystals of margaric acid or curved and feathery like those of stearic acid. The yellowish layer which rises to the surface of the urine after agitation with ether has the microscopic appearance of olein, that is it consists of oil drops. Tube casts or the parasite named by Dr. Lewis, Filaria sanguinis hominis were never recognised, the only objects in any way resembling them being fragments of hair and cotton which there was of course no difficulty in distinguishing.

Symptoms referable to the genito-urinary system.—The patient's most constant complaint is of pain in the lumbar region, passing round the right flank, with tenderness on pressure in the right iliac and hypogastric regions. These symptoms are not always equally severe. Frequently after they have been excessive for a time, the patient affirms that she feels "something burst in her side," after experiencing which sensation she is usually relieved and notices that the urine voided contains coagula, and occasionally coagulation takes place within the urinary apparatus, so that micturition is completely obstructed for a time, and it is only after repeated efforts that a clot or clots of the description already given are expelled, and urination completed. The entire sequence of these symptoms when they are pronounced, leaves the impression that some such body as a coagulum in travelling down the ureter, possibly having formed in the pelvis of the kidney, and that it finally "bursts" to use the patient's expression into the bladder, to be ultimately extruded per urethram.

A careful examination of the genital organs showed these to be normal in every respect, and there is no evidence whatever of any disease of the bladder.

State of the digestive system.—The patient's appetite which was greatly impaired when I first saw her, improved on regulating her diet, and on the removal of constipation. The tongue until recently was constantly covered by a soft white fur. The dimensions of the liver and spleen are normal. In place of her former corpulence, the patient is now comparatively emaciated.

State of the circulatory system.—The heart sounds are normal but the action of the organ is weak, and the patient occasionally faints. The pulse as a rule beats from 72 to 78 per minute, is

always regular, but varies in fulness and in strength. A microscopic examination of blood drawn by puncture from a finger on two occasions was normal in every respect, both as regards the ratio of colourless to coloured cells, and the absence of anything resembling the filaria sanguinis hominis.

State of the respiratory organs.—Normal.

State of the skin.—Normal. There has never been any eczematous eruption about the pudenda or elsewhere, nor any other form of skin disease whatever.

State of the nervous system.—The patient is intelligent, and frequently vivacious, when not discoursing about her own ailments, but excessively despondent and on the brink of syncope when this is the theme. Her general activity is, however, much impaired, and she looks and feels debilitated, and walks with a slow and feeble gait.

State of the special senses.—There is a small central opacity, perfectly white, in the left pupil, which is situated either in the crystalline lens or its capsule, and does not exhibit the ophthalmoscopic characters of cataract in this situation, nor is there any evidence of cataract in the right eye. The statement of the patient that it was first observed after an attack of smallpox at the age of two years finally disposes of a diabetic origin for the opacity. The other senses are normal.

Remarks.—The appearance of chyluria in this case, after a residence of thirty-one years in Europe, probably excludes the possibility of the causation of the disease by any endemic influences prevalent at the birthplace of the patient in Algeria. In searching for a rational explanation of the conditions related, I would ask whether chyluria and glycosuria exist in this instance as *independent* but *contemporaneous* diseases? Or, whether the sugar in the urine is derived from the *chylous elements?* If the latter, why is sugar not a more constant ingredient of chylous urine? If the former, may we assume from the circumstance that chyluria first made its appearance during the year preceding the cessation of the menses, that the genital irritation so frequently met with during the climacteric period, was the excitant to an excessive glycogenesis, in one addicted to a rich oleaginous diet; and, that an organism which could decompose even an excess of chylous material, when all other destructible elements were in normal proportion, failed to act so perfectly, when a greater call was made upon its capabilities, by an excessive production of sugar, causing the decomposition of this, as

of chyle, to be incomplete, and hence the excretion of the surplus of both by the kidneys? If this were so should we not meet with chyluria more frequently in connection with glycosuria? Or again, do the unilateral pain, and other symptoms detailed, together with the frequent formation of mucoid coagula in the bladder, indicate a leak in the lymphatics of the urinary tract on that side, giving rise to excessive thirst, a greater consumption of fluid consequent upon this, and a proportionate increase in the quantity of the urine; just as we have these symptoms arising in connection with hæmorrhage, to which the abnormal escape of chyle is, of course, closely related?

December 4th, 1877.

---

18. *Fat from a case of chyluria.*

By W. Miller Ord, M.D.

The considerable quantity of fat here shown was obtained by me last autumn from the urine of the case described this evening by Dr. Dickinson. I lost sight of the case through a miscarriage in the post, letters of mine making appointment being returned to me through the dead letter office. I am, therefore, greatly relieved by finding the patient in such excellent care, and, as Dr. Dickinson has put before you the clinical facts of the case, I will confine my remarks to the state of the urine at the time when I saw the patient. These remarks form a sort of pendant to Dr. Dickinson's, our observations having been made from somewhat different standpoints.

The patient came to me complaining of constant lumbar pain and rapid loss of flesh. The urine brought for examination was of milky appearance, but tinged with blood, so as to have the look of strawberry cream, and contained numerous rounded, soft, semi-transparent pinkish bodies, many of them in botryoidal masses. These, which looked at first like uterine hydatids, proved on examination to be clots of fibrin entangling a little blood, and many large, soft, nucleated, protoplasmic bodies. The urine smelt like milk; was of sp. gr. 1010; and was neutral in reaction. On boiling it was partially coagulated, lost its pink colour, and gave off an urinous odour. On the addition of nitric acid a very copious flocculent precipitate

was thrown down. The urine did not reduce Fehling's solution after boiling, the addition of a few drops of acetic acid and filtration. On the addition of an equal quantity of ether to the urine the milky appearance was at once removed, the ether floating on the top of a clear reddish fluid, with a granular deposit just underlying the ether. The ether on distillation yielded the fat now shown.

Under the microscope the urine was seen to be filled with fine molecules, apparently spherical and of uniform size, exhibiting most active Brownian movements. They corresponded exactly with Mr. Gulliver's molecular base of chyle, and were recognised as such by his son, who happened to be working with me at the time. There was some free fat also.

The urine was on another occasion examined immediately after being passed. It contained no clots, and the milky odour was very marked. Coagulation occurred within about a quarter of an hour, the clot being a large, very soft one.

It was evident that the fluid was urine, and that it contained no sugar, but abundance of fat and albumen. In evaporation a pellicle formed on the surface of the urine like that formed on milk in similar circumstances, and consequently a part of the albumen was in the state of alkali-albumen, while another part was in the ordinary coagulable form.

The nature of the "fat" appeared to me worthy of investigation. First, as to whether it was neutral or acid fat; second, as to whether any of the highly phosphorised matters soluble in ether were present. Dr. Thudichum, who has taken interest in this subject, was good enough to make an examination of the fat; and I subjoin the general result.

The "fat" contained, in the first place, sodium and potassium albumen in addition to free fat. The free fat was composed of neutral fats (palmitin, stearin, and olein), with a very small quantity of free fatty acid. There were no phosphorised fats such as Eggel has described. The fat was present in the proportion of ·47 per cent. of the urine, or 4·7 grammes per litre; the quantity exhibited was yielded by a pint and a half of the urine.

As regards the fats, the quantity present was not so large as in some recorded cases, Dr. Beale having found as much as 13·9 grammes of fat per litre. Ackermann has denied the existence of free fatty acids in chylous urine, in opposition to Dr. Thudichum's opinion that they are present. This case tells in

favour of Ackermann, the proportion of fatty acid found by Dr. Thudichum being very small. The absence of such matters as lecithin and its derivatives is interesting to me, as I have on one occasion found them in fatty substances from urine.

It may be observed that the microscope did not show any indications of entozoa in the urine or in the blood, although repeated search was made in both. The blood was healthy, and there was no milkiness of the serum. The patient had never been out of England; neither had her parents. *December 4th*, 1877.

---

19. *Elephantiasis of the clitoris.*

By Dr. London, of Carlsbad.

(Communicated by the President.)

Nassra Bint Issaen N—, a girl, æt. 24, from Bethlehem, came (on the 12th of July, 1875), with her mother to the hospital at Jerusalem, to consult me about a tumour at the entrance of her vagina. She stated that this tumour had been originally very small, and had gradually increased in size. On examining the parts, I found the lymphatic glands swollen in both inguinal regions. In the region of the clitoris, there was in place of the normal clitoris a pear-shaped compact-elastic tumour. The upper (smaller) part of this tumour measured about 14 centimètres in length, and 11 centimètres in circumference; the lower (larger and roundish part) was about 25 centimètres in circumference. The tumour was, especially at its lower part, excoriated, covered with wet ulcers and crusts, produced by the friction of the dress and legs on the hypertrophied part of the tumour, and also by the irritation of the urine. At the first sight this tumour had more the appearance of a scrotum, than of a clitoris; but on a nearer examination I found that we had to do in this case with an *elephantiasis of the clitoris*. According to the explanation of the girl's mother, the clitoris had been, immediately after the birth of the child, much larger than a normal one and had gradually increased in size; at the age of 24 years it attained its present form. She reported to me as a remarkable fact, that sometimes the girl suffered from fever and from intercurrent erysipelatous inflammation of the clitoris.

The other genital parts were quite normal. The hymen was intact. The catamenia have been always regular in time.

Regarding the *etiology of the case*, I could not find any rational cause of the elephantiasis. Although the girl confessed openly and "sans géne," that in consequence of a perpetual irritation in the clitoris, she was obliged very often to rub and to drag this part, nevertheless I do not think that this could be the only cause of the elephantiasis. If so, we ought to have much more elephantiasis of the clitoris in Europe too than we actually have.

WOODCUT 15.

Nor can I agree to the assumption, that the antecedent and still intercurring attacks of erysipelas were the *only* cause of the present elephantiasis, because the commencement of the disease had been (according to the above-mentioned words of the mother) remarked immediately after the birth of the child, and besides, I have observed many cases of elephantiasis of the clitoris without preceding erysipelas and without fever. The girl, who was engaged and intending to get married in a short time, asked me to remove the tumour as soon as possible.

To prevent a great loss of blood, I decided to remove the tumour with the écraseur of Chassaignac. The operation was performed

on the 26th of July, and she was completely delivered from her burden. The loss of blood was very immaterial. The wound cicatrized completely. A small stump, as large as a pea, marked the spot of the removed clitoris. The removed tumour consisted of an accumulation of condensed epidermis-cells, in diffuse meshes of hypertrophic subcutaneous cellular tissue, containing a serous yellowish-red fluid. The corpora cavernosa were on both sides of the upper part of the tumour easily distinguishable. They were in their size (circumference) larger than the normal ones. Besides this, muscular elements also were visible under the microscope.

The vessels, especially the veins and vasa lymphatica, were enlarged in their circumference. The fluid in the meshes of the subcutaneous cellular tissue showed under the microscope blood discs and pus cells. The weight of the removed object was about 1·80 kilo (=4 lbs.)

Elephantiasis of both hands and feet.—Dr. London also sent for exhibition some photographs of cases of elephantiasis, of the most striking of which the subjoined woodcut is a copy. It was taken from a negro boy 19 years of age, who was suffering from elephantiasis of the hands, and in a less degree of the feet. Dr. London

WOODCUT 16.

could get from the boy no definite account as to the origin of the disease, which appeared to have been gradually coming on since childhood. *April 24th*, 1878.

20. *Cases of filarious disease.*

By J. Bancroft, M.D., Brisbane, Australia.

(Communicated by the President.)

In the year 1874, when in conversation with the late Dr. Thomas Rowlands, of Ipswich, Queensland, I mentioned that cases of chyluria had come under the notice of the medical men of Brisbane for some time past; the first having been noticed by Dr. Mullen, in the person of his coachman. Dr. Rowlands informed me that he also had found a case, and having read of the discovery of filariæ by Dr. Lewis in India, had sought for the same in urine and had seen specimens. He had not examined blood but would be glad if I would do so. I accordingly examined some blood from Case No. 2 on the list, and finding filariæ transmitted specimens to Dr. Rowlands, who replied to me as follows:—

"*Ipswich, December 5th*, 1874.

"My dear Doctor,—Many thanks for your capillary tube containing blood, which, however, reached me in a much pulverised condition; notwithstanding this I was able to get very satisfactory results by placing the fragments on a slide and treating them with one per cent. solution of common salt. I have no difficulty in recognizing my old acquaintances, but I find in the specimens received from you one condition said to be characteristic of the filariæ, which condition I was unable to detect in the specimens which I had discovered in urine, possibly owing to saline constituents of the urine (perhaps ammoniacal) affecting them. I am alluding to the delicate enveloping sac.

"Very faithfully yours,
"Thomas Rowlands."

On referring to the writings on chyluria of my teacher, Dr. Roberts, of Manchester, and to the work of Dr. Cobbold on Entozoa, and finding no account of this parasite, I forwarded to the former blood containing filariæ. Dr. Roberts replied to my letter in February, 1875, to the effect that my specimens were destroyed in the post, and requested me to send others.

I then sent a fresh lot of tubes in a metal case, asking also that Dr. Cobbold should have some of them.

Dr. Cobbold, on June 24th, 1876, in the 'British Medical Journal,' published an account of his examination of these specimens, and sent me the same by letter, which I received on September 28th, 1876.

The information that this was only the young of a yet to be discovered parasite caused me to take great interest in the matter. I had observed that two cases of chyluria (Nos. 1 and 2) had suffered from abscess arising spontaneously, after which both cases got well.

Neither case had any parasites in the blood. This led me to suspect that possibly the parent worm had been discharged in the matter of the abscess. I compared, then, all the circumstances with what was written by Dr. Cobbold and others of guinea-worm. It seemed to me that the way would be to examine the pus of abscesses carefully for any appearance of *débris* of the parent worm. Accordingly I collected the matter of many abscesses and examined the blood of the patients for filariæ.

On November 8th, 1876, a youth (No. 8) presented himself with an old suppurating steatoma of the ear. As it is not possible to dissect out these cysts I excise a large piece of the superficial skin. This allows the old cysts to granulate up. Scraping blood from the excised portion of skin, I placed some under the microscope, and to my astonishment found filariæ. I could find nothing in the contents of the cyst but the usual matter.

On the evening of December 21st, a youth (No. 9) called on me with an abscess on the inner side of the upper arm, about the size of a walnut; the lymphatics were also red and painful. I opened the abscess, and, according to my practice for the past three months, collected the discharge in a glass vessel.

Then I placed a drop of blood under the 2-inch object glass, flattening it somewhat, but using no covering glass. This I find the readiest way of detecting filariæ. Filariæ were seen. In the course of the evening I examined the matter, mixing it very carefully with water. Among the contents was a thread-like body; it became broken in my manipulations. On examining it microscopically, I found attached to two processes from one end of the specimen oval cells with granular contents, others had in them rudimentary filariæ, and loose inactive filariæ, with granular structures in the usual form of sheath, were also seen detached therefrom. I now collected the broken fragments in glycerine and wrote a letter to

Dr. Cobbold, describing the case, but deferred sending it in hopes of a better specimen. As the subject now became more interesting I will relate in detail the cases as they happened, giving a tabulated form at the end of this paper to include them all. My patient, in whose abscess the adult filaria was discovered, was a butcher's boy. He had been carrying baskets of meat on horseback and might have hurt his arm. His abscess healed in a few days; several months later another abscess formed in the arm. From this no parent worm was obtained. Microscopic filariæ were still found in the blood.

January 10th, 1877.—Dr. Blundell brought me a patient (No. 10) with an abscess of the arm. This man was a butcher, and had previously consulted me for a painful condition of the inner side of the upper arm, which had existed at times for five years, causing contraction of the structures around the brachial artery. The blood contained microscopic filariæ, but the abscess gave no trace of adult worm. As the abscess was over ripe, possibly the parent worm had liquefied. The blood of this patient contained filariæ for several months later. The arm gained greater freedom of motion and became much more comfortable.

12th.—A female patient (No. 12) was sent to me by Mr. Andrews, surgeon, of Brisbane. She suffered from chyluria, and at times large clots were with difficulty discharged from the bladder. She was suckling a child. I examined a drop or two of blood, but did not find filariæ. She improved much by taking an acid iron mixture.

31st.—A patient, a butcher (No. 11), whom I was attending for syphilis, called. Having found two butchers previously with filarious blood, I took blood from a scrotal vein. This is a very convenient way of obtaining blood. He had enlarged testicles. The blood contained filariæ. I attended him with pneumonia of a mild type with hæmoptysis about a year ago. Subsequently nothing more interesting occurred to him.

I resolved now to examine blood of the domestic animals, and dissected an old goat belonging to a family in which two children (Nos. 2 and 3) suffer from chyluria and filarious blood. Nothing was discovered. I examined, then, the blood from forty slaughtered animals, sheep, pigs, and bullocks. The blood of some presented most remarkable appearances, but I found no trace of filariæ.

February 2nd.—(No. 16.) Patient from the interior with hydrocele. Tapped it, finding chylous fluid. Filariæ in it

numerous. 9th.—Blood from mosquito bite on the arm contains filariæ. The hydrocele, which was injected with iodine, progressed favourably.

8th.—Mrs. —, (No. 17). Had inflamed lymphatics of the arm. Previously had abscess of the same part, which healed after a medical man had opened it. Took some drops of blood and found filariæ. Water dressings were applied which relieved the inflammation. In other respects she is quite well.

15th.—A blacksmith (No. 14), suffered from soft tumours of the groin, with shivers and fever. Similar attacks occurred several times in the course of the past year. I had examined his blood often before, feeling sure that he is afflicted with filariæ, but with negative results. To-day the right testicle is inflamed and very painful. I pricked the testicle and found filariæ in the blood. He has had two abscesses of the arm four years ago.

20th.—(No. 18.) A youth, an iron-founder, has inflammation of inner side of left arm. He has two scars there, the cause of which he does not remember. Has a small soft tumour of the left groin, and a large varicocele of the right spermatic cord. Blood contains filariæ. March 6th.—Had severe attack of orchitis with febrile symptoms, which lasted some days.

March 5th.—A drayman (No. 13) called to see me about his wife, who was ill. I remembered attending him previously for shivers, lymphangitis of right arm, which ended in abscess, and was opened. I now examined for the first time his blood, and found filariæ.

5th.—A road labourer (No. 15) passes blood-stained urine. A clot forms in the urine which floats. Sediment of urine contains filariæ.

14th.—A young man (No. 20), engaged on the railway works on the Darling Downs, came to Brisbane. He had abscesses of the lymphatics of the right arm; also had orchitis. 17th.—Examined blood and found filariæ.

April 12th.—Opened pelvic abscess at Poupart's ligament. I examined the blood of mosquitos that had bitten this patient, but found no filariæ. Patient recovered, and went to work at the end of the month.

March 21st.—A carpenter, æt. 50 (Case No. 26), called to consult me about a hydrocele of the cord. I tapped it with a trochar of a peculiar form that I use for this purpose. This has a lancet-shaped piercer soldered on a tube with two lateral apertures below the

point. About 4 oz. of fluid escaped, presenting the usual appearances. On withdrawing the trochar I observed a red hair-like mass entangled in the aperture of the wound. This I carefully extracted, and placed in the fluid of the hydrocele. The hair-like mass now commenced the most active motions. I examined the patient's blood, and found microscopic filariæ. The coiling and uncoiling of the worms in the hydrocele fluid were very rapid, and the mass in this condition spread over an extent of three or four inches in each direction. My friend, Dr. Mullen, who takes great interest in filarious cases, came to inspect them. Lifting the worms out of the hydrocele fluid and placing them in water they stretched themselves out and became quiet. Now, I found there were four worms entangled. I replaced them in the hydrocele fluid, and after a short time they recovered their activity.

I kept them about thirty hours, during which time their movements continued unimpaired; then placing them in water, I spent over an hour in uncoiling them from each other.

Under the microscope tubes escaping from their bodies were seen to contain great numbers of filariæ, loose, but lying alongside of each other with some regularity.

Further along the tubes were less developed filariæ, each included in an oval shell, and still further ova in a more rudimentary condition. I placed the specimens in glycerine, and now ventured to address Dr. Cobbold.

An extract from my communication appeared in the 'Lancet' of July 14th, 1877, and drawings of my specimens in the number of October 6th.

In the 'Lancet' of September 20th are drawings of portions of a similar worm, found on August 7th of the same year by Dr. Lewis, of Calcutta, obtained by him from a scrotal tumour that had been amputated. The sexual aperture of the parasite is not figured in Dr. Lewis' specimen, but is demonstrated in that drawn by Dr. Cobbold.

To return to my cases, of which I will now mention only the more interesting.

Threatened elephantine leg.—May 18th. Found a youth (No. 22) suffering from abscesses of the glands of the neck. During the past year he had on three occasions shivers and fevers, with inflammation and swelling of the leg, causing lameness.

I opened an abscess of the neck, but found no parasite. I took

blood home with me, and found filariæ. The disease of the leg extending, I conceive, would lead to elephantiasis.

June.—The steatoma of the ear, previously related (Case No. 8), which gave filarious blood, led me to remember having removed several such tumours formerly. One boy (Case No. 23) working as a plumber, from whose cheek I had excised a similar growth two years before, I sent for, and examining his blood, found it to contain filariæ; then directing my attention to the condition of the genital organs, noticed that he was suffering from hydrocele and elastic tumour of the groin.

Shortly after this, a youth (Case No. 24) came to me with a steatoma over the malar bone, as represented in the photograph (Woodcut 17). His blood contained filariæ, in other respects he was in good health.

WOODCUT 17.

I afterwards removed the tumour. The contents consisted of cholesterine and granular matter with epithelial cells. Nothing further could be discovered. This peculiar steatoma appears to indicate filarious blood and deserves further examination.

Soft tumour of the groin and axilla I venture to call *Helminthoma elastica*. I have verified its filarious nature in six cases. It

is the softest and most elastic of all tumours with which I am acquainted.

June 24th.—A youth, æt 20 (Case 25), was shown to me by Dr. Thomson, house-surgeon to the Brisbane Hospital. A swelling existed under the right pectoral muscle, extending from the axilla to the clavicle (see Woodcut 18, taken from a photograph).

WOODCUT 18.

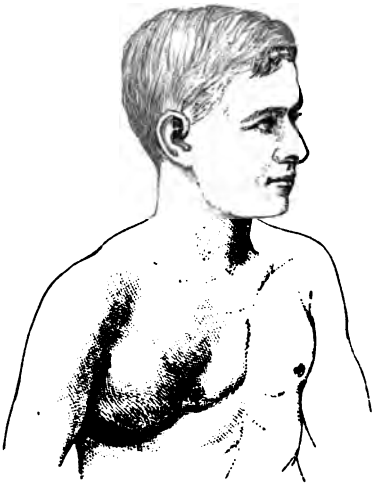

The peculiar elastic nature of it was unmistakable. I examined several specimens of the blood of this patient but failed in finding any filariæ. To make quite certain, I introduced a tenotomy knife into the centre of the tumour. A discharge of bloody serum followed in which filariæ were abundant. By pressure, about 6 oz. of fluid were discharged. This procedure was repeated at intervals of several days, but as often the tumour filled again—even increasing in size. Injections of iodine and several setons were tried but without success in reducing the swelling. I decided to remove the tumour by excision. On cutting through the fascia covering it the tumour presented an appearance like very large everted piles. These were cyst-like, and in consequence of much manipulation being required to detach them a rupture took place by which the structure collapsed in a great measure. Much blood and serum were lost during the extirpation of the mass which extended to the subclavian artery. The extirpated tissue I afterwards dissected, but

neither in it nor in the blood did I find any adult parasite. My attendants had, however, thrown away a quantity of the blood without examination. The patient suffered a severe attack of fever after the operation. I left a few days later to visit England, and had information from Dr. Thomson of the further progress of the case.[1]

The elastic tumour I conceive to be a varix of the lymphatics. It does not always contain blood though probably bleeding frequently takes place into its cells. It appears much of the same character as the swelling of lymph scrotum and the other lymph discharging tumefactions. (See Dr. Roberts' cases of chyluria and lymph vesicles on the abdomen in his work on urinary disease.)

I saw lately in Singapore a case of elephantiasis in which lymph vesicles had opened near the foot in former years discharging much fluid. I suppose chyluria to be the result of lymph vesicles opening on the mucous surface of the bladder or other part of the urinary track. This would account for the irregular nature of attacks of chyluria and its attendant hæmaturia.

By the kindness of Dr. Rowell, of Singapore, I was enabled to examine the blood of two cases of elephantiasis. These had suffered from the disease many years and in their blood no filariæ were found. This may be accounted for by supposing that the parasite causing the disease lives only for a few years at most.

The following case of commencing scrotal tumour occurred in Australia, and was brought under my notice by Dr. Concanon, of Dalby. The photograph shows a very rugose enlargement of the skin of the scrotum. There was no discharge of any kind and the skin was not inflamed when I saw it. The blood of the patient contained filariæ. A month later elastic tumours were commencing in both groins. According to the above supposition all scrotal tumours and elephantine legs will be found filarious if examined during their growing period.

There are some cerebral disorders that I also suspect to be filarious.

The following is not included among the thirty-one cases in my list:—

A youth, æt. 19, was admitted into the Brisbane Hospital with general debility. He had been working on a farm and about a year

[1] The patient was dangerously ill. He had abscesses form in the neighbourhood of the shoulder-joint, in the upper arm and pelvis. Dr. Thomson was unable to find any parent-worm in the discharges, nor microscopic filariæ in the blood.

previous had consulted me for elastic tumour of the groin. About a week after admission he became comatose and died in three days. *Post-mortem* examination showed a slight form of serous apoplexy. At that time the significance of elastic tumour was unknown to me.

A little girl that I had treated for bad glandular abscesses, much resembling Case 22, was taken with cerebral disorder and died. An abscess of the brain was found with distinct and strong limiting membrane. A similar case I remember many years ago. These cases were most likely filarious. Thinking of them, I paid a visit to the Lunatic Asylum of the Colony, and by the assistance of Drs. Thomson and Webb, examined blood from thirty lunatics selected without discrimination. In none of these were filariæ found. Ophthalmoscopic examination of the retinæ of filarious subjects gave negative results also.

The following diseased conditions are probably associated with filariæ:—

Chyluria, with or without admixture of blood.

Hæmaturia, with no chylous admixture.

Plugging of urethra from clots.

Anæmia from chyluria and hæmaturia.

Tuberculosis following chyluria. See Dr. Roberts' case.

Hydrocele containing chylous fluid and microscopic filariæ.

Hydrocele with clear contents and adult filariæ.

Variococele.

Elastic tumours of the groin or axilla, Helminthoma elastica.

Lymph vesicles bursting on the scrotum, abdomen, or by discharging chylous fluid.

Crow-crow, a similar condition of the arm mentioned by investigators in Brazil.

Orchitis, acute.

Lymphangitis of upper or lower extremities, with shivers and heats like ague, called elephantoid fever.

Erysipelatous lymphangitis, leading to hypertrophy of skin, the beginning of—

Scrotal tumour and elephantine leg.

Contraction of lymphatic trunks, with neuralgic pains (Case 9).

Abscess of scrotum, of the glands of the neck, like scrofula; of the lymphatics of the upper arm or thigh, and intra-pelvic abscess.

Peculiar steatoma of face.

Venous varix of upper arm (Case 4).
Cerebral abscess, and other lesions of the brain.

A few remarks on examination of the blood; medical treatment of cases and preventative measures.

I prick blood generally from the part the patient complains of. If it does not flow freely the syringe, called the artificial leech, is convenient. A small scrotal vein yields plenty of blood, so does the skin of the face. Elastic tumours can be punctured, avoiding large vessels.

If blood to the extent of a teaspoonful is mixed in two ounces of water and let stand in a conical glass for some hours or overnight, the contained filariæ will twist and twirl themselves to the bottom, and may be sucked up in great numbers by pipette.

Blood or fluid suspected to contain filariæ should be put on a glass slide and smeared somewhat level. Under the 2-inch object-glasses made by Beck, using at the same time the highly magnifying eyepieces, filariæ can be easily recognised (see Woodcut 19).

WOODCUT 19.

Filaria under the ¼-inch objective.

If the atmosphere be not too dry, this will be found a readier way than using cover glasses. Small homœopathic bottles are convenient to carry blood. Filariæ become much less active when placed in water.

Medical and surgical treatment.

With regard to chyluria, some tonic treatment is required, as the loss to the system is great, and patients get weak and bloodless. The appetite is generally good, sometimes greatly in excess of natural. Acid iron mixtures are useful. If some method could be employed by which the discharge of chyle could be stopped, much good would be done. Lying in a particular position determines discharge of chyle in some cases.

I suppose gravity tends to open a lymph vesicle which has formed on the mucous surface of the bladder. One case of troublesome hæmaturia happened to me several years ago in a male patient of about forty years of age. The disease arose without any known cause. After trying all the internal remedies generally used, I injected weak lead solution by a double catheter. This in a few days quite cured the patient. He might have been a filarious case, but at that time I knew nothing of the subject. Injections of an astringent kind seem worth a trial in chyluria.

When tapping hydroceles in filarious patients it would be worth trial to use a large canula, injecting the sac afterwards full of water. Adult filariæ under these circumstances would become passive, and might escape in the stream of water.

I have extirpated one large elastic tumour, which ended in recovery after severe illness: abscesses of shoulder, arm, and pelvis. No filariæ were found after recovery.

In cases where the resting place of adult filariæ could approximatively be determined, electricity might be applied, either by needles or otherwise. This, one might hope, would by diligent application during a lengthened period lead to death of the parasites. Abscesses would then probably form.

I have given nearly all the poisons to my cases of chyluria without in any way injuring the activity of the microscopic filariæ or reducing their numbers.

Preventive measures.

For several years I have cautioned the public in Queensland against drinking the surface waters without boiling. Tea drinking is very general in Australia, and I have always encouraged colonists to imitate the Chinese custom of boiling drinking water, even if no tea were attainable.

Now that Dr. Manson, of Amoy, has shown that the mosquito carries microscopic filariæ, the necessity of such precaution is confirmed. *May* 21*st*, 1878.

Cases of Filarious Disease

No.	Sex.	Age.	Occupation.	Chyluria.	Hæmaturia.	Orchitis, Hydrocele, &c.	Elastic Tumour.
1	M.	17	Coachman	Chyluria	Slight	Orchitis	...
2	F.	11	School-girl	"	At times abundant	...	...
3	M.	16	Leather-worker.	"	"	...	...
4	F.	23	Laundress	"	...	...	...
5	F.	20?	Housewife	"	Hæmaturia	...	...
6	M.	16	Saddler	"	"	...	...
7	F.	19	Domestic servant	"	...	...	...
8	M.	18	Clerk	...	...	...	...
9	M.	18	Butcher	...	...	...	...
10	M.	28?	Butcher	...	...	...	...
11	M.	25?	"	...	...	Orchitis	...
12	F.	27	Housewife	Chyluria	...	...	...
13	M.	45	Drayman	...	...	...	...
14	M.	19	Blacksmith	...	...	Orchitis	Elastic tumour
15	M.	30	Roadman	...	Hæmaturia	...	...
16	M.	26	Clerk	...	...	Chylous hydrocele	...
17	F.	23	Housewife	...	...	...	...
18	M.	18	Ironfounder	...	...	Varicocele	...
19	F.	20	Housewife	Chyluria	...	...	...
20	M.	22	Overlooker	...	...	...	...
21	M.	30	Collector	...	...	Orchitis and hydrocele	...
22	M.	17	Bricklayer	...	...	...	...
23	M.	14	Plumber	...	...	Hydrocele	Elastic tumour
24	M.	19	Groom	...	...	...	...
25	M.	20	Tin-worker	...	...	...	Of axilla
26	M.	50	Carpenter	...	...	Hydrocele	...
27	F.	22	Housewife	Chyluria	Hæmaturia	...	...
28	M.	18	Groom	...	...	Commencing Elephantiasis scroti	Of groins
29	M.	17	Stockman	...	...	Orchitis	"
30	F.	18	Domestic	Chyluria	...	...	...
31	M.	11	School-boy	...	...	...	Right groin

collected in Queensland.

Inflammation of Lymphatics.	Febrile Attacks; Elephantoid Fever.	Abscess.	Steatoma.	Filariæ.
...	...	Of scrotum	...	Sought for late, not found.
...	...	...	...	Filariæ abundant.
...	...	...	...	"
Of arm	...	Pelvic	...	...
...	...	...	...	Not found.
Of arm	Febrile attacks	Of arm	...	Filariæ found.
...	...	...	...	"
...	...	...	Of ear	"
Of arm	Febrile attacks	Of arm	...	Adult filaria, with microscopic progeny.
"	"	"	...	Filariæ found.
...	"	...	...	"
...	...	...	...	Not found.
Of arm	Febrile attacks	Of arm	...	Filariæ found.
"	"	"	...	"
...	...	...	...	"
...	...	...	...	"
Of arm	Febrile attacks	Of arm	...	"
Of thigh	"	...	...	"
...	...	...	...	Not found.
Of arm	Febrile attacks	Of arm and pelvis	..	Filariæ found.
...	...	...	...	"
Of leg and neck	Febrile attacks	Of neck	...	"
...	...	...	Of face	"
...	...	...	"	"
...	Febrile attack	Of arm and pelvis	...	"
...	...	...	...	Form adult and microscopic.
...	...	...	...	Filariæ found.
...	...	...	...	"
...	Febrile attacks	...	...	"
...	...	...	...	"
...	...	...	...	"

(B) ON SPLENIC FEVER.

21. *Life-history of Bacillus anthracis.*

By J. Cossar Ewart, M.B.

THE preparations show the phases through which *Bacillus anthracis* passes both in artificial and in natural conditions. In animals suffering from splenic fever set up by introducing a few spores of *Bacillus anthracis* into the subcutaneous tissue, numerous Bacilli in process of division are found in the blood and serous fluids in twenty to forty-eight hours after inoculation; and at death countless numbers of similar rods exist in the greatly enlarged spleen.

Death according to some investigators results from the oxygen of the blood being used up by the rapidly increasing Bacilli. By others it is said to be due to the mechanical obstruction resulting from the Bacilli filling up the small vessels and capillaries. My investigations lead me to believe that death more likely results from the by-products formed during the growth of the Bacilli acting as a virus which probably paralyses the respiratory centres.

The Bacilli when cultivated on the warm stage may first—though rarely, become motile and then lengthen into very long filaments which form a mycelium, their protoplasm rapidly condensing into bright oval spores. The spores on escaping from the filaments may either at once germinate into another generation of Bacilli or divide into sporules, which when provided with sufficient nourishment also develop into Bacilli—the Bacilli formed from the sporules being at first slightly smaller than those developed from the spores. The motile phase, the mode of condensation of the protoplasm into spores, the formation of the young Bacilli from the central protoplasmic substance rather than from the gelatinous looking envelope of the spore and several other points mentioned in a paper on *Bacillus anthracis* ('Quarterly Journal of Microscopical Science,' April, 1878) have not been before noticed either by Dr. Koch or by any of the others who have been recently studying the life-history of this now familiar organism. *February 5th*, 1878.

(c) ON MEASLES.

22. *Researches on measles (morbilli).*

By P. M. Braidwood, M.D., and F. Vacher.

(Introduced by the President.)

The prevalence of measles during some months past led us to study some of the characters distinctive of its contagium. The cultivation of measles in the lower animals was, however, not attempted, seeing that they are not known to be affected by any analogous disease. Our observations consist in the microscopical examination of the breath, the skin, lung, and other tissues of patients suffering from measles, or who have died from it. Particulars of some earlier researches of this nature are recorded in the article on measles in Ziemssen's 'Cyclopædia of the Practice of Medicine,' vol. ii, 1875.

It is there stated that Hallier found in the sputa and blood of measles patients large numbers of free cocci, most of them having a tail-like end, and being moveable, colourless, smaller than those of typhus, and which he succeeded in cultivating on various substances; but Vogel denies these observations. Salisbury ascribed measles to a fungus-spore found on decaying straw, and by inoculation therewith, produced an exanthem bearing a close resemblance to measles; while Pepper, on repeating such inoculations, obtained no results. Coze and Feltz found in the blood of measles patients numerous bacteria of great activity and extreme delicacy. They found, also, numerous similar elements in the nasal mucus of such patients. G. Simon (1848) examined a "papule cut, together with a small portion of the subjacent cutis," from a boy with measles. "It appeared that the epidermis was unaltered, and not separated from the cutis; this latter bulged somewhat at the site of the papule; why, was not ascertained. Abnormal elements were not present, with the exception of very small roundish molecules, unaffected by acetic acid, between the cutis fibres; these, themselves, showed no change, the papillæ were not enlarged, and it was presumed therefore that the papule resulted merely from a collection of fluid. On the upper portion of the hair-sac no change was found, nor any swelling of the sebaceous glands." ('Ziemssen's Cyclopædia,' vol. ii, p. 63.)

Dr. Ransome, of Manchester, more recently, as appears in a paper 'On the Organic Matter of Human Breath,' published in the 'Transactions of the Lit. and Philosoph. Soc. of Manchester, 1869,' and in the 'Journ. of Anatomy and Physiology,' May, 1870, observed bodies probably similar to those we shall hereafter describe in the aqueous vapour of the breath of two cases of measles.

Having long felt convinced that the most active mode of transmission of the morbillous contagium is through the breath, the characteristic cough of the disease being its most potent propagator, it occurred to us to examine microscopically the breath of patients afflicted with measles. The correctness of these observations was tested by examining in like manner the breath of healthy children, and more recently the breaths of patients suffering from scarlatina and from typhus. The following interesting results were thus reached. Whereas glycerine, on which a healthy child respired, showed only molecules, that on which a patient suffering from measles, during any of the eruptive days, breathed, exhibited numerous spherical sparkling bodies like those found in vaccine but larger, and others elongated, with sharp-cut ends, sparkling and colourless. These bodies are to be seen in greatest abundance during the first and second days of the eruptive period. They are, moreover, not detectable in the breath of patients suffering from scarlatina and from typhus.

In the next place, death from measles being a comparatively rare occurrence, when this exanthem does prove fatal this is due to some complication, to excessive pneumonia, to great debility, or to neglect rendering one or other complication deadly. We have, accordingly, been able to examine the tissues of the victims of measles in two instances only. One of these patients died on the eighth day after the appearance of the eruption, the other died at a stage of the disease about one week later. These children, during life, presented no abnormal symptoms, but were weak and badly nourished. In each instance we made a *post-mortem* examination within twenty-four hours after death, portions of the skin (on which the eruption during life had been well marked) were removed along with portions of each of the viscera, and were placed at once in strong alcohol, and when hardened were sent to Messrs. Cole and Son for section-cutting. The slides thus obtained, several dozens in number, were examined microscopically with great care and repeatedly by us with the following results:

Case of M. D—, who died on the eighth day after the appearance of the measles eruption. The *skin* under a low power showed considerable swelling of the corium with thickening of the rete Malpighii and deep tinging of the hair follicles, sweat ducts and glands, and lymphatics. The sweat glands were larger than usual.

Under a high power there was seen great proliferation of the cells of the rete Malpighii, extending along the hairs and along the sweat ducts into their glands. In the portion of the true skin below the rete Mucosum and in immediate proximity to the sudoriparous ducts and lymph spaces, were to be seen in groups or scattered, sparkling, spherical bodies; also sparkling, spindle-shaped, staff-shaped, or canoe-shaped bodies, which did not take the carmine tinge. These were probably the germs and organisms with which the contagium of measles is intimately associated. The germs or spherical bodies resemble the so-called micrococci of vaccine; like them they incline to form groups of two or three or four, but they seem to be somewhat larger in size. These peculiar bodies are not to be seen in the sweat glands, ducts, in the hair follicles, or in the lymph channels. They are not traceable deeper in the true skin than the level of the sudoriparous glands.

Lung under a low power showed infiltration of its tissue causing obliteration of the air vesicles for the most part, while here and there two or more of the air vesicles seem to have broken into one another. The bronchial tubes showed exudation on their lining membrane.

Under a high power the infiltration was seen to consist of blood globules altered greatly and accompanied by an excessive proliferation of cells. Some of the air vesicles were filled with granular amorphous exudation. Here and there were to be seen, on careful examination, numbers of sparkling, spherical bodies having a dark smooth outline, and which do not readily take the carmine tinge. Near these were generally to be found sparkling elongated bodies, some staff-shaped, others fusiform or ovate, slightly tinged with carmine, and appearing as dark rods or as minute fusiform cells with granular contents. These peculiar bodies can, with attention, be readily distinguished from the various forms seen in this tissue.

Liver.—Under a low power its lobules were imperfectly defined. The hepatic tissue on the whole appeared healthy. Under a high power (× 300) it showed scattered around the bile ducts sparkling staff-shaped bodies; also fusiform bodies with granular contents.

The kidney, spleen, and mesenteric glands, examined microscopically, revealed nothing distinctive.

Case of E. M—, who died on the fourteenth day of the disease.

Skin.—Under a low power showed some thickening of the rete Malpighii, hair follicles, sweat ducts and glands, but this swelling was less manifest than in the former instance. With a high power the proliferation of cells causing the deep tinging of these tissues was noticed to be less marked than in the previous case. Here, also, were to be seen very distinctly the contagium particles described before. They presented the same characters and occupied the same position as those noted before.

Lung.—A low power revealed pneumonic infiltration, causing considerable obliteration of the air vesicles, accompanied by bronchial catarrh. Under a high power (× 300) this infiltration was observed to consist for the most part of the same elements as in the last case. Specific organisms, presenting the same characters as those noticed in the last patient, were seen scattered through this tissue. As in the former instance, these peculiar bodies were readily distinguished by careful study from the various other forms to be seen in this lung tissue.

Liver.—Showed under a low power, its lobules ill-defined and its substance granular-looking, with fat-cells interspersed. Under a high power it appeared cloudy, and the tubules were distinguished with difficulty. Some fat globules were to be seen clustered here and there. For the most part, in the immediate neighbourhood of vascular channels, but occasionally where there was no evidence of blood-vessels, were to be observed the same varieties of spherical and elongated contagium particles as were detected in the lung tissue. In some instances, where the capillaries were distinctly seen, none of these bodies were discernable, while at other spots groups of these contagium particles were found, and no trace of vascular channels. It is to be noted that these bodies occur most frequently in the tissue immediately outside the walls of the vascular spaces.

Spleen.—With a low power its substance appeared very friable and broken down, while the walls of the Malpighian corpuscles seemed thickened. A high power showed the splenic capsule to be thickened and infiltrated with blood, while the tissue itself presented no distinctive characters, but appeared as a granular and corpuscular mass, with here and there yellowish hæmorrhagic patches scattered through it.

Kidney.—With neither a high nor low power could anything distinctive be made out in the renal tissue.

These observations will, we trust, lead to the recognition of an additional species of contagium particle, a *measles protoplast* to be ranked side by side with the *vaccine protoplast* (recognised by all), and with probably a specific scarlatinal variety. Our observations further draw attention to the probability of the lungs being the principal seats of development for the measles contagium, thus rendering the cough accompanying this exanthem an important means of communicating the disease and pointing to the earliest stage of measles as probably the time when it is most infective. That the contagium particles we have described are probably albuminoid in nature (like vaccine particles) and of protoplasmic character, is rendered probable by their taking the carmine tinge imperfectly as in lung tissue, or not at all, as in skin and in the breath, and by their varying in form when subjected to compression. As a rule elongated and staff-shaped, when apparently squeezed between elements of the tissues, they are seen crescent-shaped or irregularly spindle-formed. These sparkling bodies are probably intimately associated with the contagiousness of measles, in as much as they are to be found in the breath and in certain tissues of patients suffering from, or who have died from, this disease, whereas they are not recognisable in the breath and tissues of those who suffer from, or have succumbed to, some other febrile diseases.

May 7th, 1878.

(D) ON LACTIC FERMENTATION.

23. *On the lactic fermentation, and its bearings on pathology.*[1]

By JOSEPH LISTER, F.R.S.

A FEW years ago it would have seemed very improbable that the souring of milk should have any bearings upon human

[1] This communication, made to the Society without manuscript, December 18th, 1877, is here given in its original form. In preparing it for the press, however, matter has been introduced, including some points into which the time at my disposal did not allow me to enter, and also some facts since ascertained, together with considerations arising from them.

disease; but all will now be ready to admit that the study of fermentative changes deservedly occupies a prominent place in the minds of pathologists.

In order that any sure steps may be taken to elucidate the real nature of the various important diseases which may be presumed to be of a fermentative nature, such as the specific fevers or pyæmia, the first essential, as it appears to me, is that we should have clear ideas, based upon positive knowledge, with regard to the more simple forms of fermentation, if I may so speak—more simple because they can be conducted and investigated in our laboratories.

It may be said, indeed, that such information has been already afforded us by the researches of Pasteur and others who have followed in his wake, tending to prove that all true fermentations of organic liquids are due to the development of organisms within them; and I confess that for my own part I am disposed to agree with that view. But this opinion is by no means universal in our profession. We meet with statements by men of very high position, both as physiologists and pathologists, to the effect that in various fermentations—such, for example, as putrefaction—the bacteria which are found to be present may, for aught we know, be mere accidental concomitants, not causes, of the fermentative change. And such being the case, it seemed desirable to obtain, if possible, entirely conclusive evidence upon the subject.

About four months ago I made an attempt of this kind with regard to the lactic fermentation; and I propose on the present occasion to bring forward the results arrived at, and at the same time to afford the members of the Pathological Society an opportunity of seeing with their own eyes samples of the preparations which resulted from that inquiry, and on which my conclusions are based.

First, however, I desire to describe my method of experimenting, which, in its present simplified form, has never been published. It is based, in the first instance, on the fact which experience has now amply demonstrated, that if we have a vessel like this liqueur glass (A) in a state of purity, covered with a pure glass cap (B), the capped liqueur glass being further covered with a glass shade (C), and standing as a matter of convenience on a plate of glass (D), any organic liquid contained in the liqueur glass, provided it be free from living organisms at the outset, will remain without any organic development occurring in it as long as the arrangement of the glasses is left undisturbed. Or, in other words, although an interchange is con-

stantly taking place between the gases of the atmosphere and those in the liqueur glass—for the cap does not fit at all, and the shade is not air-tight—yet the double protection of the glass cap and the

WOODCUT 20.

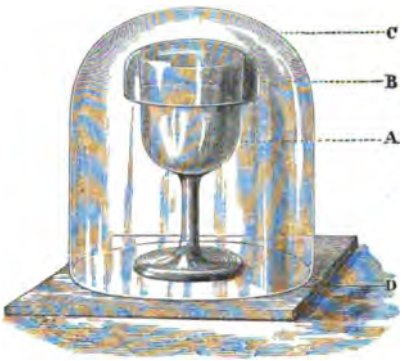

glass shade effectually prevents access of the atmospheric dust to the liquid; and if the dust is excluded, organisms do not occur in it.[1]

The glasses are obtained pure by means of heat. I find that exposure to a temperature of 300° Fahr. for two hours is sufficient to deprive all living material of its vitality. But it is not enough that the glasses should be so heated; it is necessary that the air which enters them during cooling should be filtered of its dust. This I secure by heating them in a cast-iron box, the door of which (E) is here

[1] A curious exception to this general truth was met with by Mr. Godlee in the course of his experiments made by this method upon the vaccine virus, recorded in the 'Transactions of the Pathological Society,' vol. xxviii. He found that *Penicillium glaucum* made its appearance in some of his glasses in a way that seemed unaccountable, till he discovered that the cupboard in which the vessels were kept was infested with acari, and that these creatures crawled up and into the glasses. He further found, on examining some of these acari under the microscope, that spores of the Penicillium were to be seen actually adhering to their hairs. The wonder now came to be, not that that fungus should have entered the glasses, but that other organisms, such as bacteria, should not have been also carried in. If there were any reason to apprehend the intrusion of such creatures, they might no doubt be easily excluded by placing each glass plate in an ordinary dinner-plate containing glycerine, so as to surround the glass plate on all sides with the viscid liquid.

shown. This door has its circumferential part in the form of a groove, capable of being packed with a considerable mass of cotton-wool (F). The door can be screwed by means of nuts (G, woodcut 22) against

WOODCUT 21.



the edge of the box (represented by dotted lines in the sketch); and the cotton-wool, having the narrow rim of metal thus firmly pressed against it, serves as an effectual filter of the air that passes in during cooling. But then it is essential that the heat be so equably distributed as to avoid heating any portion of the cotton to such a degree as to destroy its physical properties. The cotton-wool which you now see in the lid has been used for several experiments; yet you observe it is only slightly browned; it is not singed at any part, as it would have been unless the heat had been nearly uniform. This uniformity of the heat is provided for by having three shelves of sheet iron (H H H) interposed between the large Bunsen's burner (I) and the bottom of the box, so as to prevent the heat from acting directly upon it; while at the same time the box is covered over with a cover of sheet iron (KK), which reaches nearly to the ground, and, while it checks radiation, compels the heated air to travel over the whole exterior of the box and escape by holes at the top of the cover, whence it is conducted into a chimney by the tube (L). By these two means combined, the shelves below and the cover round about, we get the result which you see here. The cotton at the top of the box is browned to just the same degree as that at the bottom. Into such a box (about one foot in its three dimensions and furnished with a shelf in the middle) we may put a dozen sets of covered glasses such as I have

described, together with their glass plates and shades. An aperture in the top of the box, well packed with cotton-wool, transmits the thermometer (M) to show when the temperature of 300° has been attained; and when this or any higher degree short of about 350°

WOODCUT 22.

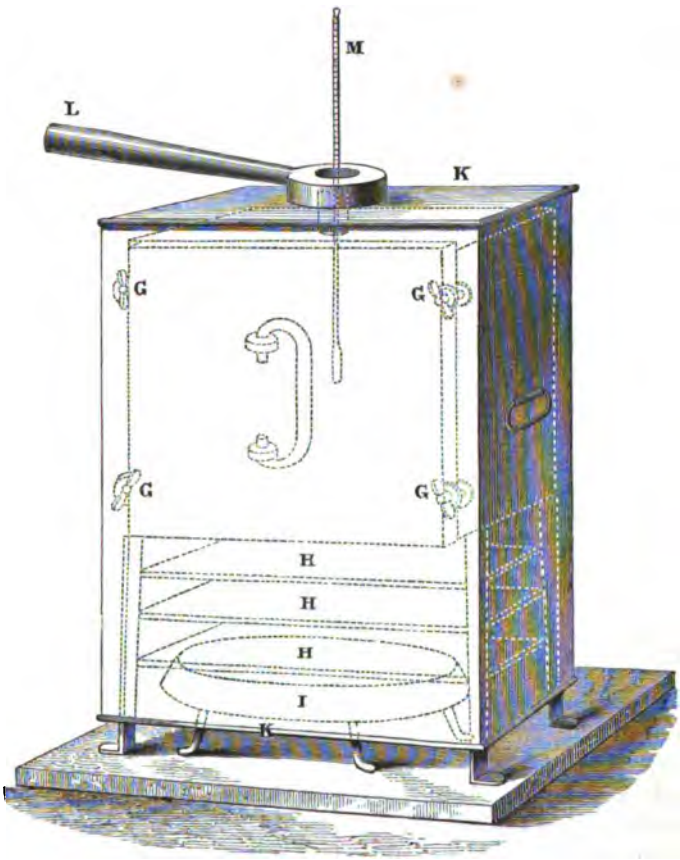

has been continued for two hours, the gas is turned off and cooling is allowed to take place; and when the apparatus is quite cool, the covered glasses may be removed with confidence that they are perfectly free from living organisms.

In the next place, how shall any pure organic liquid be introduced

into one of these purified liqueur glasses without risk of contamination? This we are now able to manage in a comparatively simple manner. The liquid is introduced by means of a flask of this form (N), having a bent spout, large at the commencement and comparatively narrow in its shorter terminal part (O) beyond the bend. The large size of the first part of the spout prevents it from ever acting like a syphon; and the result is that, when liquid is poured from such a flask and the vessel is afterwards restored to the erect

WOODCUT 23.

position, the end of the nozzle remains valved by a drop of the liquid; and this guards the orifice, so that regurgitation of air can never take place through the nozzle. And the mouth of the flask being covered with pure cotton-wool (P), the air that enters the flask during the pouring out of the liquid is filtered of its dust by passing through the cotton. When the decantation is completed, a piece of rag wrung out of a strong watery solution of carbolic acid (1 to 20) is applied to the orifice of the nozzle, and, by capillary attraction, sucks out the drop; after which a cap of carbolised cotton-wool (Z in woodcut 25, page 436) is tied securely over the nozzle, the liga-

ture obtaining a purchase upon the projection (O) upon the tube.[1] When this has been done, the liquid, if it was pure to start with, and the flask also pure, will remain ready to be used again in a pure condition a month or even a year later if required.

Now as to the means of preventing the entrance of dust into the liqueur glass while it is being thus charged. Suppose I were going to charge this glass (Q) from this flask (the spout of which is alone given in Woodcut 24), containing Pasteur's solution introduced on the 7th of August, yet you observe, remaining as pure and clear as when it was first prepared, although it has served for charging various

WOODCUT 24.

liqueur glasses. I should remove the cotton cap from the nozzle, and instantly slip the end of the nozzle into the opening which exists in the centre of this half of a substantial india-rubber ball (R),

[1] Cotton-wool intended for a cap to cover the mouth or nozzle of a flask is conveniently applied between two pieces of open muslin, which ensure that the cotton shall remain as a uniform layer, and also permit it to be readily removed without leaving any of the cotton adhering to the glass. The best material for the ligature I have found to be very fine iron-wire, tied firmly in a half knot, which is secured by giving the ends of the wire a bend, so as to convert them into hooks. A good mode of carbolising the cotton-wool is to treat it with a solution of 1 part of carbolic acid in 100 parts of anhydrous sulphuric æther. The cotton greedily imbibes the liquid into all its parts and the æther evaporating leaves the carbolic acid behind in the cotton, which is thus rendered highly pungent and antiseptic.

previously steeped in a strong watery solution of carbolic acid. The caoutchouc absorbs carbolic acid into its substance, so that, even though dry after such steeping, it is powerfully antiseptic. I then remove the shade and take off the glass cap, and immediately substitute the cap of india rubber on the nozzle of the flask (as shown in the sketch). Fluid is now poured in, the flexible caoutchouc acting as a hinge during the movements of the flask, while the antiseptic cap excludes all living organisms; and the instant the flask is withdrawn the glass cap is replaced and the shade put on. The hemispherical form of the cap also prevents lateral currents of air from depositing dust on the drop at the nozzle while it is being moved from one glass to another, and a second, a third, or a dozen glasses may be thus charged in succession; and experience shows that this mode of procedure is so secure that the liquid will remain uncontaminated in such a series of vessels until it dries up through atmospheric influence.

The last point is, How do we get the flask in a pure state with a pure liquid in it? The flask itself is purified together with its caps of cotton-wool over the mouth and nozzle by being heated in the hot box. And here we have another great advantage arising from the uniform temperature of the box sufficient to purify cotton without impairing its physical properties. We have, therefore, a simple means of securing a pure flask to begin with.

Next, we wish to introduce into it a pure liquid. There is one organic fluid, peculiarly adapted for experiments on this subject, which can be got in the pure state with very little difficulty, and that is unboiled urine, provided we have a healthy urethra to deal with and a healthy bladder. All we have to do is to wash the surface of the glans penis thoroughly with a watery solution of carbolic acid, 1 to 40, in which strength it may be applied to the lips of the meatus urinarius without causing inconvenient smarting, and having thus merely purified the external integument, remove the cotton cap from the orifice of the flask and at once apply it to the organ and direct the patient to micturate. The purified glans takes the place of the caoutchouc cap, and as the urine enters no regurgitation of air is possible. As soon as the act of micturition is completed, a freshly carbolised cotton cap is tied over the mouth of the flask, and as surely as this process is properly performed, will you have the unboiled urine, together with its vesical mucus (which used to be regarded as the special ferment of urine), remain for any length of

time free from development of bacteria or any other organism, and that whether the urine be acid or neutral in reaction.[1]

But suppose we have to deal with a liquid contaminated with organisms, like milk obtained from a dairy, we must purify it by heat. For this purpose I have always found exposure for an hour to a temperature of about 210° Fahr. sufficient.[2]

I say 210°, not 212° which is the boiling point of water, because the way in which we have proceeded is, after introducing the liquid into the purified flask, to immerse the vessel, to a higher level than that of the contained liquid, in boiling water: and, in consequence of a certain degree of evaporation which takes place through the cotton caps which cover the mouth and nozzle of the flask, the temperature of the liquid is prevented from ever rising fully to the boiling point. We thus avoid the occurrence of ebullition; and this is a very great advantage, as we get rid of frothing; and, as already stated, the temperature which is attained proves adequate for the destruction of organisms in the liquid. All we have to do then, supposing the interior of the flask perfectly pure, is to introduce the liquid into the lower part of the flask with a view to immersion

[1] For further details on this subject, see 'Transactions of the Royal Society of Edinburgh,' 1875, vol. xxvii, pp. 315 et seq.

[2] In making this statement I proceeded upon a pretty extensive experience with various liquids, such as water, Pasteur's solution, and turnip infusion, as well as milk. In my experiments with the last-named liquid, I had obtained it fresh from the cow milked directly into a glass vessel purified with carbolic lotion and then rinsed with water, and having filtered it through a fine cloth, exposed it to heat with as little delay as possible. But between the time of the meeting of the Society and that of going to press, I have found that milk which has been kept for some hours cannot be purified so easily. This I am inclined to attribute to the fact that milk, unlike the other liquids referred to, is a heterogeneous fluid containing oily particles in suspension, which tend as time passes to aggregate and coalesce. And it is quite conceivable that bacteria enclosed in such oily masses may be protected by them from the action of the hot watery liquid, the drops of butter acting as small portions of cheese have been found to do by some other observers. For it is a well established fact that bacteria withstand a much higher temperature in the dry state than when acted on directly by hot water. I have also seen reason to believe that large numbers of bacteria grouped in masses are more resisting to the action of heat than isolated bacteria, as if the circumferential members of such a mass protected the central ones, and this circumference may perhaps aid in explaining the point in question. Again, if we consider the adventitious particles introduced in the form of dirt from the milkman's hands, &c., we cannot be surprised that difficulty should be experienced even with fresh milk, unless special precautions are taken to promote cleanliness.

in a saucepan of boiling water: but then the most scrupulous care must be taken that no portion of the liquid so introduced shall come into contact with the upper parts of the interior of the flask; for any particles deposited there would fail to be acted on by the full heat of the water in the saucepan. Now the mode in which I filled the flasks in my earlier experiments was this. Having provided myself with a rag soaked with a strong solution of carbolic acid (1 to 20), I washed with it the exterior of a long funnel, and, wrapping the rag round the lower end of the funnel in sufficient mass to cover the mouth of the flask, I substituted the mass of antiseptic material for the cotton cap with which the mouth was previously covered, pushed down the funnel through the rag, poured in the liquid and withdrew the funnel, taking good care that the drop at its extremity did not touch the interior of the flask. A freshly prepared carbolised cotton cap was then applied to the mouth of the flask at the moment of withdrawal of the antiseptic rag, and the flask was immersed in the saucepan.[1]

If I proceeded in this way with Pasteur's solution or with turnip infusion, I always had success; but when I did the same thing with milk, time after time, to my great disappointment, I failed altogether. What was the explanation of the failure? Some persons might have said, "Oh! the explanation is very easy to find. There are in milk complex organic molecules which, though as yet mere chemical substances, are, we imagine, ready to develop into living beings, and it is this complex constitution of the milk that makes you fail; whereas, your Pasteur's solution is a comparatively simple material, and turnip infusion may, for aught you know, have its molecules more simply constituted than milk." I felt sure that this was not the true explanation, but that there must have been some defect in my method of procedure. It may perhaps have occurred to some of you what that defect was: it was this, that if we pour any liquid through a funnel, we invariably have air pass

[1] Means must be taken to prevent the flask from being floated up by the water in which it is immersed. This I have done by tying the flask into a vessel, such as a soap dish, containing shot. The flask so weighted is placed in the empty saucepan, warm water is poured in to a level considerably above that of the liquid in the flask, and brought to boil as quickly as possible and kept simmering for an hour. A piece of thin Mackintosh cloth, cut so as to adapt itself to the flask and cover the top of the saucepan, has the double advantage of preventing the water from boiling quickly away and avoiding moistening of the cotton about the flask by drops of condensed vapour.

along with it. Air bubbles consequently formed upon the surface of the liquid, and those bubbles bursting dispersed their dust in the air within the flask; so that it might well happen that such particles, including perhaps some atmospheric organisms, might be deposited upon the upper part of the vessel, and so fail to be destroyed when the liquid was heated. But why should success be more likely with Pasteur's solution than with milk? Simply for this reason, that milk is a material which serves as a pabulum for almost all organisms. I once met with a bacterium, but only once, that would not live in milk; for extremely numerous as the varieties of bacteria appear to be, almost all of them seem to thrive in that liquid, whereas it is a common thing to find bacteria which, if put alive into Pasteur's solution, will not grow in it at all. The defect in our method having been discovered, there was no great difficulty in correcting it. It was done by substituting for the funnel this syphon (see Woodcut 25), consisting of two glass tubes (S. and T.) connected by a tube of india rubber (U), with a stopcock (V.) in the course of the caoutchouc tubing. The syphon is first completely filled with water, the temperature of which should be higher than that of the air, so that there may be no dissolved air given off to form bubbles. Then suppose this (W) to be the fluid that we wish to introduce into the flask (X). We pass one leg of the syphon into it; then turn the tap and permit a sufficient amount of fluid to flow out to ensure that all the water has escaped from the syphon; then turn off the stopcock and proceed in the manner already described for the funnel. The tube (T) having been washed with strong carbolic lotion, carbolised rag is wrapped round its lower extremity, and this is applied to the mouth of the flask as the cotton cap is removed; the tube (T) is pushed steadily down to the bottom of the flask through the carbolised rag (Y), the stopcock is turned on and the liquid passes into the flask without the smallest air bubble accompanying it. When a sufficient quantity has been introduced, the tap is again turned off, and the syphon is withdrawn through the antiseptic rag, and a fresh cap of carbolised cotton is tied over the mouth of the flask when the rag is withdrawn.

I have said that before I saw my mistake in using the funnel, I never succeeded with milk. Since I have adopted the syphon I have charged many flasks and never failed. Here is a flask of boiled milk (or rather of milk that has been exposed to a temperature of 210°) prepared on the 7th of August, and remaining we may safely say

as pure as it was then. You observe it is still perfectly liquid and unaltered in appearance. Now I venture to remark that this failure and correction of the failure are extremely instructive, as showing

WOODCUT 25.

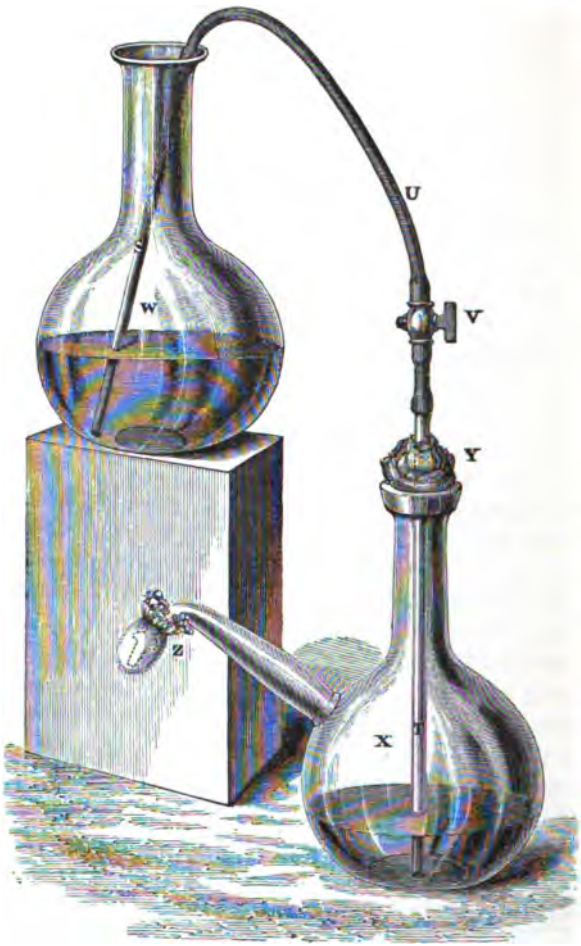

how the development of organisms under circumstances in which we cannot at first explain their occurrence may be really due to fault on our part, defect in our own manipulation.

So much for our method of procedure. I will now go on with the main subject of this communication. I selected the

lactic fermentation as one peculiarly favourable for investigation: first, because the effects which it produces in milk are extremely striking and readily recognised—the solidification which takes place being obvious at a glance, and the souring as shown by test paper being also a very conspicuous change; and in the second place because the ferment which occasions these alterations is, in ordinary localities, a very rare ferment; and if it be rare, it is not likely that any defects in our manipulations will lead to its accidental introduction.

It may seem strange that the ferment that leads to the souring of milk should be rare, but such is the fact; in dairies it appears to be universal, but in the world at large it is scarce. If you charge a series of pure liqueur glasses with boiled milk and take off their caps so as to expose them to the air for about half an hour each, doing this for the various glasses at different times of the day or in different rooms, you will be sure to have organisms develop in all of them, of the nature of filamentous fungi and bacteria; and you will see fermentative changes ensue; but, so far as my experience goes, you will not see the coagulation and souring of the lactic fermentation, nor will you find under the microscope the peculiar organism to which I have given the name of *Bacterium lactis*, which is represented here (Plate XX, fig. 9) as it occurs in ordinary curdled milk, and which may be seen under one of the microscopes on the table, in milk taken from the cow yesterday.

This organism is a motionless bacterium, that is to say, exhibiting no movement except a slight jogging, occurring most commonly in pairs, but frequently in chains of three, four, or more individuals, each segment being of somewhat rounded form, more or less oval, with the long diameter in the direction of the length of the chain, and often showing, on careful focusing, a line across their central part indicating transverse segmentation. They vary in diameter as I shall have occasion to notice again, full-sized specimens measuring about $\frac{1}{20000}$ inch.[1] You always find them, as far as I know, in souring milk from a dairy, and a touch with the point of a needle which has been dipped into such souring milk will induce their development with great rapidity in a glass of boiled milk, together with the characteristic curdling and souring, showing that the boiled milk

[1] In giving these as the characters of the *Bacterium lactis*, I do not wish to be understood as stating that this species can always be certainly recognised by its morphological features alone.

is thoroughly disposed to the lactic fermentation as soon as the appropriate ferment enters, while that ferment, as already stated, is not likely to occur as the result of exposure to the air of your study or any ordinary situation.

These little glasses (represented on a reduced scale in Woodcut 26) illustrate the same point as regards unboiled milk. Each is a small test-tube provided with a cap made of the bottom of a larger test-tube, and arranged along with five others in a stand made of pieces of glass tubing and stout silver wire, and placed under a common glass shade on a plate of glass.

WOODCUT 26.

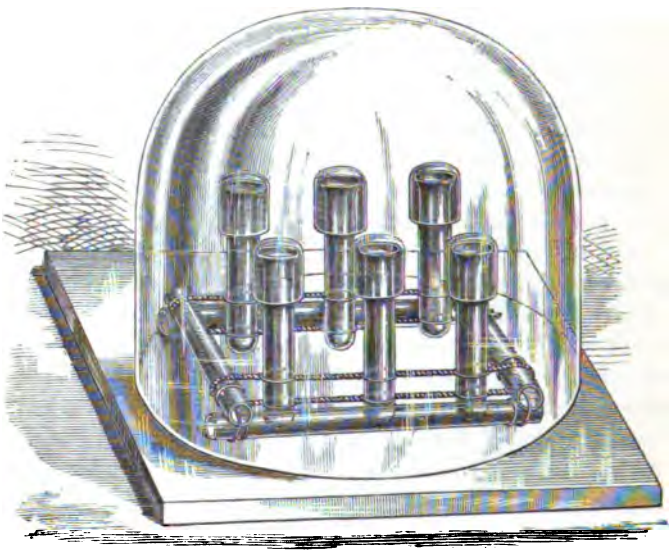

Four such sets of glasses, making twenty-four glasses in all, were purified by heat in the hot box, together with their plates and shades. Another larger glass, provided with a glass cap, having been also purified by heat in the box, milk was drawn directly into it from a cow standing in a little orchard belonging to a dairy farm and within two yards of the dairy itself, the glass cap being removed immediately before the milking commenced, and re-applied as soon as the vessel was charged, the quantity amounting to about two ounces. Then by means of a syringe connected with a purified pipette the milk was at once trans-

DESCRIPTION OF PLATE XX.

The figures in this Plate illustrate Mr. Lister's paper on the Lactic Fermentation in its Relations to Pathology.

Figs. 1 to 8 represent of natural size certain glasses of unboiled milk described in the text. They are examples of the alterations in appearance produced in milk by various different organisms other than the *Bacterium lactis*. From sketches taken October 1st, 1877.

Figs. 9 to 12, Camera Lucida sketches, by Mr. Lister, of *Bacterium lactis* and *Torula cerevisiæ* on the same scale, viz. magnified 1125 diameters.

For further description, see the plate and the text.

BACTERIUM LACTIS			TORULA CEREVISIÆ
Fig. 9.	In curdled Milk after 3 days.		Fig. 12.
Fig. 10.	In unboiled Urine after 2 days.		
Fig. 11	In Milk diluted with 1200 parts of Water, after 3 days.		

Scale in Ten thousandths of an Inch

ferred, in a room in the farm house, to the little glasses, each cap being replaced as soon as the glass was charged. Yet in spite of the care that was taken, organisms must have entered from the air of the orchard or of the apartment, possibly also from the cow's teat (though this had been proviously washed by drawing milk from it just before the glass was charged); for you observe every one of the twenty-four glasses shows manifest evidence of alteration, and there can be no doubt that these changes are due to the development of organisms. No fewer than seven of them are seen, by aid of a pocket lens, to contain filamentous fungi of various sorts, for aught I know undescribed, and certainly none of those commonly met with in milk.[1]

Two of the glasses containing filamentous fungi are represented of natural size in the sketches reproduced in figs. 1 and 2, Plate XX. The other glasses present appearances which members of the Society, if they will examine them, will find to be exceedingly peculiar. No two are alike: some have a golden-yellow aspect (fig. 8), some a green tint (fig. 7), while many are studded with brilliant red spots (figs. 3, 4, 5, 6) either alone or associated with other colours, and the lower parts of the contents of the several glasses are changed to various degrees of translucency and shades of tint, implying different fermentative changes. But there is no reason to suspect in any of them the occurrence of the *Bacterium lactis*, or the lactic fermentation. I have not had opportunity to examine the contents of these glasses microscopically, but in another experiment made in the same way a few days previously with twelve similar glasses I found, just as here, some affected with filamentous fungi, and the majority altered in various ways in colour, including definite specks of different shades of orange growing gradually as the red ones in this set did from a mere speck to larger and larger spots; and, examining with the microscope the contents of every one of those glasses, I found the orange specks to be composed of organisms in the form of little spherical granules peculiarly grouped, which I have elsewhere described under the name of *Granuligera*;[2]

[1] The filamentous fungi most frequently found in milk that is kept for a considerable period are the *Oidium lactis*, the common blue mould *Penicillium glaucum*, the common green mould of cheese, *Aspergillus glaucus*, and two forms of Mucor, the *M. mucedo* and *M. racemosus*.

[2] See 'Transactions of the Royal Society of Edinburgh,' loc. cit., p. 319, and Plate.

and other glasses, having alterations without such bright and definite colours, presented bacteria of different appearances, but in no case did I find the *Bacterium lactis.*

I also performed other experiments of a very simple character which illustrate equally well the rarity of the lactic ferment in the air, even though it be the air of a cow-house. The teat of the cow and the milkmaid's hands having been washed with strong watery solution of carbolic acid, milk was received directly into a purified flask of the kind above described (p. 430), and from this a dozen purified liqueur glasses were charged in my study within about half an hour. All these glasses underwent fermentations, and exhibited organisms under the microscope, but none showed the lactic fermentation or the *Bacterium lactis.*

With regard to the cause of the strange, perhaps unprecedented, appearances presented by the milk in the little glasses shown to the Society, the explanation undoubtedly is, not that organisms of a specially rare kind were here present, but that species, perhaps exceedingly frequent in other media, had an exceptional opportunity for coming forward in milk, in consequence of the exclusion of ferments such as the lactic, the butyric, &c., which, when present in milk, as they commonly are, take the precedence of others, and so alter the fluid as to render it an unsuitable pabulum for the multitude of other kinds.

Here I have another set of little test-tube glasses, twelve in number, with which the same experiment was repeated two days later, only with still more careful precautions against the entrance of organisms from the air or from the teat; but even here, although the appearances are less conspicuous than those in the other twenty-four, a careful inspection shows that, in ten out of the twelve, organisms of one kind or another have entered, but two of them remained perfectly unchanged in aspect six weeks after the performance of the experiment, and on examining the milk from one of these I found it fluid, perfectly natural in reaction and in taste, and free from any organisms that could be discovered by the microscope. Thus was at length attained the object of these experiments with the little glasses, viz., the proof that unboiled milk, as coming from a healthy cow, like urine from a healthy bladder, really contains no material capable of giving rise to any fermenta-

tive change or to the development of any kind of organism which we have the means of discovering.

The lactic ferment is as scarce in ordinary water as we have seen it to be in the air. If I prepare a series of glasses of boiled milk in the way that has been described, and add to each a drop, say half a minim, of tap water, I find that fermentative changes, such as putrefactive or butyric alterations, occur in all, but that none exhibit the souring or curdling of dairy milk. An extremely instructive experiment is to inoculate each of a series, say ten, of such glasses with a very small drop of a constant size for all, which can be readily done by means of a syringe like this (Woodcut 27), having a graduated nut (*a*), revolving on a fine screw on the piston rod (*b*), each degree on the nut corresponding to $\frac{1}{100}$ minim, so that either $\frac{1}{100}$, or $\frac{1}{50}$ or $\frac{1}{200}$, if it be desired, can be expelled at pleasure.[1] Supposing $\frac{1}{100}$ minim of water to

WOODCUT 27.

[1] It is essential to the precise working of this apparatus that there be nothing elastic in its composition, otherwise drops of varying size will be furnished by it. Thus, an india-rubber junction between the syringe and the nozzle is inadmissible. The nozzle of glass tube (*c*) is screwed upon the body of the syringe by means of the brass adapter (*d*) to which the glass tube is secured with a cement which I have found very useful on account of its power of resistance to the action of boiling water, viz. finely powdered gum copal brought to a liquid state by a high temperature and then applied to the objects to be cemented, which have previously been heated to an equally high degree. The presence of an air-bubble in the water within the syringe would also by its elasticity vitiate accuracy of performance. This is got rid of, so far as the body of the

be thus introduced into each glass, the result will probably be that fermentative changes of totally different kinds will occur in the various glasses, as indicated by striking differences of colour in the contained milk and differences of odour in the air in the glass shades; and, what is extremely interesting, some glasses will escape all change. This last fact proves at once the important truth that the fermentative agency in water, the existence of which was pointed out long ago by Dr. Burdon Sanderson, is not matter dissolved in the water, but consists of insoluble particles of some kind or other suspended in it. For if the ferment were dissolved in the water, every equal-sized drop would produce an equal effect. But the fact is, as already stated, that when drops of such minuteness are employed, some of the inoculated glasses escape altogether, and those which are affected exhibit different kinds of fermentation, and we thus learn from this simple experiment not only the truth that the fermentative material is in the form of insoluble particles, but that every minim of ordinary water contains several different kinds of ferments, which, though generally confused through being mixed up together, declare their individual peculiarities when isolated by this method of separation.

These various fermentative changes were invariably found associated with bacteria, those in different glasses sometimes showing themselves conspicuously different under the microscope, though often only distinguished by their effects. Thus, in one case, the cream being particularly thick, a bright vermilion-coloured point appeared after some days at the spot of inoculation, and gradually spread over the surface, and on examining with the microscope a portion taken with a purified needle from the vermilion spot, I found it teeming with bacteria, while a portion of the uncoloured cream in

syringe is concerned, by first accurately charging it with water that has been boiled to dispel its dissolved air. The water of inoculation, with which the glass nozzle is to be filled, is also raised to a somewhat higher temperature than the air of the apartment by placing the vessel containing it before the fire for a few minutes. The nozzle with its adapter is purified by boiling it in water in a saucepan for about half an hour, after which its fine end is immersed in the water for inoculation, and when it is filled beyond the bend, the other end is depressed, so that the rest of the filling may be done by syphon action. When a drop of water projects from the adapter, it is applied to a correspondingly projecting drop of water at the mouth of the syringe, and the two drops coalescing prevent the introduction of a particle of air when the nozzle is screwed on. With these precautious drops of exactly the same size can be insured.

the vicinity showed nothing but the usual milk globules. Here then was a remarkable change going on in the milk *pari passu* with the development of bacteria, and doubtless occasioned by them, yet the bacteria themselves were of ordinary double rod form and of about medium size.[1] But various as were the changes produced in the milk by inoculation with water, there was no instance in the course of several such experiments of the lactic fermentation resulting from it. We see, therefore, from the facts which I have adduced, that the souring of milk, instead of being—as might naturally be supposed *a priori* from seeing it occur constantly in all milk brought from a dairy—an inherent property of the liquid, is a change which, whether in boiled milk or unboiled, requires the introduction of something from without, and that something a scarce article, both in air and in water, except in dairies. Indeed, even in a dairy, though it exists in all the milk in the pans, it does not necessarily follow that it is the most frequent ferment in the air. I once took a glass of pure boiled milk to a dairy, and putting it down near one of the pans, removed its glass shade and glass cap, and left it exposed for a quarter of an hour, thinking it probable that the lactic fermentation would result. But it so happened that this was not the case. As a consequence of this exposure a filamentous fungus made its appearance in the milk, and also a bacterium, but a bacterium associated with a most extraordinary alteration, viz., viscidity in an extreme degree, reminding me of that of the glutinous drops that bead the spider's web. On introducing a needle into the top of the liquid, and raising it, I drew out a barely-visible thread, which was a yard and two inches long before it broke. Such was the special fermentation that resulted from exposure to the air on that occasion even in a dairy; it so happened that, if any particles of the lactic ferment were floating in the air at all, none fell into the glass.

This particular fermentation, therefore, from the conspicuousness of its effects and the rarity of the ferment under ordinary circumstances, seemed a peculiarly favourable one for investigation.

And now, before proceeding further, I desire to correct a mistake into which I fell when investigating this same fermentation some

[1] These experiments were performed in the early part of the year 1875, and were briefly alluded to in a paper in the 'Lancet' of that year (see 'Lancet,' April 3rd, 1875, p. 470).

years ago; for, next to the promulgation of new truth, the best thing, I conceive, that a man can do, is the recantation of published error. In the year 1873, I gave, in the 'Microscopical Journal,' an account of the behaviour, as I supposed, of the *Bacterium lactis* in different liquids.[1] I stated that, having obtained souring milk from a dairy, I inoculated a glass of uncontaminated unboiled urine with a small drop, and the result was the development in that liquid of organisms with a very different appearance from the bacteria which I had seen in the souring milk. The latter had the characters of *Bacterium lactis*, as already described (Plate, XX, fig. 9), viz., pairs or chains of small oval bodies, with lines of transverse segmentation. Those in the urine, on the other hand, were broad and extremely long, often coiled up like a spirillum, though motionless, like the *Bacterium lactis*. There were, however, what certainly looked like transitional forms between the two. From this urine I inoculated another glass of the same liquid, the result being a reproduction of the same large spirillum-like organism. I next inoculated from the second urine-glass one of Pasteur's solution; and now obtained appearances different from any before seen, viz., instead of either the motionless chains of *Bacterium lactis* of the milk, or the spirillum of the urine, an actively-moving minute double bacterium. But on introducing a small drop of the Pasteur's solution so peopled into a third urine-glass, I got back large coiled organisms resembling those of the former glasses of the same fluid, except that these exhibited languid motion. Yet the introduction of a small drop from this third urine-glass into one of pure boiled milk was followed by souring and curdling just as if the inoculation had been made with sour milk from the dairy. The apparently transitional forms in the first urine-glass made me suppose that the spirillum was the *Bacterium lactis*, modified by its new habitat. I also examined in a cultivating glass, under the microscope, a drop of a mixture of fresh urine with a small quantity of the Pasteur's solution containing the moving bacteria, and found that the minute active organisms first seen gave place to larger languidly-moving specimens, and thus I thought I had evidence of a transition from one to the other. And lastly the efficiency of the contents of the third urine-glass as a lactic ferment, in spite of the various forms assumed in the various media, confirmed my belief that I was observing one and the same organism in all the glasses. And if this

[1] See 'Quarterly Journal of Microscopical Science,' October, 1873.

was really the case, considering how thoroughly the organism must have been washed in the various media of all chemical material that might be supposed to be originally associated with it in the milk—particularly considering that the lactic fermentation does not occur at all in either urine or Pasteur's solution—the chain of facts appeared a strong confirmation of the view that this particular bacterium was really the cause of the lactic fermentation. I was mentioning these facts a few months ago to an eminent physiologist, who took the view that after all bacteria might be mere accidental concomitants of the fermentative changes; and when I had finished my story he said, "Well, I am convinced." I thought to myself, "If I have convinced this eminent teacher by these facts, they are worth proving more rigorously; I shall have a little time between giving up my surgeoncy in Edinburgh and going to London, and I will devote it to repeating the experiments; but this time I will make continuous observations under the microscope, and trace, if I can, the actual process of transformation of the organism from one form to another." Accordingly, I got some souring milk from the same dairy as before, and proceeded, in the first place, to inoculate from it a glass of uncontaminated unboiled urine, and also a glass of pure Pasteur's solution. The result in the case of the urine was that, instead of getting a large motionless spirillum as in the corresponding experiment of four years previously, I found an active double bacterium of moderate dimensions. In the Pasteur's solution, on the other hand, instead of the minute very actively-moving bacterium of my former experience, I obtained only motionless bacteria of various dimensions.

Here then were the facts all wrong. What was the explanation? I had obviously got some accidental contamination of the *Bacterium lactis* with other forms, although in doing the inoculations I had only introduced a very minute portion with the point of a heated needle. So I determined to try if possible to get rid of concomitant bacteria of other kinds, and the way which occurred to me as a possible mode of doing this was to dilute the souring milk with so large a quantity of boiled and therefore pure water as to have on the average, so far as it could be estimated, only one bacterium of any kind to every one of the drops with which a set of glasses of boiled milk should be inoculated. If this could really be done, as the *Bacterium lactis* was certainly in much larger numbers than any other kind, I might hope that some at least of the drops of inocu-

lation might contain it isolated from other species, and that thus I might have the *Bacterium lactis* develop pure and unmixed in the inoculated milk. Accordingly having obtained some souring milk from the dairy, I inoculated a glass of boiled milk from it by dipping the point of a heated needle successively in the two liquids, and when the odour of souring milk was perceptible in the air under the glass shade, I found bacteria present on microscopic examination, and endeavoured to estimate their numbers in proportion to the liquid.

This was done in the following manner. By means of the syringe already described (page 441) one or more hundredths of a minim could be measured with precise accuracy; and I found that $\frac{1}{50}$ minim exactly occupied a circular plate of thin covering glass, half an inch in diameter, so that when such a drop was placed on a glass slide, and a covering glass of the size mentioned and quite flat was put down upon it, all air was expelled from under the latter, and the rim of fluid that formed round about its margin was so narrow as not to measure a quarter of the diameter of the field of the microscope even when the highest magnifying power was used. In other words $\frac{1}{50}$ minim was disposed in a thin uniform layer of the exact size of the covering glass. Hence the number of bacteria under the glass slip, that is to say in $\frac{1}{50}$ minim, was equal to the number of the bacteria in a field of the microscope multiplied by the number of times the area of that field went into the area of the covering glass. The micrometer gave the diameter of the field in thousandths of an inch; and the covering glass measured 500 thousandths of an inch across: and the areas of the circles were of course proportioned to the squares of those diameters. All that was needful therefore, in order to enable me to calculate the number of bacteria in $\frac{1}{50}$ minim, was to form a fair estimate of the number of bacteria per field, and this was done by counting the organisms in a considerable number of fields and taking the average.[1]

[1] I found great advantage from placing the circular covering glass (with the liquid) on the under surface of a plate of thin glass, large enough to cover a chamber excavated in a thick glass plate. A drop of water sufficed to fix the edges of the thin plate of glass down upon the thick, and served also to prevent any evaporation taking place from the liquid to be examined into the air chamber, so that the liquid was maintained of constant quantity. At the same time, the object being on the under side of the thin plate of glass, an immersion lens could

It so happened that two kinds of bacteria were seen under the microscope, one motionless, with the characters of *Bacterium lactis*, the other much less numerous, with longer segments and in active movement. As a rule, on examining milk which is undergoing the lactic fermentation but is still fluid, the *Bacterium lactis* is alone discoverable; but in this instance we had ocular proof of the admixture of another sort, though in much smaller numbers. As the result of the estimate which I made of the number of bateria present in every $\frac{1}{50}$ minim, I found it necessary to dilute the milk with no less than a million parts of boiled water in order that every $\frac{1}{100}$ minim should contain on the average a single bacterium.[1] This having been done, $\frac{1}{100}$ minim of the infected water was added by means of the small syringe (figured at page 441[2]) to each of five glasses of pure boiled milk. The result of this inoculation was that one only of the five glasses was affected at all. The contents of four remained permanently fluid and unchanged, and when examined with the microscope after the lapse of thirteen days, showed no bacteria of any kind. The milk of the fifth glass, however, was, in the course of the third day after inoculation, converted into a solid mass, and on examination was found to be sharply acid, and under the microscope there were seen among the

be used for examining it to its extreme limits without the inconvenience of the liability of the drop of water under the object glass mingling with the liquid examined, as would have been the case had the object been on the upper side of the glass plate.

[1] The dilution with this enormous proportion of water was readily done by dividing the process into two stages. First, by means of the small syringe (figured at page 441) with purified nozzle, $\frac{1}{100}$ minim of the milk was added to 200 minims of boiled water, which had been measured into a purified glass by means of a pure graduated pipette connected with a syringe, the end of the pipette adapted to the syringe having been stuffed with cotton-wool before purification in the hot box, so as to filter air that passed into the pipette from the syringe. When the milk had become thoroughly diffused through the water, as indicated by uniform opalescence (the diffusion having been promoted by stirring rapidly with a pure glass rod), a minim of this first dilution was transferred by means of another and smaller pure syringe-pipette into a second purified glass, which had been charged with 50 minims of boiled water. I needly hardly add that the utmost care was used to avoid more than momentary exposure of the liquids manipulated, and of the purified pipettes or other apparatus employed.

[2] The nozzle of this syringe was purified by boiling it in water in the interval between its employment referred to in the above note and the inoculation of the milk glasses.

granular masses of casein countless motionless bacteria with the ordinary characters of *Bacterium lactis*, specimens of which were sketched and are reproduced in this diagram (Plate XX, fig. 9). No other bacteria, however, were to be discovered; we had got rid of the moving species which was seen to be associated with it in the milk before dilution, and *à fortiori* it might be believed that other species, doubtless present in the original milk, but in too small numbers to be detected, had been avoided.

Having therefore presumably obtained the *Bacterium lactis* pure and unmixed, I proceeded to ascertain its behaviour in other media. I inoculated a glass of uncontaminated unboiled urine with it; and now, instead of either the moving bacterium which resulted from a corresponding inoculation with sour milk a few days before, or the large coiled organism of the experiments done four years previously, there appeared a motionless bacterium with identically similar characters to those of the *Bacterium lactis* in the glass of milk, as will be seen from this diagram (Plate XX, fig. 10) made from a sketch taken two days after inoculation of the urine. Had either of the forms seen in the previous experiments been present, the insignificant motionless *Bacterium lactis* would probably have escaped notice altogether. In the course of the first twenty-four hours its growth was indicated by delicate white vertical streaks on the glass without any turbidity of the liquid. Next day, however, the fluid was decidedly nebulous, but after that period the growth was exceedingly slow, and very little effect was produced upon the urine as regards either odour or reaction. Nevertheless it still retained its power of acting as a lactic ferment when introduced into milk even after four days' residence in the urine; for having inoculated at this period eight glasses of boiled milk with drops of the urine diluted with enough boiled water to provide about three bacteria on the average to each drop, all the glasses soured and curdled within three days.[1]

On the day on which this fact was observed, and when the bacterium was therefore still in full activity, I introduced a small portion of the curd from one of the glasses into a glass of Pasteur's solution, in order to study the behaviour of the organism in that fluid. In this experiment I made use of what I have called a "separation-

[1] Even after seventeen days in the urine the organism still retained the power of causing lactic fermentation, though it was then not quite so energetic, requiring an additional day to produce curdling.

tube," a piece of glass tube bent at an angle of about 45° (see Woodcut 28), with one leg shorter than the other, the shorter leg closely packed with moist cotton wool (*e*), which is purified together with the tube by boiling in water. The apparatus is then transferred to a pure liqueur glass, in which it is arranged with the longer leg (*f*) placed vertically and kept in this position by a mounting of silver wire (*g*) applied to the tube before its purification. The liquid to be experimented on is now poured into the glass to a higher level

WOODCUT 28.

than the mouth of the shorter leg of the separation tube, but not so high by a considerable interval as the top of the longer leg. The liquid finds its way slowly through the cotton and rises in the longer leg, and it is into the liquid in the longer leg of the separation tube that the material of inoculation is introduced. The cotton in the shorter leg is so closely rammed that it serves as an effectual filter to prevent the passage of any particles of ordinary solid matter; but if any organism capable of developing in the liquid is introduced into the longer leg, it will work its way through the cotton, and show itself in the general liquid in the glass. Even a motionless bacterium or a filamentous fungus will traverse the closely packed mass, at a rate corresponding with the rapidity of its development. Thus we have a simple means of separating things which are living and capable of developing in any particular liquid from particles which are not alive, or which, though living, are incapable of growing in that medium. It was into the longer leg of such a separation tube in

a glass of Pasteur's solution that I introduced the morsel of curdled milk containing the actively growing *Bacterium lactis*. For a long time it appeared as if no growth whatever of the organism had taken place in its new habitat. But when nearly three weeks had elapsed, thinking that the little bit of curd looked somewhat swollen, I subjected it to microscopic examination, and found that the substance of the curd seemed to have disappeared, its place being occupied by small bacteria having the characters of *Bacterium lactis*, showing that the organism really had undergone some development. But it seemed to have grown only where it had the material of the curd to feed upon; for the outside liquid in the glass showed no trace of any organism either to the naked eye or under the microscope. Thus it appears that the *Bacterium lactis*, though not destroyed by Pasteur's solution, does not find in that fluid the materials requisite for its nutrition. I also imitated in another glass of Pasteur's solution the experiment of four years before, by inoculating it with urine in which the *Bacterium lactis* was developing actively, but here again, although the specimen was kept twenty-one days, no sign whatever of bacteric growth appeared. It was therefore plain that the *Bacterium lactis* is really incapable of growing in pure Pasteur's solution.[1]

Thus I was forced to the conclusion that the appearances which I had described in my former communication as due to modifications of the *Bacterium lactis* in urine and Pasteur's solution had been entirely deceptive, and had been occasioned by the accidental accompaniment of other species. And now that we know from the results of experiments like those with the little test-tube glasses how very numerous are the bacteria and other organisms which really infest milk, it is easy to understand how such a confusion may have arisen.[2]

[1] It is right that I should state that the solution which I employed differed from that made according to Pasteur's formula, in having only half the proportion of sugar, and in having its mineral salts derived from wood ashes instead of from the ashes of yeast. It was, however, with solution of precisely the same composition that I had worked in the experiments of four years previously.

[2] It is not, indeed, altogether easy to see what the precise train of events may have been in the experiments of four years ago. I may suggest the following as possible. First, along with the *Bacterium lactis* with which the first urine-glass was inoculated (see p. 444), was accidentally introduced another kind of bacterium, which produced the large spirillum-like appearances. This adventitious organism grew freely in the urine, along with the slowly growing and incon-

Now, however, having good reason to believe that I had got the *Bacterium lactis* pure and unmixed, I proceeded to perform the experiment which constitutes the most important feature of this investigation. I have already described the mode of procedure when speaking of the means adopted for isolating the *Bacterium lactis*. Its object now was to obtain, if possible, absolute proof, which would commend itself to the judgment of all, that the *Bacterium lactis* is really the cause of the lactic fermentation, and no mere accidental concomitant of the change.

On the 30th of August last, having provided sixteen pure glasses of boiled milk, and having estimated, in the manner already described, the number of bacteria present in every $\frac{1}{50}$ minim of a glass of boiled milk which had been inoculated the day before by touching it with a heated needle dipped in milk curdled under the influence of the pure ferment, I diluted a drop of this milk with boiled water to the requisite degree, and introduced into each of ten of the sixteen uncontaminated glasses a drop calculated to contain on the average a single bacterium, while five of the rest received each a drop supposed to contain two of the organisms, and the remaining glass was inoculated with a quantity in which, according to the estimate, there would be four bacteria. The result was that within

spicuous *Bacterium lactis*. It presented considerable varieties of form, some of them closely resembling chains of *Bacterium lactis*, but it was in reality a totally distinct species. Then when the Pasteur's solution was inoculated from the urine, both organisms were again introduced together. Here the spirillum-like organism underwent a modification, assuming the characters of an actively moving double bacterium, a transition which was, I think, sufficiently traced under the microscope (see 'Microscopical Journal,' loc. cit.). Meanwhile, the *Bacterium lactis* lay dormant in this medium, but retained its vitality, and by accident it happened that one or more of these still living individuals, lying perhaps at the surface of the liquid in the speck of scum that commonly results from inoculation, was transferred along with the other organism to the last urine-glass. Here the latter resumed the spirillum-like form which it had before shown in urine, though retaining now for a while in a limited degree the movement it had acquired in Pasteur's solution. The individual or individuals of the *Bacterium lactis* introduced into the urine along with it were here able to develope again, though slowly, and some of their progeny entered the glass of boiled milk inoculated from this urine-glass, and in that medium developed with their accustomed rapidity and with the usual fermentative effect. It may, perhaps, seem trivial to record this complicated hypothetical explanation, but I am induced to do so for the sake of illustrating the excessive care required in order to avoid deception when we are dealing with such extremely minute organisms.

three-and-a-half days the glass into which four bacteria were supposed to have been introduced contained a curdled mass, and the five which had received the drops arranged for two bacteria each, had all undergone a similar change. Of the ten inoculated with drops averaging one bacterium each, the majority were at this period still fluid; but some assumed the solid condition in the course of the next twenty-four hours, though at different times. But of this series of ten exactly five, as it so happened, remained permanently fluid.

This was just the sort of occurrence which might have been anticipated if we believed the bacteria to be really the cause of the fermentative change, and supposed that we had succeeded in forming a fair estimate of their numbers. It was to be expected that the bacteria would not be distributed with perfect uniformity in the water with which the milk was diluted; and hence of the drops containing on the average one bacterium each, some would probably be destitute of the organisms, and the rest have more than one, and in differing numbers, involving slight differences of time in arriving at the stage of the fermentative process which induced coagulation.

But not only were the results of this experiment in harmony with the view that the *Bacterium lactis* was the real fermentative agent: they would, as I believed, afford indisputable evidence of the truth of the theory, provided it should turn out, as former experience made me feel sure would be the case, that every glass which had curdled contained the bacterium, and that every one which remained fluid contained none. Though, as I have said, I did not doubt that this was the state of the case, yet I went through the laborious process of examining the contents of all the sixteen glasses just before leaving Edinburgh, nine days after the time of the inoculation. All those which had coagulated still contained an unaltered white curd with a glistening upper surface, and nothing to indicate the supervention of any change secondary to that of the lactic fermentation. The air in the glass shade of each had the odour of souring, the taste of a little portion of the curd removed for investigation was sour and its reaction sharply acid, and under the microscope, in every instance, bateria with the characters of *Bacterium lactis* were found, but no other organism. And in the case of the remaining five glasses, where the milk was still fluid and unchanged in appearance, the air in the glass shade had merely the slight odour of suet, which Pasteur long since pointed out as resulting from oxidation; the

taste was that of fresh milk, and the reaction showed the peculiar form of neutrality which fresh milk exhibits, both blue and red litmus paper acquiring an intermediate purple tint.[1] And on subjecting the contents of each to microscopic examination, I could discover under a protracted search no organisms of any kind. I have brought before the Society one of these last glasses (still under the protection of its glass cap and shade) to show that even after the lapse of nearly four months the milk remains fluid and unaltered. I need hardly say that it required considerable care to bring these glasses from Edinburgh without having their contents spilled. Nevertheless this is one which was successfully transported; and I have placed under one of the microscopes a drop of its milk, in which it will be seen that there are no organisms present, and that the only alteration discoverable is that some of the milk globules have assumed an angular form as the result of evaporation.

Here, again, is one of the glasses which underwent the lactic fermentation, and its appearance is in truth as remarkable as that of the other. We know that if curdled milk is kept under ordinary circumstances it soon loses its original characters. The *Oidium lactis* grows upon its surface, the *Penicillium glaucum* or some other common mould probably shows itself, and the curd acquires first a cheesy and then a putrid smell, accompanied with great alterations of its aspect. Here, however, the lactic fermentation having occurred single and alone, we have a pure white curd to this hour, as if the milk had curdled yesterday, and any little smell which there is in the air of the glass shade is a slight sour odour.[2]

[1] Neutral urine presents this same reaction.

[2] For the sake of any one desiring to repeat this experiment, it may be well for me to add a few matters of important detail. The estimate of the number of bacteria present in the milk should be made within about twenty-four hours of the inoculation of the glass with a purified needle-point dipped into milk souring with the pure ferment, and then applied to the milk which is to be inoculated, close to the edge of the glass, as distinguished from the central part, from which the drop will be afterwards taken. At ordinary temperatures the bacteria will then be found about the period referred to of full size and isolated, and therefore easily counted; whereas if too long a time is allowed to pass after inoculation, they will be found too numerous to be easily counted, and often of small size and in groups composed of an indefinite number. Further, if the bacteria are counted in one drop of the milk, and another drop is taken for dilution and inoculation, two great inconveniences will

And now let me dwell for a few minutes on the inference to be drawn from these facts. We have seen that boiled water rendered infective by the admixture of a small quantity of milk undergoing the lactic fermentation, having been introduced in drops of equal size into ten glasses of pure boiled milk, five of those glasses underwent the lactic fermentation, characterised by souring and curdling, while five remained altogether unaffected. This proves that the same truth holds regarding the lactic ferment which we have before established with respect to the various ferments that occur in ordinary water, viz. that it is not a material soluble in water, but consists of insoluble particles. For had it been dissolved in the water of inoculation, every equal-sized inoculating drop would have produced the same fermentative effect. Next we have to consider the bearing of our facts on the nature of those insoluble particles, the question being whether they were the bacteria or consisted of some so-called chemical ferment destitute of life, of which the bacteria were a mere accidental concomitant. Let us assume, for the sake of argument, that it is possible for insoluble particles to exist devoid of vitality, yet capable of multiplying like the bacteria. Such a notion is unsupported, I believe, by a tittle of scientific evi-

result. First, there will be no security that the two drops contained the same proportions of bacteria; and, in the second place, the knowledge that the bacteria are in process of multiplication with great speed (doubling their numbers in about an hour) leads to most undesirable hurry in the microscopic examination and the subsequent calculation, besides leaving uncertainty as to the estimate, in consequence of the development that is proceeding in the milk in the glass. But these difficulties are entirely got over by adding a minim of the milk to ten minims of boiled water in a purified glass, and using this first dilution both for the estimation of the bacteria and for furnishing the drop to be diluted for the purpose of inoculation. The milk having been well mixed with the water, the bacteria are pretty equally distributed through it, while the addition of so much water to the milk greatly retards the development of the bacteria and makes hurry unnecessary. Thus, I ascertained in one instance that the rate of increase in some milk so diluted and still kept protected in a pure glass appeared to have been only such as to treble the number of bacteria in sixteen hours, whereas they would probably have been multiplied fourfold in two hours if the milk had remained undiluted. The dilution has the further advantage that it does away entirely with the difficulty caused by the milk globules and molecules in the recognition of the bacteria in undiluted milk, even when in very thin layer. In counting the bacteria I found it convenient to take all the fields in succession both in the horizontal and in the vertical diameter of the covering glass, which with my microscope gave about a hundred fields from which to estimate the average.

dence; but, for the sake of argument, let us for a moment assume it. We should then be further obliged to suppose, in order to account for our facts, that these hypothetical particles, though merely accidental accompaniments of the bacteria, were present in precisely the same numbers, a thing which is utterly inconceivable. But we should have to go further and suppose, what is equally inconceivable, that these bodies of different natures, though mere accidental concomitants, were not only exactly equally numerous, but invariably accompanied each other in pairs; so that when a bacterium was introduced into one of the glasses, it was always associated with a particle of the hypothetical true ferment, and whenever the bacterium was excluded, the hypothetical ferment likewise failed to enter. Hence, as the only other possible interpretation of our facts involves what is utterly inconceivable, I venture to think that those facts will be admitted by all to afford a conclusive demonstration that the particular species of bacterium which we have been studying is really the cause of this special fermentation.[1]

It is true that this proof applies only to one particular kind of fermentative change. But the same method will, I believe, be found applicable in other instances, for the purpose of ascertaining how far the rule is universal that a true fermentation, by which I mean one characterised by the faculty of self-multiplication of the ferment, is caused by the development of an organism. In the meantime, as a contribution of a definite character, so far as it goes, to the elucidation of the nature of fermentative changes, so fraught with interest at the present day alike to the physician and the surgeon, I trust it will be not considered unwelcome to the Pathological Society.

[1] Strictly speaking, the expression should be, not "the cause," but "the cause under ordinary circumstances." For our facts do not of course exclude the possibility of the existence of some other ferment which might produce the same effect upon milk if the circumstances were favorable to its development, as, for example, by the exclusion of the *Bacterium lactis*. In truth, I once obtained as the result of taking milk directly from the cow into a purified vessel, a minute moving bacterium, which, though it developed very slowly in comparison with the *Bacterium lactis*, produced in time a sour curd, which I have little doubt was due to the change of milk sugar into lactic acid. But thus interpreted, the terms in the text may be considered admissible; just as we speak of the yeast plant as the cause of the alcoholic fermentation, although we know that the *Mucor racemosus*, when growing unmixed in a saccharine solution, gives rise to the same fermentative change.

There are some other points which came out in the course of this enquiry to which I should like to allude. One of these has reference to the cause of the odour of souring milk. In the lactic fermentation the sugar of milk is resolved into lactic acid by a mere rearrangement of its constituent atoms, one atom of sugar of milk going to form four atoms of lactic acid, without gain or loss. Now the chemist tells us that lactic acid is non-volatile, and accordingly this acid in the pure condition is absolutely odourless. Why, then, should souring milk have any odour? In fact this investigation has proved, as a result of isolating the true lactic ferment, that the smell of souring milk is principally due to the products of some other concomitant fermentation or fermentations. For when a glass of pure milk is made to sour under the influence of the *Bacterium lactis* pure and unmixed, the odour that results is extremely trifling. Nevertheless the air in the glass shade over a vessel containing milk in such circumstances has a slight sharp odour; and it seemed worth while to ferment a considerable quantity of milk in this way and subject it to distillation, so as to ascertain, if possible, the nature of the odorous ingredient. Having curdled boiled milk in a purified flask by means of pure *Bacterium lactis*, I mixed 6 ounces of the recently-formed clot with 5 ounces of distilled water, and having introduced it into a retort, heated it for some hours in a bath of boiling water, the distillate being collected in a receiver kept cool with cloths over which cold water constantly streamed. The product, which by that time amounted to 5½ drachms of clear watery liquid, had the sharp odour of the clot, but in a more concentrated form. It was collected in three successive portions, the last of which had comparatively little of the sharp smell, and rather an odour like that of bread. That which first came off had such a sharply-piercing smell that I felt no doubt that it was acid. To my surprise, however, I found it not only tasteless, but neutral to test-paper. I redistilled the product, and stopping the process when half had passed over, found the second distillate still more sharp in odour than the first, while the residue was almost odourless. But on distilling a third time I got a result less pungent than that of the second process, in consequence, I presume, of loss of some of the ingredient through extreme volatility. I kept the last distillate in a stoppered bottle for two days, at the end of which time it still retained its peculiar odour. What the nature of this substance is remains to be determined. It seems likely that it may be some

ætherial product with the remarkable peculiarity of having an acid smell, though tasteless and neutral in reaction.

It has been ascertained by Pasteur that the alcoholic fermentation, which, as we all know, consists in the main of the resolution of sugar into alcohol and carbonic acid without gain or loss of atoms, is attended with the appearance of other products in small quantity, such as glycerine and succinic acid, and the ætherial substance in souring milk may, perhaps, be related to the lactic fermentation in a similar manner. I cannot but think it likely that these apparently secondary products may, in reality, be of primary importance in the production of fermentative changes. Pasteur has shown that if yeast is added to a saccharine solution adapted for the nutrition of the *Torula cerevisiæ*, and the liquid is exposed in a thin layer in a shallow vessel to the atmosphere, the torula developes with peculiar rapidity, but little alcoholic fermentation results; and, on the contrary, when the liquid is placed in a deep vessel in considerable mass, the torula developes comparatively slowly but gives rise to abundant fermentation. And he explains this remarkable result by supposing that the fungus requires oxygen for its nutrition, and when it cannot obtain it otherwise, abstracts it from the sugar, and so occasions the fermentation; but when it can get the needful oxygen readily from the air, as it is able to do in the shallow vessel, it thrives peculiarly well, but, not having occasion to withdraw oxygen from the sugar, leaves it undisturbed, except the comparatively small portions of it which it assimilates for its own growth.[1]

The fact is certainly of extreme interest, because it seems to show that the breaking up of the sugar is not due to the mere presence

[1] Monsieur Pasteur expressed this view in 1861 in a "Bulletin de la Société Chimique," where, after relating the facts referred to in the text, he thus expresses himself:—"Il parait dès lors naturel d'admettre que, lorsque la levûre est ferment, agissant à l'abri de l'air, elle prend de l'oxygène au sucre et que c'est là l'origine de son caractère de ferment." In his recent work, 'Études sur la Bière,' 1876, M. Pasteur quotes these first expressions of his theory, and adds that they "n'ont rien perdu de leur rigueur; bien au contraire le temps les a consacrés" (Op. cit., p. 257). When stating his present opinion he employs, it is true, terms which might seem capable of a different interpretation, viz.:—"La fermentation par la levûre s'est présentée à nous comme la conséquence directe d'un travail de nutrition, d'assimilation, de vie en un mot, effectuée sans gaz oxygène libre. La chaleur consommée par ce travail a dû être nécessairement empruntée de la matière fermentescible, c'est à dire au corps sucré, qui, à la manière des corps explosifs, dégage de la chaleur par sa décomposition." The

of the growing organism in its vicinity; otherwise the fermentation would be proportioned to the growth of the torula, and would therefore be more abundant in the shallow vessel. But the explanation of the difference of the results, as dependent on the necessity or otherwise of abstraction of oxygen from the sugar by the torula, seems to lack applicability without some addition to the hypothesis. For sugar does not lose any oxygen at all in being converted into alcohol and carbonic acid, and therefore the withdrawal of that element would be incompatible with the new arrangement of the atoms in a saccharine molecule.

On the other hand, if we compare the formulæ of glycerine and succinic acid with that of sugar, we see that the abstraction of an atom of oxygen from each of several atoms of grape sugar might naturally lead to the simultaneous formation of the less complex atoms of the other substances out of the residual constituents of the sugar; the formation of the succinic acid involving the liberation of a certain amount of hydrogen, which again is required for the production of the glycerine: and further, that the relative proportions by weight in which the new compounds would be formed would be those in which they were actually found to present themselves by Pasteur in alcoholic fermentation.[1]

Thus the formation of the glycerine and succinic acid seems to be exactly explained by Pasteur's theory of the deoxidising agency of the torula upon sugar. But in order to account for the disruption at the same time of a very much larger number of other sugary particles

latter of these sentences might seem to have no necessary reference to the question of abstraction of oxygen from sugar by the plant; but it is immediately succeeded by the following:—"La fermentation par la levûre semble donc liée essentiellement à la propriété que possède cette petite plante cellulaire de respirer, en quelque sorte, avec l'oxygène combiné au sucre." Here the original theory is plainly restated, and we are led to infer that the decompositions of the sugar referred to in the former sentence as providing the necessary heat for the work of nutrition result from its deoxidation.

[1] According to Miller's 'Elements of Chemistry,' the formulæ of the three substances are—Glucose (*i. e.* grape sugar), $C_6H_{14}O_7$; Glycerine, $C_3H_8O_3$; Succinic acid, $C_4H_6O_4$. Therefore, 5 atoms of glucose, less 5 of oxygen, are equal to 10 atoms of glycerine, less 10 of hydrogen; and 2 atoms of glucose, less 2 of oxygen, are equal to 3 of succinic acid, plus 10 of hydrogen. Therefore, 7 atoms of glucose, less 7 of oxygen, leave the elements necessary for producing 10 atoms of glycerine and 3 of succinic acid. Now, the atomic weight of glycerine multiplied by 10 is 1860, and the atomic weight of succinic acid multiplied by 3 is 354, so that the weight of glycerine formed would be between 5 and 6 times the weight

into alcohol and carbonic acid, it would seem necessary to assume further that the decomposition of some atoms of glucose into glycerine and succinic acid, under the deoxidising agency of the torula, exercises a disturbing influence upon neighbouring particles and leads to their becoming broken up into simpler compounds without loss of atoms. Such a theory of the alcoholic fermentation of sugar would be a combination of the views of Pasteur and of Liebig; and while assigning with the former authority the primary and essential place to the growing organism, would admit with the latter a catalytic influence exerted by decomposing organic substances upon unstable compounds in their vicinity. And if this be the true state of the case, it will be seen that the glycerine and succinic acid, though produced in comparatively small quantity, so far from being secondary and unimportant, are in fact the primary effect of the action of the torula upon the sugar, of which the formation of alcohol and carbonic acid is a secondary, though simultaneous, result. And it is considerations such as these which seem to me to invest with special interest the occurrence of the odoriferous ætherial product above referred to as an accompaniment of the pure lactic fermentation.

This theory of the alcoholic fermentation has the advantage that its principle is applicable not only to cases in which the organisms concerned thrive, like the *Torula cerevisiæ*, in the presence of free oxygen, and may be therefore supposed to be ready to take that element from fermentable materials when they cannot get it in the free condition,[1] but also to fermentations like the butyric where, as M. Pasteur himself has shown, the long and actively moving bacteria which appear to constitute the ferment, instead of thriving in free oxygen, are rendered incapable of development by it, if not deprived of vitality altogether.[2] There seems no reason for sup-

of succinic acid; and this is just about the proportion of the quantities of the two materials obtained by Pasteur from fermented sugar (see 'Miller's Chemistry,' vol. iii, p. 161).

[1] Another well known instance of this is presented by the common mould, *Mucor racemosus*, which, when growing at the surface of a saccharine solution, produces little or no alcoholic fermentation, but brings about that change in very considerable amount when compelled to grow below the surface where but little free oxygen is at its disposal. M. Pasteur has also demonstrated that even *Penicillium glaucum* and *Aspergillus glaucus* have the same effect, though in a much more limited degree, when placed in similar circumstances. (*Vide* 'Études sur la Bière.')

[2] To use M. Pasteur's own words, the atmosphere acts upon them with "influence *mortelle;*" the italics are the author's ('Études sur la Bière,' p. 293).

posing that an organism upon which oxygen in the uncombined condition operates as a poison, should be specially disposed to abstract that element from its combinations. We have in fact, here, the converse of the conditions of the *Torula cerevisiæ*. But nothing is more natural than that such a bacterium, when growing at the expense of an organic material, should take for the purposes of its nutrition some of the atoms composing that substance and leave the rest to form new combinations; and the decompositions arising in this manner may operate with catalytic effect upon neighbouring particles, whether of the same body or of some other unstable compound present in the solution. For, according to this view, it by no means follows that the substance which is the main subject of a fermentation must be that on which the ferment primarily acts, or indeed, that it should contribute at all to the nutrition of the growing organism. Thus, so far as I am aware, it is, in the present state of our knowledge, an open question whether in the case of the lactic fermentation, as it occurs in milk, the *Bacterium lactis* may not derive its nourishment exclusively from the casein, the decomposition of which may act catalytically upon the milk sugar. In that case the old view of the casein being the ferment would have so much of truth in it that, though not the primary fermenting agent, it would occupy the position of an intermediary between the organism and the material which undergoes fermentation.

In the more typical fermentations, such as the alcoholic and the lactic, the most characteristic and striking phenomenon is the catalysis or breaking up of an organic substance into simpler compounds out of all proportion to what is required for the purposes of the nutrition of the fermentative organism: but it would surely be a great mistake to restrict the term fermentation to cases like these. The only safe ground for us to take is, I believe, to regard as fermentative all chemical changes brought about by growing organisms in the media which they inhabit, whether those changes be or be not more than correspond with the immediate necessities of the organism. Thus the mouldy smell produced by the growth of *Penicillium glaucum* in paste or preserve is proof of the formation of some volatile product at the expense of the material in which the fungus is growing. The chemical change thus indicated must, I conceive, be grouped with the true fermentations, whether the penicillium does or does not cause more organic particles to be decomposed than actually contribute to its nutri-

tion. And in like manner I should regard putrefaction as a fermentation without reference to the question whether the amount of albumen decomposed is or is not more than is required for the growth of the putrefactive bacteria. It is nevertheless desirable to give some distinctive appellation to fermentations such as the alcoholic and the lactic, in which the breaking up of the fermentable material occurs out of all proportion to the requirements of the organism concerned; and for such cases I would venture to suggest the designation *catalytic fermentations*. For certain it is that catalysis, or breaking up of organic substances into simpler compounds, without loss or gain of atoms, does take place in those fermentations, whether in the manner above suggested or otherwise[1]; so that the proposed term would express an ascertained truth, independently of any theory.

The lactic fermentation, then, resembles the alcoholic in being a typical catalytic fermentation, the milk sugar being broken up into lactic acid without loss or gain of atoms, while the simultaneous appearance of another product in small quantity presents another feature of similarity. A further point of apparent analogy between these two fermentations has been brought out by the investigation which forms the subject of this communication. In the experiment of inoculating ten glasses of pure boiled milk with drops calculated each to contain on the average a single *Bacterium lactis* (see page 451) five of the glasses were capped liqueur glasses such as have been above described, but the other five were in the form of test-tubes with suitable caps, employed in order that I might be able to transport them to London without spilling the milk. The milk was in about the same quantity in the two sets of vessels; but the test-tubes being narrower than the liqueur glasses, the contained milk in the former had about twice the depth and a considerably smaller free surface, affording much less opportunity for the

[1] Liebig threw out the suggestion that the yeast plant may by its growth produce a material capable of acting upon sugar in the same manner as emulsin acts upon amygdalin, one of the most beautiful examples of pure catalysis known to chemists. Pasteur alludes to this suggestion in his work above referred to ('Études sur la Bière,' p. 315) as conceding the point for which Pasteur has always contended, viz. that the organism is the primary and essential fermentative agent. And though it seems hardly called for in the case of alcoholic fermentation in presence of Pasteur's facts, yet it seems not at all improbable that the principle may be found to apply to some of the catalytic fermentations.

access of the atmosphere to the milk. The result was a very marked difference in the times of coagulation of the milk in the two sets of glasses; that in the test-tubes, where clotting took place at all, being solid within three-and-a-half days of the time of inoculation; whereas the milk remained fluid in all the liqueur glasses till about twelve hours later, and in some of those glasses which ultimately curdled the change did not occur till nearly twenty-four hours after it had taken place in the test-tubes. Or in other words, assuming that the curdling of the milk implied the formation of a certain amount of lactic acid, it appeared that the more free exposure to the air in the liqueur glasses had exercised a retarding influence upon the lactic fermentation in them. The facts, therefore, reminded me of Pasteur's observations as to the effect of atmospheric exposure in checking the alcoholic fermentation. In the time that has passed between the delivery of this communication and its publication I have made an attempt to verify the observation, and also to ascertain whether the analogy with the corresponding fact in the alcoholic fermentation was real or only apparent. For oxygen might be conceived to retard the lactic fermentation in either of two ways; either on the same principle as in the alcoholic fermentation, by supplying an element necessary for the nutrition of the organism, and so preventing the operation of its deoxidising agency, with attendant catalysis, or on the totally opposite principle of the free oxygen operating upon the *Bacterium lactis* as a poison or sedative, as it has been shown to act on the bacterium of the butyric fermentation. The inquiry has assumed larger proportions than I had anticipated: but I may briefly mention here some of the facts ascertained. I found that when I imitated Pasteur's experiment with the fermenting saccharine solution and exposed milk from a dairy in a thin layer to the atmosphere with arrangements for avoiding evaporation, the souring of the milk was retarded to a much greater degree than I had observed it in the comparatively thick layer in the liqueur glasses of the former experiment. This effect became still more marked when oxygen was substituted for atmospheric air: but the unexpected fact was also elicited that carbonic acid gas is still more potent than oxygen in retarding the lactic fermentation. The relations which these gases bear to the growth of the *Bacterium lactis* must be reserved for future consideration.

I have introduced into this diagram a representation of the *Torula cerevisiæ* side by side with the *Bacterium lactis*, drawn on the

same scale enlarged from camera lucida sketches (the sketches are reproduced on their original scale in Plate XX, figs. 9 to 12). My object in so doing is to bring out the remarkable contrast between them in point of magnitude. This is especially striking if we compare the *Torula Cerevisiæ* with the *Bacterium lactis* as it was found after growing for three days in milk diluted with 1200 parts of boiled water (fig. 11). Here they have assumed a condition so minute that the individuals of every pair do not equal in size the smaller granules of the torula. Being motionless, I could hardly have recognised them as bacteria except from their mode of grouping and the circumstances under which they occurred. Yet *Bacterium lactis* they undoubtedly were, and one such barely visible granule introduced into a gallon of uncontaminated milk would lead within three days to its conversion into a solid mass. It is a ferment just as potent as the Torula in spite of its extreme minuteness; and this circumstance, it seems to me, has an interesting bearing upon pathology. For it cannot be said to be an unlikely thing that other organisms may exist as much smaller than the *Bacterium lactis* as that bacterium is than the torula. But if this be the case, such organisms must be entirely beyond the range of human vision aided by the best microscopes that we possess. Seeing, then, that the hypothesis which I make cannot be regarded as extravagant, it will not do for us to say, because we cannot see under the microscope any organisms in a given infective liquid, that they certainly do not exist, and that therefore we must abandon the idea to which analogy might otherwise lead us, that the virus concerned may be of the nature of an organism. We see, I say, from the comparison of these two sketches that it is far from being impossible that there may exist ultra-microscopic organisms as real, as distinct in structure, and as potent in their effects, as is the *Bacterium lactis*.

But while we have thus reason to think it not unlikely that ultra-microscopic fermentative organisms may exist, we have no grounds whatever for believing that bacteria visible under the microscope have ultra-microscopic germs. The sole reason for the frequently expressed opinion, I may almost say axiomatic assumption, to that effect, is, I believe, the fact that while ordinary water has been shown to cause the development of bacteria when introduced into organic liquids even in small quantity, yet no bacteria can be discovered in it by aid of the microscope. But we are apt to

forget how extremely difficult it is, with the very high magnifying powers which it is needful to use, to discover such minute objects as bacteria unless they are present in large numbers. Now, if we recal the experiments above related of inoculating milk with very minute drops of water,[1] we see that in the sample of ordinary tap water examined there could not be more than about one particle capable of producing a bacterium in every $\frac{1}{100}$ minim. A drop of that size, small as it is, would, if placed between two flat plates of glass for microscopic examination, spread itself over a space about half a square inch in area, and we might search such a drop for an entire day without finding an individual bacterium contained in it. I once took the trouble to try whether I could find the *Bacterium lactis* in some milk diluted with boiled water to the degree requisite to produce on the average one full-sized individual to every hundredth of a minim, but failed to do so with a protracted search. But the difficulty would have been immeasurably increased if the bacterium had resided for three days in the water and had acquired the characters represented in Plate XX, fig. 11, so minute and indefinite that an individual, if placed fairly in the field of the microscope, would probably not attract attention at all, or if it did so, would be passed over as of uncertain nature. In this connection I may mention a hitherto unpublished observation which I made five years ago. I introduced some tap water into three capped liqueur-glasses, purified by heat, and placed under glass shades. After a week had elapsed, on taking the glasses into a dark room and examining the water, with a candle placed on the other side of the vessel (a very good way of detecting the first appearances of nebulosity produced in a transparent fluid by bacteric development), I could just discern upon the free surface a delicate bluish film, which, on microscopic examination, proved to be composed of closely-packed motionless bacteria of various forms, and for the most part of extreme minuteness. This explained an appearance which had before puzzled me, viz. that when water had been left undisturbed in a wine-glass for a day or two, minute bacteria had shown themselves in a drop withdrawn from it, and applied between the immersion lens and the glass that covered the object. Along with the drop I had, no doubt, taken a portion of a bacteric film on the surface. Adult bacteria, therefore, do, as a matter of fact, exist, though it may be in a very minute condition, as a scum on still

[1] See p. 442.

water, and there can, therefore, be no reasonable doubt that they exist also disseminated through moving water, but detached from one another by the motion of the liquid, so as no longer to present the recognisable characters which they have, even though extremely minute, when packed together in the form of a scum.[1] And supposing them present, thus minute, motionless, and isolated, and as widely scattered as our experiments proved them to be in the water investigated, any attempt to search for them with the microscope would be, I do not hesitate to say, absolutely hopeless.

Our morphological knowledge is also opposed to the idea that bacteria should have germs related in point of magnitude to the adult organism as the seeds of a poppy or the spores of a fern are to the full-grown plant. It is true that there are some species of bacteria in which appearances have been seen that appear to indicate the existence of spores, notably in the case of the *Bacillus anthracis*, which seems to constitute the virus of malignant pustule.[2] But in all such cases the supposed spore or germ is not

[1] The minute form in which the *Bacterium lactis* was found in milk much diluted with water is only an extreme degree of what was seen under other circumstances. It has been before mentioned (page 453) that as the souring of milk proceeds the bacteria assume a smaller size. Also when growing in urine, though they presented in the early days the same dimensions as in milk, they were found much smaller at a later period, though still proved by experiment to retain the property of inducing the lactic fermentation in milk. Again, the *Bacterium lactis* which has been described as growing slowly in Pasteur's solution at the expense of a little piece of curd, was almost as small as that in the milk diluted with water. The puny character of the progeny depends probably upon unsuitable or inadequate supply of nutritious material; and in comparison with the media in which bacteria ordinarily thrive, the elements for their nutrition are extremely scanty in water. Again, as regards moving bacteria, it is a very common thing to see them become, not only of smaller size, but motionless as they continue to develope in one and the same medium. A good example of this in a bacterium of unusual form is given in the paper in the 'Microscopical Journal' before referred to (page 17 and Plate XIX). It is, therefore, not surprising that moving bacteria should, as a rule, acquire motionless as well as minute characters in water. At the same time it is easy to understand that some particular bacteric species, like multitudes of algæ and infusoria, may have water as their favourite habitat, and attain in it their largest dimensions.

[2] See especially a memoir recently published in the 'Quarterly Microscopical Journal' (vol. xviii, new ser.), by Dr. Ewart, who has observed that the highly refracting bodies which form in the threads that constitute the organism become free and afterwards multiply by segmentation, and that the individuals which result from this fissiparous proliferation again give origin to threads. M.

only conspicuous from its highly refracting character, but attains dimensions about equal to the transverse diameter of the thread in which it grows.

Nor have we any right to assume that because some kinds of bacteria have germs, the same must necessarily be the case with all. *Apriori* there would seem to be no organisms known to us in nature with less necessity for such a provision. They constitute, in fact, in the adult form, a reproductive apparatus; perpetually multiplying with amazing rapidity by fissiparous generation. And, further, it seems very likely that bacteria, differing widely as they do in their characters, may spring from various sources. I have, on several occasions, seen appearances which make me think that some bacteria take their origin as segments of the threads of minute filamentous fungi. Certain it is that some such free segments or gemmæ, as they are termed by the fungologist, have morphological characters absolutely undistinguishable from some bacteria.[1] And, supposing any bacteria to have such an origin, we may be pretty sure they would not possess germs, seeing that gemmæ are themselves a form of germ of the fungi that produce them. In the same way there are ciliated monads which a few years ago would have been unhesitatingly regarded as definite species, but which are now well known to be the spores of various algæ and fungi; while there are others which have been proved to be adult organisms with special reproductive arrangements.[2]

The method of investigation which has been described in this communication affords the opportunity of judging regarding any kind of bacterium contained in a particular liquid, whether in reality germs are present as well as the adult form. For if we find that the number of fermentative particles corresponds exactly with the number of adult bacteria which we have counted, we may infer that there were no free germs present in the liquid. Thus we may fairly suppose that the

Pasteur describes highly refracting spots, which he believes to be of the nature of germs, in some other bacteria ('Études sur la Bière,' page 295); and I have myself seen what I have regarded as nuclei in the finely granular protoplasmic mass of some large bacteria, and I have sometimes observed the threads cleared of granular material, as if the nuclei were on the point of becoming free, appearances corresponding so far to those in the *Bacillus anthracis*.

[1] See 'Trans. of Royal Soc. of Edinb.,' loc. cit., and 'Mic. Journal,' loc. cit.

[2] See the beautiful researches of Dallinger and Drysdale on the life-history of the Monads, 'Monthly Microscopical Journal,' Aug. 1, and Dec. 1, 1873; Jan. 1, March 1, and Dec. 1, 1874; and May 1, 1875.

Bacterium lactis exists in souring milk only in the bacteric form in which we see it, although it is, of course, possible that it may form germs under other circumstances. Meanwhile the facts which I have adduced will, I hope, remove the mystery attendant on the notion that water teems with ultra-microscopic or invisible germs of the bacteria which we see of larger or smaller dimensions in organic liquids undergoing fermentative changes.

INDEX.

ABSCESS of liver, aneurysm of hepatic artery in cavity of (J. P. Irvine) . 128
„ acute, in right lumbar region, in a case of thrombosis of vena portæ (S. West) 107

ADAMS (*William*), spontaneous rupture of the œsophagus . . 113
„ *report* of Committee on ditto (W. Cayley and W. S. Greenfield) . 114

ALBUMINURIA in a case of aneurysm of abdominal aorta (J. P. Irvine) . 79

AMYLOID VISCERA in a case of old spinal disease (J. F. Goodhart) . 78

ANÆMIA, IDIOPATHIC (W. H. Dickinson) 379

ANEURYSM of aorta, destructive pneumonia from compression of bronchus by (J. P. Irvine) 36
„ — bursting into the pericardium, popliteal aneurysm cured four months previously (W. W. Wagstaffe) 72
„ of the arch of the aorta, which opened externally (T. B. Peacock) . 68
„ of abdominal aorta, rupture and formation of a traumatic aneurysm, albuminuria (J. P. Irvine) 79
„ of the anterior communicating cerebral artery (J. W. Legg) . . 106
„ of the cerebral and brachial arteries (W. S. Greenfield) . . 91
„ small, of coronary artery in an ulcer of the lower curvature of the stomach (R. D. Powell) 133
„ of hepatic artery in the cavity of an abscess of the liver; perforation of stomach and rupture of aneurysm into it (J. P. Irvine) . . 128
„ popliteal, cured four months previously to an aortic aneurysm bursting into the pericardium (W. W. Wagstaffe) 72
„ of a branch of the pulmonary artery; death from hæmorrhage (S. West). 41
„ of the right auricle (J. W. Legg) 57
„ of the left ventricle of the heart (J. W. Legg) . . . 54
„ of the cœliac axis, caused by diffuse suppuration of the retro-peritoneal tissues consequent on concretions in the kidney (J. P. Irvine) . . 85
„ bursting into the pericardium, abstract of 25 cases recorded in the 'New York Pathological Transactions' 76
„ dissecting, with obliteration of the aorta (J. W. Legg) . . 65
„ miliary, on a branch of the anterior cerebral artery in apoplexy (T. Barlow) 8
„ septal, in defective muscular development of cardiac ventricular septum (J. P. Irvine) 47
„ traumatic, formation of, in rupture of aneurysm of abdominal aorta (J. P. Irvine) 79

ANTRUM, fleshy polypus involving (W. S. Watson) . . . 223

ANUS, colloid cancer of (R. W. Lyell) 220
„ imperforate (E. Crisp) 115

AORTA, see *Aneurysm* of.
„ distortion of, from spinal curvature, with dilatation of the heart, &c. (J. F. Goodhart) 78
„ obliteration of, dissecting aneurysm, two semilunar aortic valves (J. W. Legg) 65
„ arch of, see *Aneurysm*.
AORTIC VALVE, displacement of, by a septal aneurysm (J. P. Irvine) . 47
AORTIC VALVES, rupture of (J. B. Yeo) 62
„ two semilunar (J. W. Legg) 65
APOPLEXY, miliary aneurysms on a branch of the anterior cerebral artery in a case of (T. Barlow) 8
ARTERY, anterior cerebral, case of syphilitic tumour of (W. S. Greenfield) . 10
„ — see *Aneurysms* (miliary).
„ (coronary), see *Aneurysm*.
„ (femoral), see *Thrombosis*.
„ plugging of left femoral, and iliac, gangrene of the leg, severe ulceration of the intestines (H. G. Howse) 101
„ hepatic, see *Aneurysm*.
„ superior mesenteric, see *Thrombosis* of.
„ pulmonary, obstruction of (J. P. Irvine) 11
„ — see *Aneurysm*.
AURICLES, see *Thrombosis*.
„ large aperture in the septum of (T. B. Peacock) . . . 43
„ left, loose balls of fibrin in, with mitral stenosis (J. W. Legg) . . 49
„ — large ante-mortem clot filling, in mitral stenosis (W. Ewart) . 52
„ right, aneurysm of (J. W. Legg) 57
AXILLARY GLANDS, hyperplasia of, with leukæmia (T. Ridge Jones) . 368

BACILLUS ANTHRACIS, life history of (T. C. Ewart) . . . 420
BACTERIUM LACTIS, experiments on (J. Lister) . . 437, &c.
BANCROFT (*J.*), *of Brisbane, per C. Murchison*, cases of filarious disease . 407
BARKER (*Arthur E.*), ulcerative escape of biliary calculi from the gall-bladder into the duodenum 142
„ very extensive caries of spine leading to fatal pleurisy . . 191
BARLOW (*Thomas*), miliary aneurysms on a branch of the anterior cerebral artery in a case of apoplexy 8
BLADDER, &c., DISEASES of 151-162
BOILEAU (—), *report* on the appearance of the blood in J. H. Porter's Case No. 2, lymphadenosis 340
BONES, DISEASES of 172-193
„ hyperostosis and tumour of, two cases (J. F. Goodhart) . . 175
BOWEL, see *Intestines*.
BRAIDWOOD (*P. M.*), and *F. VACHER*, *per C. Murchison*, researches on measles 421
BRAIN, contusion of, and hæmorrhage into arachnoid cavity (W. S. Greenfield) 4
„ multiple tumours of, with tuberculosis of lungs and kidneys, &c. (J. P. Irvine) 11
„ morbid appearances in, in a case of diabetes (A. Silver and J. P. Irvine) . 25
BRANCHIAL CLEFTS, congenital dermoid cysts occurring in (W. W. Wagstaffe) 194
BREAST, colloid cancer of (W. Spencer Watson) . . . 218
BROMIDE, see *Potassium* (bromide of).

BRONCHIAL GLANDS, caseous degeneration of (J. P. Irvine) . . 11
„ caseous tubercle of (J. F. Goodhart) 322
„ caseous inflammation of, at root of the right lung (J. F. Goodhart) . 323
BRONCHUS, compression of, by aneurysm of aorta; destructive pneumonia (J. P. Irvine) 36
BROWNE (*Lennox*), primary cancer of the tonsil . . . 243
„ *report* on ditto, by Committee on Morbid Growths (J. F. Goodhart and H. T. Butlin) 247
„ epithelioma of tongue invading the tonsil; living specimen . . 248
„ *report* on ditto, by the Committee on Morbid Growths (J. F. Goodhart and H. T. Butlin) 250
„ epithelioma of pharynx invading the larynx; living specimen . . 250
„ encephaloid cancer of the larynx 251
BRYANT (*Thomas*), cases of prostatic tumours removed in the operation of lithotomy; recovery 164
„ case of impacted fracture of the shaft of the femur . . . 190
BUTLIN (*Henry T.*), case of multiple round-celled sarcoma in a boy . 211
„ *report* on Lennox Browne's case of primary cancer of the tonsil . 247
„ *report* on Lennox Browne's case of epithelium of tongue invading the tonsil 250

CALCULI, spontaneous disruption of, within the bladder (W. M. Ord) . 161
„ biliary, ulcerative escape of, from the gall bladder into the duodenum (A. E. Barker) 142
„ cystine, conclusion of a case of (C. Heath) . . . 154
CALCULUS containing carbonate and phosphate of lime (W. M. Ord) . 160
„ indigo, from the kidney (W. M. Ord) 155
CANCER of the lung, and hyperostosis of lower jaw (W. Cayley) . 172
„ in its relations to the lymphatic system (G. Hoggan) . . . 384
„ see below, *Carcinoma.*
„ primary, of the tonsil (L. Browne) 243
„ colloid, of the breast (W. Spencer Watson) . . . 218
„ — of rectum, anus, and buttocks (R. W. Lyell) . . . 220
„ encephaloid, of the larynx (L. Browne) 251
„ epithelial, of the rectum, two specimens (W. H. Cripps) . . 123
CANCEROUS ULCER of forty-three years' duration (G. Thin) . . 237
CARCINOMA in a case of splenic leukæmia (T. Whipham) . . 313
„ diffused, with the distribution of Hodgkin's disease (J. F. Goodhart) . 325
„ of the orbit recurring fourteen years after its second removal (E. Nettleship) 230
CARIES of SPINE, extensive, leading to fatal pleurisy (A. E. Barker) . 191
CAYLEY (*W.*), mitral stenosis, thrombosis of left auricle and of femoral arteries, gangrene of lower extremities 60
„ hyperostosis of the lower jaw, right parietal bone, left clavicle, and tibiæ; cancer of the lung 172
„ *report* on W. Adams's case of spontaneous rupture of the œsophagus . 114
CERVICAL GLANDS, lymphadenoma in, with secondary growths in skin, spleen, &c. (W. S. Greenfield) 273, 778
CHYLE, see *Urine* (chylous).
CHYLURIA, a case of (C. H. Ralfe) 388
„ fat from a case of (W. M. Ord) 402
CIRCULATION, ORGANS of, DISEASES, &c., of . . 43-112
CIRRHOSIS of the LIVER, consequent on a case of thrombosis of the vena portæ (S. West) 107
CLAVICLE, LEFT, hyperostosis of (W. Cayley) . . . 172

CLITORIS, elephantiasis of (Dr. London) 404
CLOT, large ante-mortem, filling the left auricle (W. Ewart) . . 52
CŒLIAC AXIS, see *Aneurysm*.
COMMITTEE ON MORBID GROWTHS, REPORTS OF.
„ on L. Browne's case of primary cancer of the tonsil (J. F. Goodhart and H. T. Butlin) 247
„ — case of epithelium of tongue invading the tonsil (J. F. Goodhart and H. T. Butlin) 250
COMMUNICATIONS (SPECIAL) 269-467
A. on disease of the lymphatic system, including lymphadenoma and leukæmia 269-419
B. on splenic fever 420
C. on measles 421-25
D. on lactic fermentation . . . 425-67
CONCRETIONS in the KIDNEY, causing diffuse suppuration in retro-peritoneal tissues (J. P. Irvine) 85
„ see *Kidney*.
COUPLAND (*Sidney*), intestines and abdominal lymphatic glands from a case of lymphadenoma 363
CRIPPS (*W. H.*), two specimens of epithelial cancer of the rectum . 123
CRISP (*Edwards*), miliary tubercle of the lungs in an infant aged three months 34
„ imperforate anus 115
CROCKER (*H. Radcliffe*), bromide of potassium eruption in an infant . 252
„ and *TILBURY FOX*, the minute anatomy of dysidrosis . . 264
CRYSTALLISABLE fatty principle in chylous urine (A. Morrison) . 394
CYSTS, peritoneal, with blood cyst of left ovary (J. K. Thornton) . 145
„ in connection with the ovaries occurring in twin infants (A. Leared) . 171
„ large single, of the testicle (A. Doran) 163
„ blood, of left ovary, with peritoneal cysts (J. K. Thornton) . . 145
„ congenital dermoid, occurring in the branchial and other clefts (W. W. Wagstaffe) 194
„ — *table* of cases of dermoid cysts found in unusual position on the face (W. W. Wagstaffe) 203

DAVIES-COLLEY (*N.*), congenital occlusion of small intestine . . 115
DEGENERATION, CASEOUS, of bronchial glands (J. P. Irvine) . . 11
DELIRIUM TREMENS, pachymeningitis hæmorrhagica in (W. S. Greenfield) 1
DERMOID, see *Cysts*.
DIABETES, morbid appearances in the brain, spinal cord, &c. in a case of (A. Silver and J. P. Irvine) 25
„ phosphatic, case of so-called (C. H. Ralfe) . . . 151
DIAPHRAGMATIC HERNIA, true (G. Garlick) . . . 125
DICKINSON (*W. Howship*), ulceration of the bowel as a consequence of renal disease 117
„ two cases in which tubercle was associated with, or simulative of, lymphadenoma 373
„ idiopathic anæmia 379
„ — *observations* on ditto. (Sir William Gull) . . . 382
„ chylous urine 391

DIGESTION, ORGANS OF, DISEASES, &c. of . . 113-150
„ — A. digestive canal 113-127
„ — B. liver, pancreas, peritoneum, &c. . . . 128-150
DIPHTHERIA associated with enteric fever (W. S. Greenfield) . . 29
DISEASES, &c. of the NERVOUS SYSTEM 1-28
„ of the ORGANS of RESPIRATION . . . 29-42
„ of the ORGANS of CIRCULATION . . . 43-112
„ of the ORGANS of DIGESTION . . . 113-150
„ — A. digestive canal 113-127
„ — B. liver, peritoneum, &c. 128-150
„ of the GENITO-URINARY ORGANS . . . 151-171
„ — A. kidneys, bladder, &c. 151-162
„ — B. male genital organs 163-168
„ — C. female genital organs 168-171
„ of the OSSEOUS SYSTEM 172-193
„ MORBID GROWTHS 194-251
„ of the SKIN 252-268
„ SPECIAL COMMUNICATIONS 269-467
„ — A. on disease of the lymphatic system, including lymphadenoma and leukæmia 269-419
„ — B. on splenic fever 420
„ — C. on measles 421-425
„ — D. on lactic fermentation 425-467
DIVERTICULUM, perforation of a, in a case of acute intestinal obstruction (A. Doran) 122
DORAN (*Alban*), case of acute intestinal obstruction, perforation of a diverticulum 122
„ large single cyst of the testicle 163
DOWSE (*T. S.*), the pathology of a case of paralysis agitans, or Parkinson's disease 17
DUCTUS communis choledochus, congenital malformation of (J. H. Morgan) 137
DUODENUM, ulcerative escape of biliary calculi from the gall-bladder into (A. E. Barker) 142
DYSIDROSIS, minute anatomy of (T. Fox and H. R. Crocker) . . 264

ELEPHANTIASIS of the clitoris (Dr. London) . . . 404
„ of both hands and feet (Dr. London) 406
„ of leg, threatened (J. Bancroft) 411
EMBOLISM of the middle cerebral artery in Hodgkin's disease (H. G. Sutton) 344
ENTERIC FEVER, diphtheria associated with (W. S. Greenfield) . 29
EPITHELIOMA of the lip in a woman (G. Thin) . . . 236
„ of pharynx invading the larynx (L. Browne) . . . 250
ERUPTION, bromide of potassium, in an infant (H. R. Crocker) . . 252
EWART (*T. Cossar*), life history of bacillus anthracis [in splenic fever] . 420
EWART (*William*), large ante-mortem clot, filling the left auricle in a case of stenosis of the tricuspid and mitral valves 52
EYE, carcinoma of the orbit of, recurring fourteen years after its second removal (E. Nettleship) 230
„ melanotic sarcoma of, secondary growths in liver, &c. (J. W. Legg) . 225
„ excision of, for sarcoma of sclerotic, recurrent tumour four years after, see vol. 27, p. 227 (E. Nettleship) 234

FAT, from a case of chyluria (W. M. Ord) 402

FEET, elephantiasis of (Dr. London) 406
FEMUR, imparted fracture of the shaft of (T. Bryant) . . . 190
FERMENTATION, LACTIC, SPECIAL COMMUNICATION on (J. Lister) 425-467
FEVER, see *Splenic Fever*.
FIBRIN, loose balls of, in left auricle with mitral stenosis (J. W. Legg) . 49
FILARIOUS DISEASE, cases of (J. Bancroft 407
„ *table* of cases collected in Queensland (J. Bancroft) . . . 418
„ on examination of the blood, medical treatment and preventive measures in cases of (J. Bancroft) 416
FORAMEN OVALE closed and large aperture in septum of the auricles (T. B. Peacock) 43
FOX (*Tilbury*) and H. R. Crocker, the minute anatomy of dysidrosis . 264
FRACTURE OF LEG in a case of febrile delirium tremens (W. S. Greenfield) . 1
„ of skull, contusion of brain, and hæmorrhage into arachnoid cavity (W. S. Greenfield) 4
„ impacted, of the shaft of the femur (T. Bryant) . . . 190

GALL BLADDER, ulcerative escape of biliary calculi from, into the duodenum (A. E. Barker) 142
GANGRENE of lower extremities, in a case of mitral stenosis (W. Cayley) . 60
„ of the leg in a case of thrombosis of superior mesenteric artery, &c. (H. G. Howse) 101
GARLICK (*George*), true diaphragmatic hernia . . . 125
„ case of rapidly fatal lymphadenoma 358
GENERATION, ORGANS of, DISEASES, &c., of . . 163-171
GLANDS, see *Hodgkin's* disease of.
„ see *Axillary*, *Bronchial*, *Cervical*.
GODLEE (*R. J.*), on the introduction of the penicillium glaucum into tube glasses by acari 427
GOODHART (*James F.*), old spinal disease, with amyloid viscera, distortion of the aorta from spinal curvature, with dilatation of the heart, and ante-mortem coagula in the left ventricle 78
„ two cases of hyperostosis and tumour of the bones . . . 175
„ cases illustrating diseases of the lymphatic system, and particularly lymphadenoma or leukæmia lymphatica and leukæmia splenica . . 322
„ *report* on Lennox Browne's case of primary cancer of the tonsil . 247
„ *report* on Lennox Browne's case of epithelium of tongue invading the tonsil 250
GOWERS (*W. R.*), observations on specimens illustrating lymphatic diseases . 304
GREENFIELD (*W. S.*), pachymeningitis hæmorrhagica in delirium tremens . 1
„ on a case of syphilitic tumour of anterior cerebral artery . . 10
„ diphtheria, associated with enteric fever 29
„ cases of aneurysm of the cerebral and brachial arteries . . 91
„ specimens illustrative of the pathology of lymphadenoma and leucocythæmia 272
„ *report* on W. Adams's case of spontaneous rupture of œsophagus . 114
GROWTHS, MORBID 194-251
GULL (*Sir William*) *observations* on W. H. Dickinson's case of idiopathic anæmia 382

HÆMORRHAGE into arachnoid cavity in a case of fracture of skull (W. S. Greenfield) 4
„ death from, in a case of aneurysm of a branch of the pulmonary artery (S. West) 41

HÆMORRHAGIC pachymeningitis in delirium tremens (W. S. Greenfield) . 1
HANDS, elephantiasis of (Dr. London) 406
HEART, aneurysm of, see *Aneurysm.*
„ dilatation of, and ante-mortem coagula in the left ventricle (J. F. Goodhart) 78
„ malformation of, aperture in septum of the auricles, foramen ovale closed (T. B. Peacock) 43
HEATH (*Christopher*), conclusion of a case of cystine calculi . . 154
HERNIA, true diaphragmatic (G. Garlick) 125
HODGKIN'S disease of the glands, two cases of: leucocythæmia, lymphadenosis (J. H. Porter) 335
„ — diffused carcinoma with the distribution of (J. F. Goodhart). . 325
„ — drawings of organs with microscopical sections from cases of (H. G. Sutton and F. C. Turner) 342
„ — case 1, anæmia lymphatica, enlargement of glands, &c. . . 343
„ — case 2, fatty degeneration of the heart, thrombosis of iliac veins, &c. 344
„ — case 3, lymphadenoma, enlargement of lymphatic glands, and of spleen, &c. 345
„ — case 4, masses of growth in spleen, liver, kidneys, lungs, &c. . 346
„ — case 5, general enlargement of lymphatic glands and spleen . 346
„ — case 6, enlargement of spleen, with disseminated nodules . 347
„ — case 7, general glandular and splenic enlargement, &c. . . 349
„ — case 8, great enlargement of the spleen and lymphatic glands, &c. . 351
„ — case 9, great enlargement of the spleen, liver, kidneys, &c. . 353
„ — see *Lymphadenoma*, &c.
HOGGAN (*George*), cancer in its relations to the lymphatic system . 384
HOWSE (*H. G.*), thrombosis of the superior mesenteric artery, with plugging of the left femoral, external and common iliac arteries, gangrene of leg, and severe ulceration of the intestines 101
„ hyperostosis of the tibia, with curvature of the shaft, osteitis deformans, and development of a spindle-celled sarcoma in the upper epiphysis . 182
„ general hyperostosis, with osteo-arthritis in a living subject . . 184
HYPEROSTOSIS, general, with osteo-arthritis in a living subject (H. G. Howse) 184
„ and tumour of the bones, two cases (J. F. Goodhart) . . . 175
„ of the lower jaw, right parietal bone, left clavicle and tibiæ, cancer of lung (W. Cayley) 172
„ of the tibia (T. W. Nunn) 181
„ — with curvature of the shaft, osteitis deformans, &c. (H. G. Howse) . 182
HYPERPLASIA of axillary glands, with leukæmia (T. Ridge Jones) . 368

INDIGO, see *Calculus* (Indigo).
INTESTINES, DISEASES of 113-127
„ acute obstruction of; perforation of a diverticulum (A. Doran) . 122
„ severe ulceration of, in a case of thrombosis (H. G. Howse) . . 101
„ ulceration of, as a consequence of renal disease (W. H. Dickinson) . 117
„ small, congenital occlusion of (N. Davies-Colley) . . . 115
IRVINE (*J. Pearson*), multiple tumours of the brain, tuberculosis of lungs and kidneys, caseous degeneration of bronchial glands; obstruction of the pulmonary artery 11
„ destructive pneumonia due to compression of bronchus by aneurysm of aorta 36
„ defective muscular development of the cardiac ventricular septum, consequent septal aneurysm, displacement of an aortic valve by this aneurysm . 47

IRVINE (*J. Pearson*), aneurysm of abdominal aorta, rupture and formation of a traumatic aneurysm, albuminuria 79
„ aneurysm of the cœliac axis, caused by diffuse suppuration in the retro-peritoneal tissues, consequent on concretions in the kidney; pyæmic changes . 85
„ aneurysm of hepatic artery in the cavity of an abscess of the liver, perforation of the stomach and rupture of aneurysm into it . . . 128
„ see *Silver* and Irvine, case of diabetes.

JAW, lower, hyperostosis of, with cancer of lung (W. Cayley) . . 172

JONES (*T. Ridge*), hyperplasia of axillary glands with leukæmia . . 368

KIDNEYS, BLADDER, &c., DISEASES of . . . 151-162
„ disease of, followed by ulceration of the bowel (W. H. Dickinson) . 117
„ concretions in the, causing diffuse suppuration in retro-peritoneal tissues, followed by aneurysm of cœliac axis (J. P. Irvine) . . . 85
„ see *Calculus; Tuberculosis.*

LACTIC FERMENTATION, SPECIAL COMMUNICATION on (J. Lister) . 425-467
LACTIC FERMENTATION, and its bearings on pathology (J. Lister) 425-467
LARYNX, encephaloid cancer of (L. Browne) . . . 251
„ epithelioma of pharynx, invading the (L. Browne) . . . 250

LEARED (*Arthur*), cysts in connection with the ovaries occurring in twin infants 171

LEGG (*J. Wickham*), two cases of loose balls of fibrin in the left auricle, with mitral stenosis 49
„ aneurysm of the left ventricle of the heart . . . 54
„ aneurysm of the right auricle 57
„ obliteration of the aorta, dissecting aneurysm, two semilunar aortic valves 65
„ aneurysm of the anterior communicating cerebral artery . . 106
„ melanotic sarcoma of the eyeball; secondary growths in the organs of the chest and belly, particularly in the liver 225
LEUCOCYTHÆMIA, case of (J. H. Porter) 335
„ specimens illustrative of the pathology of (W. S. Greenfield) . . 272
„ with multiple hæmorrhages and infiltration of liver and kidneys (W. S. Greenfield) 298
LEUKÆMIA (S. Wilks) 269
„ lymphatic, cases illustrating (J. F. Goodhart) . . . 322
„ — hyperplasia of axillary glands (T. Ridge Jones) . . . 368
„ splenic, cases illustrating (J. F. Goodhart) . . . 322
„ — with carcinoma (T. Whipham) 313
„ see *Lymphadenoma.*

LIME, carbonate of, see *Calculus.*
„ phosphate of, see *Calculus.*
LIP, epithelioma of, in a woman (G. Thin) 236

LISTER (*Joseph*), on the lactic fermentation and its bearings on pathology 425-467

LITHOTOMY, prostatic tumours removed in the operation; recovery (T. Bryant) 164

LIVER, &c., DISEASES of 128-150
„ affection of, in lymphadenoma (W. S. Greenfield) . . . 278
„ abscess of, aneurysm of hepatic artery in the cavity of (J. P. Irvine) . 128
„ cirrhosis of, consequent on a case of thrombosis of the vena portæ (S. West) 107
„ secondary growths in, following melanotic sarcoma of the eyeball (J. W. Legg) 225
„ softening of syphiloma of (S. Wilks) 135

LONDON, Dr., of Carlsbad, per C. Murchison, elephantiasis of the clitoris 404

LUNG, cancer of, and hyperostosis of the lower jaw (W. Cayley) . . 172
„ morbid appearances in, in a case of diabetes (A. Silver and J. P. Irvine) . 25
„ pyæmic changes in (J. P. Irvine) 85
„ siliceous matter found in, in millstone-makers' disease (T. B. Peacock) . 31
„ see *Tubercle; Tuberculosis.*

LUPUS, hypertrophic, case of, with the histology of its various stages (A. Sangster) 254

LYELL (*R. W.*), colloid cancer of rectum, anus, and buttocks . . 220

LYMPHADENOMA (C. Macnamara) 360
„ experiments illustrative of the pathology of (W. S. Greenfield) . . 272
„ cases illustrating (J. F. Goodhart) 322
„ varieties of, and necessity for limiting the term to the nature of the growth 296
„ with affection of the cervical and mediastinal glands and typical affection of the spleen, case 1 (W. S. Greenfield) 273
„ case 2 commencing in the cervical glands, with secondary growths in the skin, affection of liver and spleen, case 2 (W. S. Greenfield) . . 278
„ — case 3 (W. S. Greenfield) 282
„ — case 4, commencing in inguinal glands (W. S. Greenfield) . . 284
„ — case 5, of cervical glands, infiltration of omentum and peritoneum (W. S. Greenfield) 288
„ rapidly fatal case of (Geo. Garlick) 358
„ intestines and abdominal lymphatic glands from a case of (S. Coupland) . 363
„ sections of spleen in 306
„ two cases of tubercle associated with (W. H. Dickinson) . . 373
„ and Leukæmia (S. Wilks) 269

LYMPHADENOSIS, case of (J. H. Porter) 335

LYMPHATIC GLANDS, progressive caseous disease of, after disease of the knee-joint (J. F. Goodhart) 324

LYMPHATIC SYSTEM, disease of, including lymphadenoma and leukæmia, SPECIAL COMMUNICATIONS ON 269-419
„ cases illustrating diseases of (J. F. Goodhart) . . . 322
„ observations on specimens illustrating diseases of (W. R. Gowers) . 304
„ cancer in its relations to (G. Hoggan) 384

MACNAMARA (C.), lymphadenoma 360

MALFORMATION, congenital, of the ductus communis choledochus (J. H. Morgan) 137

MALIGNANT DISEASE, see *Cancer.*

MAMMARY REGION, see *Breast.*

MARSHALL (*Lewis W.*), *per W. J. Walsham*, spindle-celled sarcoma in the muscles of the calf, from a child aged five months 215

MEASLES, SPECIAL COMMUNICATIONS ON 421-5
„ researches on (P. M. Braidwood and F. Vacher) . . . 421

MENINGITIS, tubercular, case of (J. F. Goodhart) . . . 322

MILIARY tubercle, see *Tubercle.*

MILK, see *Lactic* Fermentation.

MILLSTONE-MAKERS' disease; siliceous matter found in the lung (T. B. Peacock) 31

MITRAL VALVE, stenosis of (W. Ewart) 52
„ — stenosis of, in cases of loose balls of fibrin in left auricle (J. W. Legg) . 49
„ — thrombosis of left auricle, &c. (W. Cayley) . . . 60

MORBID GROWTHS 194-251

MORBILLI, see *Measles.*

MORGAN (*John H.*), case of congenital malformation of the ductus communis choledochus 137
MORISON (*Alex.*), case of chylous urine, in which the fatty principles were in part crystallisable, and the presence of sugar determined . . 394
MURCHISON (*C.*), see *London*, *Bancroft*, *Braidwood*, and Vacher.
MUSCLES OF THE CALF, spindle-celled sarcoma in (L. W. Marshall) . 215

NEPHRITIS, secondary acute, and acute abscess in right lumbar region in a case of thrombosis of vena portæ (S. West) 107
NERVOUS SYSTEM, DISEASES, &c., of 1-28
NETTLESHIP (*E.*), carcinoma of the orbit recurring fourteen years after its second removal 230
„ sequel to a case of sarcoma of the sclerotic: death from recurrent tumours four years after excision of the eye. (See vol. 27, p. 227) . . 234
NOSTRIL, fleshy polypus involving (W. S. Watson) . . . 223
NUNN (*T. W.*), hyperostosis of the tibia 181

OBSTRUCTION, see *Intestines*.
OCCLUSION, congenital, of small intestine (N. Davies-Colley) . . 115
ŒSOPHAGUS, spontaneous rupture of (W. Adams) . . . 113
ORBIT, fleshy polypus involving (W. S. Watson) . . . 223
„ see *Eye*.
ORD (*William M.*), indigo calculus from the kidney . . . 155
„ calculus containing carbonate and phosphate of lime . . . 160
„ spontaneous disruption of calculi within the bladder . . . 161
„ fat from a case of chyluria 402
OSSEOUS SYSTEM, DISEASES, &c., of . . . 172-193
OSTEITIS DEFORMANS, hyperostosis of tibia (H. G. Howse) . . 182
OSTEO-ARTHRITIS, with general hyperostosis in a lung subject (H. G. Howse) 184
OVARIES, cysts in connection with, occurring in twin infants (A. Leared) . 171
OVARY, left, blood cyst of, with peritoneal cysts (J. K. Thornton) . . 145
„ — solid tumours of, and slightly enlarged right (H. Taylor) . . 168

PACHYMENINGITIS hæmorrhagica in delirium tremens (W. S. Greenfield . 1
PARALYSIS AGITANS OR PARKINSON'S DISEASE, pathology of a case of (T. S. Dowse) 17
PARKINSON'S DISEASE, see *Paralysis Agitans*.
PASTEUR (*L.*), notices of his solution for experiments, &c., on fermentation (J. Lister) . . . . . 431, &c.
PEACOCK (*T. B.*), millstone-makers' disease; siliceous matter found in the lung 31
„ malformation of the heart; large aperture in the septum of the auricles, foramen ovale closed 43
„ aneurysm of the arch of the aorta which opened externally . . 68
PENICILLIUM GLAUCUM, its introduction into tube glasses by acari . 427
PERFORATION OF A DIVERTICULUM, in a case of acute intestinal obstruction (A. Doran) 122
PERICARDIUM, aortic aneurysm bursting into (W. W. Wagstaffe) . 72
PERITONEUM, &c., DISEASES, &c., of . . . 128-150
„ see *Cysts* (Peritoneal).

PERITONEAL (RETRO-) TISSUES, diffuse suppuration in, causing aneurysm of the cœliac axis (J. P. Irvine) 85
PHARYNX, epithelioma of, invading the larynx (L. Browne) . . 250
PLEURISY, fatal, extensive caries of spine leading to (A. E. Barker) . 191
PNEUMONIA, destructive, due to compression of bronchus by aneurysm of aorta (J. P. Irvine) 36
POLYPUS, fleshy, involving the antrum, orbit, and nostril (W. Sp. Watson) . 223
POTASSIUM, bromide of, eruption in an infant (H. R. Crocker) . . 252
POWELL (*R. Douglas*), small aneurysm of the coronary artery in an ulcer of the lower curvature of the stomach 133
PROSTATE, tumours of, removed in the operation of lithotomy; recovery (T. Bryant) 164

RALFE (*Charles H.*), case of so-called phosphatic diabetes . . 151
„ a case of chyluria 388
RECTUM, colloid cancer of (R. W. Lyell) 220
„ epithelial cancer of, two specimens (W. H. Cripps) . . . 123
RENAL DISEASE, see *Kidneys*.
RESPIRATION, ORGANS of, DISEASES, &c., of . . 29-42
ROWLANDS (*Thos.*), letter relative to filariæ found in urine . . 407
RUPTURE of aortic valves (J. B. Yeo) 62
„ spontaneous, of œsophagus (W. Adams) 113

SANGSTER (*A.*), case of "hypertrophic lupus," with the histology of its various stages 254
„ — *summary* of microscopical appearances . . . 264
SARCOMA of the anterior part of the sclerotic, death from recurrent tumours nearly four years after excision of the eye (see vol. xxvii, p. 227 (E. Nettleship) 234
„ round-celled, involving the antrum, orbit, and nostril (W. Sp. Watson) . 223
„ — multiple, in a boy (H. T. Butlin) 211
„ spindle-celled, in the upper epiphysis (H. G. Howse) . . 182
„ — in the muscles of the calf, from a child aged five months (L. W. Marshall) 215
„ melanotic, of the eyeball, secondary growths in the chest, liver, &c. (J. W. Legg) 225
SCALP, rodent ulcer of, pathological histology of (G. Thin) . . 241
SCLEROTIC, see *Sarcoma* of.
SEPTUM of the auricles, large aperture in: foramen ovale closed (T. B. Peacock) 43
„ cardiac ventricular, defective muscular development: septal aneurysm, &c. (J. P. Irvine) 47
SILICEOUS matter found in lung, in millstone-maker's disease (T. B. Peacock) 31
SILVER (*Alex.*) and *J. Pearson IRVINE*. case of diabetes; morbid appearances met with in the brain, spinal cord, lungs, &c. . . . 25
SKIN, DISEASES of 252-268
„ secondary growths in, in lymphadenoma (W. S. Greenfield) . . 278
„ bromide of potassium eruption of, in an infant (H. R. Crocker) . 252
SKULL, see *Cranium*.
SOFTENING of syphiloma of liver (S. Wilks) . . . 135
SPINE, extensive caries of, leading to fatal pleurisy (A. E. Barker) . 191

SPINAL curvature, distortion of the aorta from (J. F. Goodhart) . . 78
„ disease, old, with amyloid viscera, &c. (J. F. Goodhart) . . 78
SPINAL CORD, morbid appearances in, in a case of diabetes (A. Silver and J. P. Irvine) 25
„ elongated cavity in (Fred. Taylor) 21
SPLEEN, typical affection of, in lymphadenoma (W. S. Greenfield) 273-278
„ sections of, in lymphadenoma 306
SPLENIC FEVER, SPECIAL COMMUNICATIONS . . . 420
STEEL (*G. R.*), autopsy of L. Browne's case of cancer of tonsil . . 245
STENOSIS, mitral, thrombosis of left auricle and of femoral arteries, &c. (W. Cayley) 60
STOMACH, INTESTINES, &c., DISEASES of . . . 113-127
„ perforation of, and rupture of aneurysm of hepatic artery into it (J. P. Irvine) 128
„ ulcer of lower curvature of, aneurysm of coronary artery in (R. D. Powell) 133
SUGAR, presence of, in chylous urine (A. Morison) . . 394, 398
SUPPURATION, diffuse, in retro peritoneal tissues, causing aneurysm of the cæliac axis (J. P. Irvine) 85
SUTTON (*H. G.*), *per F. C. Turner*, drawings of organs, with microscopical sections, from cases of Hodgkin's disease and allied conditions . 342
SYPHILITIC TUMOUR of anterior cerebral artery (W. S. Greenfield) . 10
SYPHILOMA of liver, softening of (S. Wilks) . . . 135
SYRINGOMYELUS, elongated cavity in the spinal cord (Fred. Taylor) . 21
TAYLOR (*Frederick*), elongated cavity in the spinal cord (syringomyelus) . 21
TAYLOR (*Henry*), *per J. Knowsley Thornton*, solid tumour of left ovary and slightly enlarged right ovary 168
TESTICLE, large single cyst of (A. Doran) 163
THIN (*George*), case of epithelioma of the lip in a woman . . 236
„ cancerous ulcer of forty-three years' duration . . . 237
„ pathological histology of a case of rodent ulcer of the scalp . . 241
THORNTON (*J. Knowsley*), peritoneal cysts with blood cyst of left ovary . 145
„ see *Taylor* (*H.*).
THROMBOSIS of left auricle and of femoral arteries in case of mitral stenosis (W. Cayley) 60
„ of the iliac veins in Hodgkin's disease (H. G. Sutton) . . 344
„ of superior mesenteric artery, with plugging of left femoral, and iliac arteries, gangrene of leg (H. G. Howse) 101
„ of the vena portæ, leading to cirrhosis of the liver, after thrombosis of vena cava, &c. (S. West) 107
THYROID GLAND, specimen of cystic tumour of, successfully removed from the living subject (J. Wood) 206
TIBIÆ, hyperostosis of (W. Cayley) 172
„ — (T. W. Nunn) 181
„ — with curvature of the shaft, osteitis deformans (H. G. Howse) . 182
TONSILS, primary cancer of (L. Browne) 243
TRICUSPID VALVE, stenosis of (W. Ewart). . . . 52
TUBERCLE, two cases of, associated with lymphadenoma (W. H. Dickinson) 373
„ caseous, of bronchial glands invading the lung, case of (J. F. Goodhart) . 322
„ miliary, of the lungs in an infant aged three months (E. Crisp) . . 34
TUBERCULOSIS, GENERAL, case of (J. F. Goodhart) . . . 322
„ of the lungs and kidneys, in a case of multiple tumours of the brain (J. P. Irvine) 11

TUMOUR and hyperostosis of bones, two cases (J. F. Goodhart) . . 175
„ cystic, of the thyroid gland successfully removed from the living subject (J. Wood) 206
„ multiple, of the brain, with tuberculosis of lungs and kidneys, &c. (J. P. Irvine) 11
„ prostatic, removed in the operation of lithotomy; recovery (T. Bryant) . 164
„ recurrent, nearly four years after excision of the eye for sarcoma of sclerotic (see vol. xxvii, p. 227) (E. Nettleship) 234
„ solid, of left ovary, and slightly enlarged right ovary (H. Taylor) . 168
TURNER (*F. C.*), see *Sutton* (drawings of cases of Hodgkin's disease).
ULCER of lower curvature of stomach, aneurysm of the coronary artery in (R. D. Powell) 133
„ cancerous, of forty-three years' duration (G. Thin) . . . 237
„ rodent, of the scalp, pathological histology of (G. Thin) . . 241
ULCERATION, severe, of intestines in a case of thrombosis of the superior mesenteric artery (H. G. Howse) 101
„ of the bowel as a consequence of renal disease (W. H. Dickinson) . 117
URINARY ORGANS, DISEASES, &c., of . . . 151—162
URINE, chylous (W. H. Dickinson) 391
„ — case in which the fatty principles were in part crystallisable and the presence of sugar determined (A. Morison) 394
VACHER (*F.*), see *Braidwood* and Vacher.
VALVE, see *Aortic, Mitral, Tricuspid.*
VASCULAR SYSTEM, DISEASES, &c. of . . . 43-112
VENA PORTÆ, see *Thrombosis* of.
VENTRICLE, left, ante-mortem coagula in, in a case of dilatation of the heart (J. F. Goodhart) 78
„ — of the heart, aneurysm of (J. W. Legg) . . . 54
VISCERA, amyloid, in a case of old spinal disease (J. F. Goodhart) . 78

WAGSTAFFE (*W. W.*), aneurysm of the aorta bursting into the pericardium, popliteal aneurysm cured four months previously (with abstract of cases in the New York Pathological Transactions) 72-6
„ congenital dermoid cysts occurring in the branchial and other clefts . 194
„ — table of cases of dermoid cyst found in unusual position on the face . 203
WALSHAM (*W. J.*), see *Marshall* (*L. W.*)
WATSON (*W. Spencer*), specimen of colloid cancer of the breast . 218
„ case of fleshy polypus (round-celled sarcoma) involving the antrum, orbit, and nostril 223
WEST (*Samuel*), case of aneurysm of a branch of the pulmonary artery; death from hæmorrhage 41
„ case of thrombosis of the vena portæ, leading to cirrhosis of the liver after thrombosis of the vena cava, &c. 107
WHIPHAM (*T.*), splenic leukæmia with carcinoma . . . 313
WILKS (*Samuel*), softening of syphiloma of liver . . . 135
„ lymphadenoma and leukæmia 269
WOOD (*John*), specimen of cystic tumour of the thyroid gland successfully removed from the living subject 206

YEO (*J. Burney*), case of rupture of the aortic valves . . . 62

PRINTED BY J. E. ADLARD, BARTHOLOMEW CLOSE, LONDON

2

41 B107

J. HOLZER